



# REVISTA DE GASTROENTEROLOGÍA DE MÉXICO

[www.elsevier.es/rgmx](http://www.elsevier.es/rgmx)



## SCIENTIFIC LETTERS

### Perforated gastric volvulus due to incarcerated paraesophageal hernia<sup>☆</sup>



### Vólvulo gástrico perforado por hernia paraesofágica incarcerada

A 77-year-old woman came to the emergency department presenting with abdominal pain of 48-h progression that initially was epigastric and then became generalized. Her other symptoms were pain in the center of the chest with dyspnea, nausea with no vomiting, and a progressively deteriorating general health status; as the hours progressed, her level of consciousness began to diminish. She had an important history of iron deficiency anemia that was treated with oral iron.

Upon arrival she presented with hypotension (blood pressure 76/60 mmHg), tachycardia (121 bpm), tachypnea (27 rpm), and desaturation (SaO<sub>2</sub>: 89%). The first examination revealed a distended and tympanic abdomen with diffuse pain upon palpation and obvious signs of generalized peritoneal irritation. Nasogastric tube placement was unsuccessful. Blood analysis showed elevated levels of C-reactive protein and procalcitonin - 110 mg/l and 282 ng/ml, respectively -, leukopenia (1,200 l/ml), acute renal failure (urea of 69 mg/dl and creatinine of 1.68 mg/dl), and hypoxemia with compensated metabolic acidosis. Electrocardiogram results showed no signs of acute myocardial ischemia.

A plain chest x-ray taken with a portable machine showed a large hiatal hernia with probable stomach protrusion and an image of paragastric gas (suggesting pneumoperitoneum) (fig. 1A). Crystalloid and colloid resuscitation was begun due to the symptoms of shock, and once the hemodynamic parameters improved, an abdominal computed tomography scan was carried out (figs 1B and C); it revealed paraesophageal gastric herniation with organoaxial volvulus (intrathoracic disposition of the fundus and body with the gastroduodenal junction in the normal position); it also showed signs of ischemia in the gastric wall and perigastric ectopic gas bubbles.

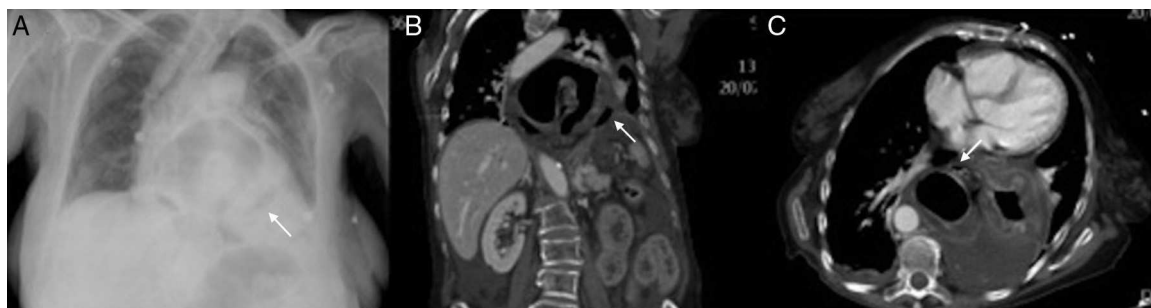
Emergency surgery was indicated and the patient underwent laparotomy through a midline incision that revealed diffuse peritonitis with abundant free fluid and a paraesophageal hernia with organoaxial gastric volvulus that presented with signs of ischemia in the entire greater curvature, as well as a 3 cm perforation in the fundic portion of the curvature. Given the patient's situation (48-h symptom progression, the need for vasoactive drug perfusion from the start of the procedure, and the fact that the lesser curvature was apparently not involved), the entire cavity was thoroughly washed, the hernia was reduced, and atypical tubular gastrectomy was performed, extirpating practically the complete greater curvature. Gastropexy from the remnant to the diaphragm and its left pillar was then carried out (fig. 2).

The patient was placed in the intensive care unit. She showed slight improvement and then within the first 24 hours presented with hemodynamic deterioration that was refractory to catecholamines. Her previous respiratory and renal failure worsened, progressing to multiorgan failure and consequent death.

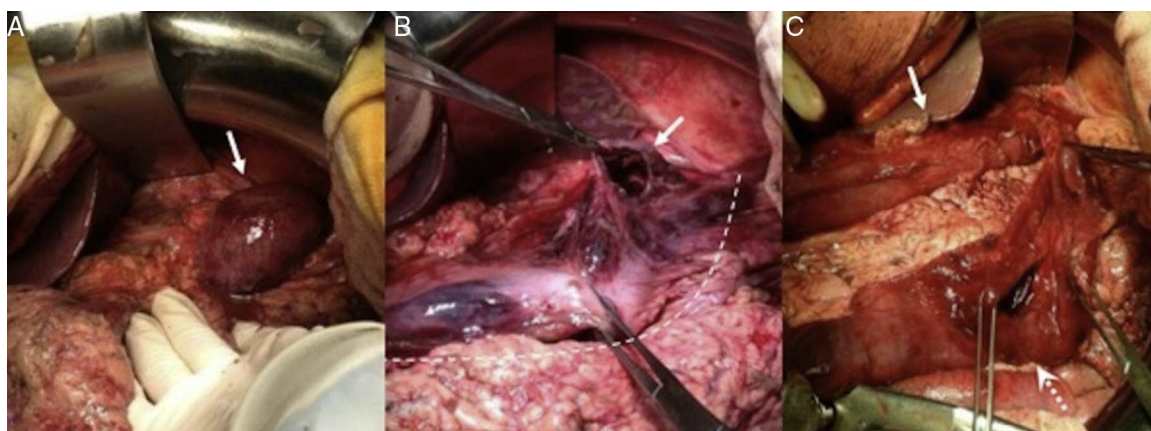
Paraesophageal hernias (PEH) are produced by a herniation of the gastric fundus through the diaphragm with the gastroesophageal junction (GEJ) in the normal position. They make up 5%<sup>1</sup> of the hiatal hernias and are considered to be caused by a weakness in the pleuroperitoneal membrane that allows the anterior wall of the stomach to protrude between the esophagus and the phrenoesophageal ligament.<sup>2</sup> Because of the position of the GEJ, these patients do not usually present with the typical symptomatology of gastroesophageal reflux disease, but rather seek medical attention due to dysphagia (resulting from esophageal compression by the herniated stomach), chronic anemia from mucosal bleeding, postprandial fullness, nausea, and vomiting.<sup>3</sup> However, some patients remain asymptomatic or begin to present with the appearance of complications.

Acute PEH can be produced by gastric volvulus, incarceration, strangulation, massive bleeding, or perforation.<sup>4</sup> Gastric volvulus is an infrequent entity, arising from a 180° rotation of the stomach over its own axis.<sup>5</sup> Despite being described as a primary presentation, the majority of cases are secondary to other pre-existing pathologies (paraesophageal hernias, traumatism, etc.) In regard to the rotational axis, there are 2 types of volvulus: the organoaxial (60%), in which the stomach rotates over its longer axis, with the greater curvature in a cephalad direction and the lesser curvature in a caudal one; and the mesenteroaxial (30%), in

<sup>☆</sup> Please cite this article as: Martínez-Pérez A, Garrigós-Ortega G, Gómez-Abril S, Torres-Sánchez T, Uceda-Navarro D. Vólvulo gástrico perforado por hernia paraesofágica incarcerada. Revista de Gastroenterología de México. 2014;79:204–206.



**Figure 1** Chest x-ray. A): Large hiatal hernia with a probably ectopic paragastric air bubble (black arrow). Left pleural effusion. CT: coronal (B) and axial (C) views: paraesophageal gastric herniation with organoaxial volvulus. Intrathoracic disposition of the fundus and body with normal location of the gastroduodenal junction. The herniated gastric walls present with concentric thickening due to edema and there is little contrast uptake due to ischemic damage. Multiple ectopic gas bubbles (white arrow) and fluid in the hernial sac due to visceral perforation are visible.



**Figure 2** Images of the surgery: A) After pushing back the left hepatic lobe, the paraesophageal hernia with the intrathoracic stomach and ischemic aspect can be observed (white arrow). B) After reducing the herniated stomach, ischemia affecting the greater curvature (white dotted line) and 3 cm perforation at the level of the curvature in the gastric body (white arrow) is seen C) Tubular gastrectomy resecting the ischemic greater curvature and gastric perforation (white arrow shows gastric tubularization; dotted white arrow shows gastric resection)..

which the rotation is over the shorter axis. The remaining 10% are mixed and undetermined forms.

Organoaxial volvulus is frequently (2/3 of the cases) secondary to PEH, traumatism, and eventration or diaphragmatic paralysis. In its acute form it can present with the classic Borchardt triad (epigastric pain, inability to vomit, and difficulty in placing the nasogastric tube),<sup>6</sup> and constitute a surgical emergency due to its frequent association with strangulation as a result of the consequent vascular compromise.

The surgical treatment of choice in these cases includes hernial reduction, the resection of ischemic tissue (total or partial gastrectomy), and repair of the hernial defect, if there is one.<sup>7</sup> Good results with laparoscopic approaches have been described for gastric volvulus in stable patients,<sup>8</sup> but its use in cases of perforation is controversial.

In our case, the deterioration of the patient and the location of the perforation led to the decision to perform partial tubular gastrectomy associated with gastropexy. We felt this was the most adequate option for extirpating the ischemic tissue, maintaining the digestive transit, avoiding the performance of a gastrointestinal anastomosis and

its potential complications, and preventing possible recurrence. The delay from the time of symptom onset to the diagnosis, together with the important subsequent clinical deterioration of the patient, conditioned the poor postoperative progression that resulted in her death.

## Financial disclosure

No financial support was received in relation to this article.

## Conflict of interest

The authors declare that there is no conflict of interest.

## Bibliografía

1. Mori T, Nagao G, Sugiyama M. Paraesophageal hernia repair. *Ann Thorac Cardiovasc Surg.* 2012;18:297–305.
2. Davis Jr SS. Current controversies in paraesophageal hernia repair. *Surg Clin North Am.* 2008;88:959–78.

3. Kim HH, Park SJ, Park MI, et al. Acute intrathoracic gastric volvulus due to diaphragmatic hernia: A rare emergency easily overlooked. *Case Rep Gastroenterol*. 2011;5:272–7.
4. Bawahab M, Mitchell P, Church N, et al. Management of acute paraesophageal hernia. *Surg Endosc*. 2009;23:255–9.
5. Lal Meena M, Jenav RK, Mandia R. Gangrenous stomach in mesenteroaxial volvulus. *Indian J Surg*. 2011;73:78–9.
6. Borchardt M. Zur pathologie und therapie des magnevolvulus. *Arch Klin Chir*. 1904;74:243–8.
7. Shafii AE, Agle SC, Zervos EE. Perforated gastric corpus in a strangulated paraesophageal hernia: A case report. *J Med Case Rep*. 2009;3:6507.
8. García MR, Peris N, Domingo C, et al. Tratamiento del vólvulo gástrico agudo mediante abordaje laparoscópico. *Cir Esp*. 2013;91:189–93.

A. Martínez-Pérez<sup>a,\*</sup>, G. Garrigós-Ortega<sup>a</sup>,  
S.A. Gómez-Abril<sup>a</sup>, T. Torres-Sánchez<sup>a</sup>, D. Uceda-Navarro<sup>b</sup>

<sup>a</sup> Servicio de Cirugía General y del Aparato Digestivo,  
Hospital Universitario Doctor Peset, Valencia, Spain

<sup>b</sup> Servicio de Radiodiagnóstico, Hospital Universitario  
Doctor Peset, Valencia, Spain

\* Corresponding author: Servicio de Cirugía General y del  
Aparato Digestivo. Hospital Universitario Doctor Peset. Av.  
Gaspar Aguilar, 90. 46017 Valencia, Spain.

E-mail address: [aleix.martinez.perez@gmail.com](mailto:aleix.martinez.perez@gmail.com)

(A. Martínez-Pérez).

10 December 2013 12 March 2014

## Colonic mass secondary to actinomycosis: A case report and literature review<sup>☆</sup>

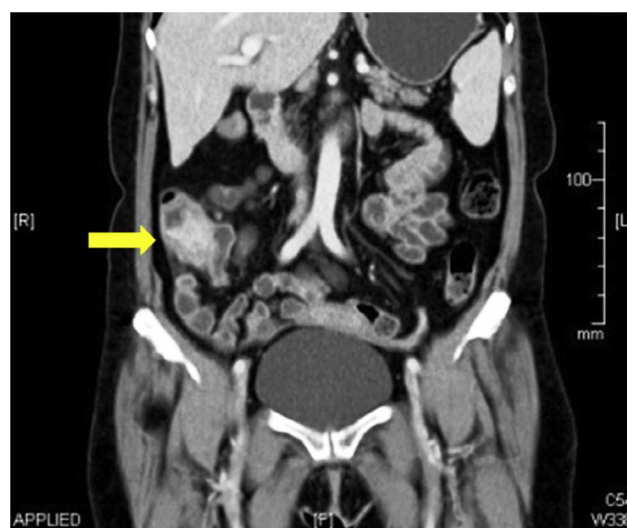

### Tumoración colónica secundaria a actinomicosis. Presentación de un caso y revisión de la literatura

*Actinomyces* spp. are Gram-positive facultative anaerobic bacteria that form part of the normal flora of the oropharynx, the gastrointestinal tract, and the female genital tract.<sup>1,2</sup> The microorganisms are opportunistic pathogens when there is disruption of the mucus membranes after inflammation, trauma, surgery, or use of an intrauterine device.<sup>3</sup> The location of up to half of the cases is cervicofacial, followed by a 20% frequency of abdominal location.<sup>4</sup>

We present the case of a 58-year-old woman that sought medical attention for abdominal pain in the right flank of 2-month progression, changes in bowel habit with constipation, and a 5 kg weight loss. Upon admittance her vital signs and laboratory tests were within normal limits. During physical examination a mass in the right iliac fossa was detected that was slightly painful upon palpation; there were no peritoneal irritation data. A strictured lesion in the cecum was encountered through colonoscopy. Biopsies were taken that only revealed nonspecific chronic inflammation. An abdominal tomography scan identified a 5 cm tumor at the level of the cecum with thickening of the wall in the terminal ileum and the cecum, along with adenopathies (fig. 1). Because there was clinical suspicion of neoplasia, the patient underwent a laparoscopic right hemicolectomy. The intraoperative finding was peritumoral adenomegalies larger than 1 cm. During macroscopic examination, a cecal appendix measuring 5 x 1.5 cm was observed with thickened walls and fibroadipose obliteration of the

lumen, along with a poorly delineated abscess-like lesion in the cecum. A pericecal abscess with extensive *Actinomyces* spp. colonization, «sulfur granules», and acute and chronic inflammation were viewed during the histopathologic study (fig. 2). Given these findings, 4-month therapy with amoxicillin plus clavulanic acid was begun. Postoperative progression was satisfactory and the patient was released 4 days after the surgery. Actinomycosis is a chronic suppurative disease that presents with the formation of fistula, sinus, inflammatory pseudotumor, or abscess. These are the characteristics that make it necessary to consider inflammatory bowel disease, inflammatory pelvic disease, and tuberculosis in the differential diagnosis. The infection can simulate malignancy due to its capacity to invade adjacent tissue and form masses.<sup>4–6</sup> Up to 80% of the cases occur in women and 60% are associated with the



**Figure 1** Abdominal tomography scan using contrast medium showing a tumor, 5 cm in diameter, at the level of the cecum, with thickening of the wall in the terminal ileum and the cecum; adenopathies are also identified.

<sup>☆</sup> Please cite this article as: Blanco-Vela CI, Luna-Ayala VM, Perez-Aguirre J. Tumoración colónica secundaria a actinomicosis. Presentación de un caso y revisión de la literatura. *Revista de Gastroenterología de México*. 2014;79:206–208.