



CLINICAL IMAGE IN GASTROENTEROLOGY

Primary anal lymphoma in a patient that underwent hemorrhoidectomy[☆]



Linfoma anal primario en un paciente operado de hemorroidectomía

C.Z. Díaz Barrientos^{a,*}, R.M. Osorio Hernández^b, T. Navarrete Cruces^b

^a Servicio de Coloproctología, Hospital Universitario de Puebla, Puebla, Mexico

^b Servicio de Coloproctología, Hospital General de México, Mexico City, Mexico

A 40-year-old man with no pathologic medical history was diagnosed with grade III hemorrhoidal disease through anoscopy. A proximal organic problem was ruled out after flexible rectosigmoidoscopy that extended up to 55 cm from the anal margin. A Ferguson hemorrhoidectomy of the 3 main bundles was performed. He was released from the hospital 24 hours after the surgery and finished his outpatient consultation at 30 days with closed wounds and no signs of infection. The histopathologic study reported hemorrhoidal bundles with ingurgitation. He returned 45 days after his release from the outpatient service complaining of anal pain, the sensation of a mass, bleeding, and diarrhea. Physical examination revealed a circumferential, indurated, 8 × 8 cm tumor in the perianal region with a hyperemic and bluish-purple appearance (fig. 1). It was limited to the anal duct and did not involve the rectum. The ELISA test for HIV was carried out and confirmed by a positive Western-Blot test; this test had not been done prior to the surgery. A biopsy was taken and the histopathologic study

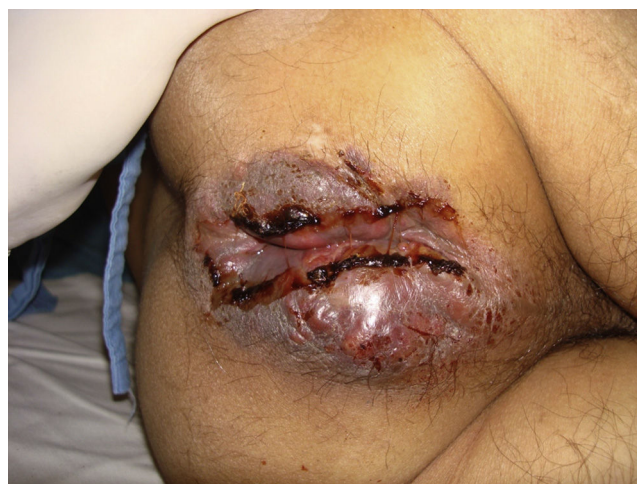

Figure 1 Anal tumor upon admission to the emergency department.

with immunohistochemistry reported diffuse non-Hodgkin lymphoma with immunophenotype B. A computed tomography scan of the neck, chest, abdomen, and pelvis showed no evidence of nodal lymphoma and the bone marrow biopsy was normal. The patient was referred to the hematology department; he refused chemotherapy treatment and died 3 months later (fig. 2).

[☆] Please cite this article as: Díaz Barrientos CZ, Osorio Hernández RM, Navarrete Cruces T. Linfoma anal primario en un paciente operado de hemorroidectomía. Revista de Gastroenterología de México. 2014;79:292–293.

* Corresponding author. Diagonal Zaragoza 5128 Consultorio 208 Colonia San Manuel Puebla, Puebla México, Código Postal 72570, Phone number: +22 25769091.

E-mail address: cher_zilahy@hotmail.com (C.Z. Díaz Barrientos).

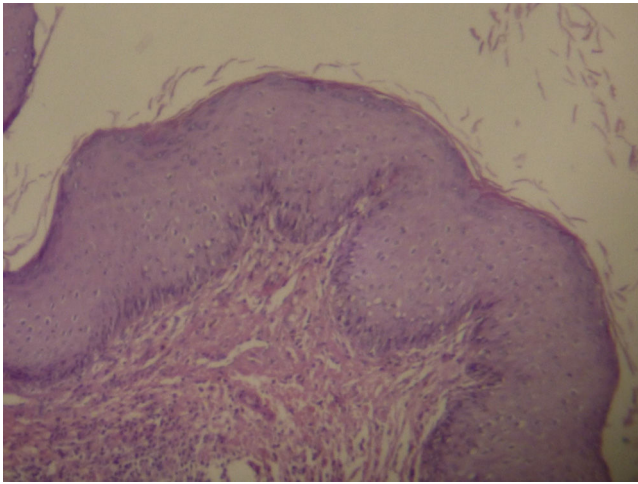


Figure 2 Histopathologic slide of the anal tumor.

Financial disclosure

No financial support was received in relation to this study/article.

Conflict of interest

The authors declare that there is no conflict of interest.