

- cholangiopancreatography: Case report and literature review. *Gastroenterol Clin Biol.* 2007;31:750–2.
5. De La Serna-Higuera C, Fuentes Coronel A, Rodríguez Gómez S, et al. Subcapsular hepatic hematoma secondary to the use of hydrophilic guidewires during endoscopic retrograde cholangiopancreatography. *Gastroenterol Hepatol.* 2008;31:266–7.
 6. Cárdenas A, Crespo G, Balderramo D, et al. Subcapsular liver hematoma after endoscopic retrograde cholangiopancreatography in a liver transplant recipient. *Ann Hepatol.* 2008;7:386–8.
 7. Burhans R, Myers R. Benign neoplasms of the extrahepatic biliary ducts. *Am Surg.* 1971;37:161–6.
 8. Chu P. Benign tumors of extrahepatic biliary ducts. *Arch Path.* 1950;50:84.
 9. Ohike N, Kim G, Tajiri T, et al. Intra-ampullary papillary-tubular neoplasm (IAPN): Characterization of tumoral intraepithelial neoplasia occurring within the ampulla: A clinicopathologic analysis of 82 cases. *Am J Surg Pathol.* 2010;34:1731–48.
 10. Sotona O, Cecka F, Neoral C, et al. Papillary adenoma of the extrahepatic biliary tract—a rare cause of obstructive jaundice. *Acta Gastroenterol Belg.* 2010;73:270–3.
- C. Curvale*, M. Guidi, I. Málaga, H.J. Hwang, R. Matanó
Gastroenterology Service, Hospital de Alta Complejidad en Red "El Cruce"-Néstor Carlos Kirchner, Buenos Aires, Argentina
- *Corresponding author. Boulogne Sur Mer 478 – Piso 7mo Dpto 24 – CABA, Argentina. Phone: +54 – 11 - 48644645.
E-mail address: cecicurvale@hotmail.com (C. Curvale).

Human fasciolosis diagnosed in the acute phase: A first clinical report in Mexico[☆]



Fasciolosis humana diagnosticada en fase aguda. Primer reporte clínico en México

Fasciolosis is a zoonosis caused by *Fasciola hepatica* that affects sheep, cattle, and occasionally, humans. In the latter, 2 phases are distinguished: the acute phase and the chronic phase.¹

Figure 1 one illustrates the sequential biologic cycle.²

Acute phase symptomatology is fever of 38 °C, important eosinophilia, abdominal skin rash, and pain in the right hypochondrium. Diagnostic methods in this phase are a complete blood count that shows blood eosinophilia and anti-*Fasciola hepatica* antibodies. Stool exams in this phase are negative.³

The chronic phase is characterized by adult *Fasciola* in the biliary tract, causing diarrhea that can be steatorrheic, fever, pain in the right hypochondrium, and weight loss. Eosinophilia can be mild or absent and eggs are found in fecal material.^{4,5}

We present herein the clinical case of a 34-year-old man, resident of Puebla, Mexico, that stated during the medical interview that he had eaten fish with some type of green topping one week before symptom onset, which was characterized by a skin rash on his face, neck and chest, flatulence with borborygmi, and liquid stools with no blood (3 in 24 h).

The patient then presented with fever of 38 °C, headache, myalgia, pain in the right hypochondrium that radiated to the ipsilateral lumbar region, and weight loss of 4 kg in 3 weeks.

The Widal test was negative, but due to the clinical suspicion of typhoid fever, he was given 3 g daily of ampicillin for 10 days with no improvement.

Because of the lack of treatment response, the patient sought medical attention at the Clinical Parasitology Service of the Faculty of Medicine of the BUAP. New laboratory tests reported: complete blood count: erythrocytes 4.9 mm³, hemoglobin 14.5 g/dL, hematocrit 45%, MCV 91 fl, MCHC 32 g/dL. Leukocytes 9.15 thousand/μL, with differential count of: lymphocytes 2.19 thousand/μL neutrophils 2.56 thousand/μL, eosinophils 4.11, thousand/μL basophils 0.18 thousand/μL, and monocytes 0.09 thousand/μL.

Because of the high percentage of eosinophils, complete blood count was repeated 8 days later with the following results: erythrocytes 5.0 mm³, hemoglobin 14.7 g/dL, hematocrit 46%, leukocytes 10.87 thousand/μL, lymphocytes 1.63 thousand/μL, neutrophils 2.82 μL, eosinophils 6.19 thousand/μL, basophils 0.0 thousand/μL, and monocytes 0.21 thousand/μL.

The stool exams were performed using the sedimentation technique. Six samples were negative and Enterotest[®] (Beal Capsule) was negative for cysts, trophozoites, and parasitic eggs.

Counterimmunoelectrophoresis (CIE) was carried out to search for anti-*Fasciola hepatica* antibodies (fig. 2).

The patient was treated with 1 mg/kg of weight of intramuscular dehydroemetine for 10 days with total symptom remission.

The present case corresponds to acute (or invasive) phase fasciolosis and is the first of its kind to be reported in Mexico. In Peru, where fasciolosis is endemic, a review carried out from 1963 to 2005 reported a total of 1,701 cases, only 11% of which were diagnosed in the invasive phase and 89% were diagnosed with full-blown disease, corroborating the difficulty of diagnosis in the acute phase.⁶ As illustrated by the present report, due to its polymorphic symptomatology, physicians do not usually consider this pathology in the differential diagnosis and patients undergo numerous studies and treatments before being correctly diagnosed.⁷

An important datum is a history of watercress ingestion, which has been identified in national studies in up to 49% of the cases; this history was not obtained or was not reported in 23 and 28% of the cases, respectively. Our patient stated that he was not familiar with watercress, but he did say he had eaten a vegetable topping before clinical symptom

[☆] Please cite this article as: Cruz y López OR, Gómez de la Vega E, Cárdenas-Perea ME, Gutiérrez-Dávila A, Tamariz-Cruz OJ. Fasciolosis humana diagnosticada en fase aguda. Primer reporte clínico en México. *Revista de Gastroenterología de México.* 2016;82:111–113.

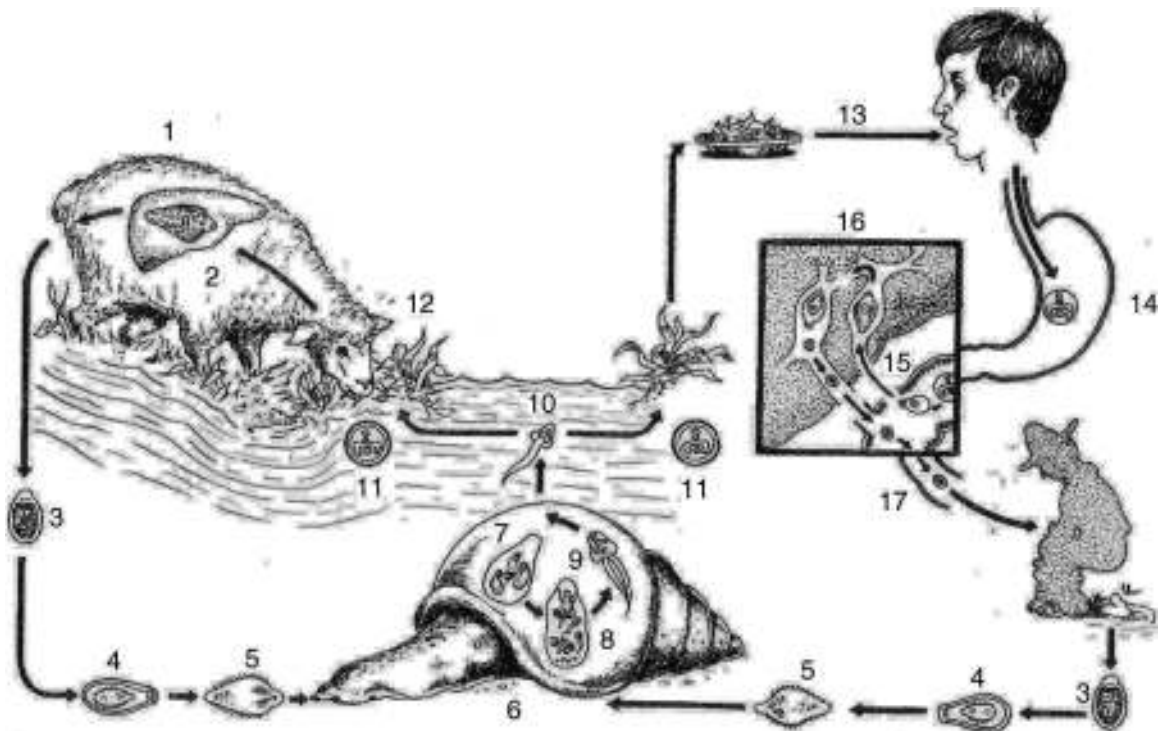


Figure 1 The habitat of adult *Fasciola hepatica* is in the bile ducts of sheep (1,2). When the eggs are passed into an aquatic environment through feces (3), a ciliated parasite (miracidium) develops inside them (4, 5) that searches for a *Lymnaeidae* snail (6) and transforms inside it into a sporocyst, mother redia, daughter redia, and cercaria (7, 8, 9). The latter abandons the snail (10) adopting the cystic form of a metacercaria (11) and adheres to different aquatic plants that are eaten by sheep (12). It reaches the duodenum, forming tunnels in the tissue until reaching the liver (1, 2). The acute phase in humans begins when an individual becomes infected by eating watercress (*Nasturtium officinale*) that contains metacercariae, transforming in the duodenum into adolocercariae (13-15). They penetrate the tissues through proteases until reaching the liver parenchyma, adopting the adult form in a period of 4 to 6 months. The habitat of the adult *Fasciola* is in the bile ducts, causing the chronic or full-blown disease phase that can last months or years (16,17). (Source: Modified from: Cruz López O.²)

onset. Recent reports link fasciolosis with radish ingestion, and to a lesser degree with the ingestion of turnips, spinach, and lettuce, results that require further investigation.⁸

And finally, our patient was treated with dehydroemetine, due to the nonavailability of the drug that is currently considered the treatment of choice: triclabendazole at an

oral dose of 10 mg/Kg. Studies have reported the usefulness of nitazoxanide, but the results are still inconclusive.⁹

We presented this report in the hope it can be useful in the study of patients with eosinophilia and their early treatment.

Ethical responsibilities

Protection of persons and animals. The authors declare that no experiments were performed on humans or animals for this study.

Data confidentiality. The authors declare that no patient data appear in this article.

Right to privacy and informed consent. The authors declare that no patient data appear in this article.

Financial disclosure

No financial support was received in relation to this article.




Figure 2 Counterimmunoelectrophoresis. Upper wells: controls; lower wells: patient and control.

Conflict of interest

The authors declare that there is no conflict of interest.

Acknowledgements

The authors wish to thank Dr. Manuel Gutiérrez-Quiroz, Head of the Department of Immunoparasitology of the UNAM for providing the antigen used in our study.

References

1. Carrada-Bravo T. Fasciolosis diagnosis, epidemiology and treatment. *Rev Gastroenterol Mex.* 2003;68:135–42.
2. Cruz López O. Fasciolosis. Cap. 9. In: Cruz López O, editor. *Parasitología*. 2.ª edición México, D.F: Méndez Oteo Editores; 1995. p. 279–86.
3. Sánchez Vega JT, Tay Zavala J, Salinas Velasco R, et al. Fasciolosis. Presentación de un caso y comentarios acerca de esta trematodiosis. *Rev Mex Pediatr.* 2001;68:17–20.
4. Cruz-López O, Adán-Pimentel A, Tamariz-Cruz O, et al. Fasciolosis hepática diagnosticada en fase de estado. *Rev Gastroenterol Mex.* 2006;71:59–62.
5. Vázquez G, Zavala-García C, Elizondo J, et al. Infestación por fasciola hepática en la vía biliar. *Médica Sur.* 2007;14:14–7.
6. Marcos LA, Terashima A, Leguía G, et al. La infección por Fasciola hepática en el Perú: una enfermedad emergente. *Rev Gastroenterol Per.* 2007;27:389–96.
7. Díaz-Fernández R, Garcés-Martínez M, Millán-Álvarez L, et al. Comportamiento clínicoterapéutico de fasciola hepática en una serie de 87 pacientes. *Rev Cubana Med Trop.* 2011;63:268–74.
8. Tay J, DeHaro I, Salazar PM, et al. Estado actual de nuestros conocimientos sobre fasciolosis en la República Mexicana. *Rev Mex Patol Clin.* 1986;33:41–6.
9. Zumaquero-Rios JL, Sarracent-Pérez J, Rojas García R, et al. Fascioliasis and intestinal parasitosis affecting school-children in Atlixco, Puebla State Mexico: Epidemiology and treatment with nitazoxanide. *PLoS Negl Trop Dis.* 2013;7:e2553.

O.R. Cruz y López^{a,*}, E. Gómez de la Vega^a, M.E. Cárdenas-Perea^a, A. Gutiérrez-Dávila^a, O.J. Tamariz-Cruz^b

^a *Departamento de Agentes Biológicos, Facultad de Medicina, Benemérita Universidad Autónoma de Puebla, Puebla, Mexico*

^b *Instituto Nacional de Pediatría, Programa KARDIAS/ABC, Centro Médico ABC, Mexico City, Mexico*

*Corresponding author. Departamento de Agentes Biológicos, Facultad de Medicina, Benemérita Universidad Autónoma de Puebla. Calle 13 Sur Numero 2702, Tercer Piso. Col. Volcanes. CP 72410 Puebla, Puebla, México. Tel.: +229 35 00 ext. 5645, cell phone: 2224555289. E-mail address: othoncruz@yahoo.com (O.R. Cruz y López).

Proton pump inhibitor-responsive esophageal eosinophilia: A new entity in search of recognition?[☆]



Eosinofilia esofágica sensible a inhibidores de la bomba de protones. ¿Nueva entidad en busca de reconocimiento?

Eosinophilic esophagitis (EoE) has been a well-recognized pathologic entity in adults since 1978. Its clinical characteristics, treatment, and progression have been extensively studied over the last years. However, it has recently been described to form part of a group of clinical entities characterized by the infiltration of eosinophils in the esophageal mucosa together with gastroesophageal reflux disease (GERD) and proton-pump inhibitor-responsive esophageal eosinophilia (PPI-REE). Based on the above, we decided to present herein the case of a patient with

esophageal eosinophilic infiltration diagnosed with PPI-REE, given his favorable response to these drugs.

A 50-year-old man sought medical attention due to intermittent dysphagia, retrosternal pain, and heartburn. He had a past history of hemorrhoidectomy and appendectomy years before and seafood allergy. Six months earlier, he had been seen by another gastroenterologist for the same symptoms, underwent endoscopy with no esophageal biopsy, was diagnosed with esophageal candidiasis, and prescribed oral nystatin. His blood count and biochemical profile were normal.

We decided to perform another endoscopy and it revealed an abundant whitish mottled pattern in the esophageal mucosa with some areas of exudate and edema (Fig. 1A). No hiatal hernia or erosions were observed and the junctional epithelium had a normal aspect. Eight biopsy samples were taken from the mucosa of the upper and lower third of the esophagus and the pathologist reported the presence of an abundant eosinophilic infiltrate in the epithelium (from 18 to 52 per high power field [HPF]) (Fig. 1B). Twenty-four hour esophageal pH impedance monitoring was normal. The patient was treated with 40 mg of oral pantoprazole every 12 h for 2 months. After that treatment, endoscopy with biopsy was repeated, which showed endoscopic improvement of the mucosa (Fig. 2A), and in the biopsy there was significant reduction of the eosinophilic infiltrate (1 to 3 eosinophils per HPF) (Fig. 2B). The patient stated that he had a significant decrease in the intensity of

[☆] Please cite this article as: García-Compeán D, González-González JA, González-Moreno EI, Barrera-Villarreal E, Maldonado-Garza HJ. Eosinofilia esofágica sensible a inhibidores de la bomba de protones. ¿Nueva entidad en busca de reconocimiento? *Revista de Gastroenterología de México.* 2016;82:113–115.