



## CLINICAL IMAGE IN GASTROENTEROLOGY

### Hydatid cyst of the liver<sup>☆</sup>

### Quiste hidatídico hepático



U.G. Rossi<sup>a,\*</sup>, G. Rubis Passoni<sup>b</sup>, M. Cariati<sup>a</sup>

<sup>a</sup> Department of Radiology and Interventional Radiology, San Carlo Borromeo Hospital, Milano, Italy

<sup>b</sup> Endoscopy Unit, Hospital Department of Gastroenterology and Hepatology, San Carlo Borromeo Hospital, Milano, Italy

A 37-year-old man was evaluated for a 6-month history of upper abdominal pain with weight loss. Physical examination revealed a palpable mass at the left lobe of the liver. There was no associated fever or chills. Laboratory data showed a mild elevation of serum ALT (117 U/l), direct bilirubin (1.8 mg/dl), and white blood cells ( $11.7 \times 10^9/l$ ).

He underwent abdominal contrast-enhanced phase multi-detector computed tomography and the axial and coronal

views (figs. 1A and B) demonstrated a large 16.3 cm formation that had completely replaced the left lobe of the liver, with a dense central area and multiple low-attenuation round vesicles located peripherally and delimited by linear membranes. Diagnosis was hydatid cyst of the left lobe of the liver, with the mother cyst in the centre and the daughter vesicles in the peripheral location. The presence of the specific antibody to the echinococcus antigen confirmed the

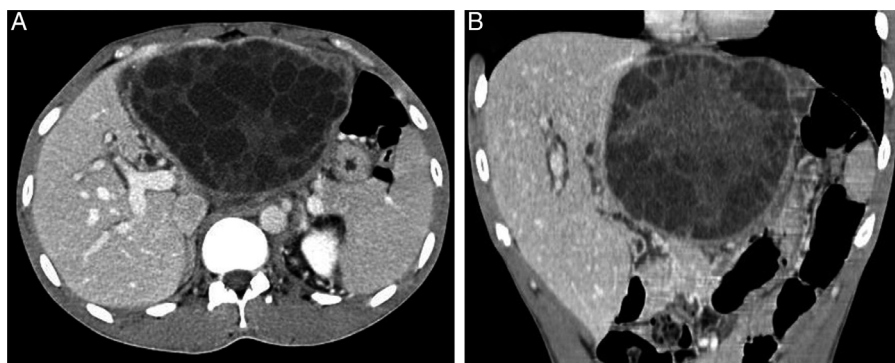


Figure 1 Axial (A) and coronal (B) views of the computerized tomography.

<sup>☆</sup> Please cite this article as: Rossi UG, Rubis Passoni G, Cariati M. Quiste hidatídico hepático. Revista de Gastroenterología de México. 2016;82:105–106.

\* Corresponding author. San Carlo Borromeo Hospital, Department of Radiology and Interventional Radiology, Via Pio II, 3, 20153 Milano, Italy. Phone: ++39 02 40222465; fax: ++39 02 40222465.

E-mail address: [urossi76@hotmail.com](mailto:urossi76@hotmail.com) (U.G. Rossi).

radiological diagnosis. The patient underwent medical and surgical therapy.

### **Ethical responsibilities**

**Protection of persons and animals.** The authors declare that no experiments on humans or animals were carried out in relation to this study.

**Data confidentiality.** The authors declare that no patient data appear in this article.

**Right to privacy and informed consent.** The authors declare that no patient data appear in this article.

### **Financial disclosure**

No financial support was received in relation to this study/article.

### **Conflict of interest**

The authors declare that there is no conflict of interest.