

Gastrointestinal graft-versus-host disease. What is the role of capsule endoscopy? A case series[☆]



Enfermedad injerto contra huésped gastrointestinal. ¿Cuál es el papel de la cápsula endoscópica? Serie de casos

Allogeneic hematopoietic cell transplantation (AHCT) is an essential part of the therapeutic treatment of malignant hematologic diseases. It has been associated with frequent complications, such as infections and graft-versus-host disease (GVHD). The skin, digestive tract, and biliary tract are the main organs affected by GVHD. It is the most important complication and is associated with high morbidity and mortality. This pathology is divided into acute and chronic disease, depending on whether it presents before or after the first 100 post-transplantation days.^{1,2}

Gastrointestinal GVHD can manifest as nausea, anorexia, vomiting, bloating, diarrhea, abdominal pain, bleeding, ileus, weight loss, and fever with negative cultures. It is associated with an 80% mortality rate, especially in cases that do not respond to first-line treatment.^{2,3} In regard to its gastrointestinal involvement, GVHD diagnosis is based on panendoscopy and colonoscopy, taking biopsy samples from the antrum, duodenum, and colon. However, the small bowel is the most affected area, given that it is the most extensive immune organ.⁴

GVHD can present in the small bowel in different manners, affecting it by segments or in its totality. The main findings in this organ are edema, erythema, erosions, ulcers, and bleeding.⁵ Capsule endoscopy (CE) is a noninvasive tool that allows us to observe the entire small bowel⁶ and can be very useful in accelerating GVHD diagnosis. The aim of this report is to communicate the usefulness of CE in patients suspected of presenting with gastrointestinal GVHD.

Case 1

A 25-year-old man was diagnosed with paroxysmal nocturnal hemoglobinuria. He underwent AHCT on May 14, 2015. Thirty days later he presented with abdominal distension, nausea, and diarrhea. Panendoscopy and colonoscopy with biopsy were performed and the CE capsule was simultaneously placed. It revealed flattened villi in the small bowel, as well as edema of the mucosa and vascular pattern loss. Denudation of the mucosa was present in some segments, along with fibrin-covered ulcers, fresh blood, and clots. The CE capsule was moved into the duodenum through endoscopy after remaining in the stomach for 6 h. GVHD diagnosis was corroborated through histopathology one week later. The

patient did not respond to initial management and so was given second-line treatment. He responded adequately and was released from the hospital.

Case 2

A 37-year-old man was diagnosed with chronic myeloid leukemia. He underwent AHCT on June 30, 2015. Twenty-nine days after the transplantation he was admitted to the hospital with diarrhea, nausea, and vomiting. Panendoscopy and colonoscopy with biopsy were performed, together with CE capsule placement. The capsule identified flattened villi in the entire small bowel, along with denudation of the mucosa, ulcers that caused areas of stricture, and active bleeding. The histopathology study confirmed the GVHD diagnosis 10 days later. The patient is currently receiving second-line treatment for steroid-refractory disease.

Case 3

A 45-year-old man was diagnosed with acute myelomonocytic leukemia and underwent AHCT on June 4, 2015. On the 54th day after the transplantation, he presented with intermittent colicky abdominal pain, diarrhea, nausea and vomiting, and he could not tolerate an oral diet. Two days later he presented with hematochezia on 17 occasions. Panendoscopy and colonoscopy with biopsy were performed. The CE capsule was placed and showed shortening of the villi in the jejunum and ileum, as well as erosions and active bleeding in different areas. The capsule was moved into the duodenum through endoscopy after remaining in the stomach for 4 h. The gastrointestinal GVHD diagnosis was confirmed through histology 5 days later. The patient is currently responding to second-line treatment with infliximab.

Acute GVHD is a life-threatening complication of AHCT. Intestinal involvement occurs in up to 46% of the cases. The usefulness of CE in diagnosing this disease is becoming increasingly relevant. Neumann et al. demonstrated that CE has the same sensitivity and specificity as panendoscopy with biopsy in acute intestinal GVHD.⁷ They also found that it has a 100% negative predictive value, as previously reported by Yakoub-Agha, et al.⁸ The greatest associated impediment is gastric retention of the capsule, which can occur in 10.5–18% of the cases, due to a probable gastric hypomotility observed in these patients.^{4,8} This can be resolved through the use of real time recorders and by endoscopically advancing the capsules that have remained in the stomach for long periods. The principal differential diagnosis is viral infection, which must be previously ruled out. In our cases, GVHD diagnosis by CE was made prior to the histopathology report, thus treatment was begun early (fig. 1A and B).

In conclusion, even though panendoscopy and colonoscopy with biopsy is the criterion standard, CE is a noninvasive method that can aid in the diagnosis of gastrointestinal GVHD. With this method, it is not necessary to wait for the histopathologic result and the risks involved in invasive endoscopic explorations are avoided. A larger number of cases are required to confirm that CE is a complementary diagnostic method in gastrointestinal GVHD.

[☆] Please cite this article as: Blanco-Velasco G, Cuba-Sascó C, Hernández-Mondragón OV, Paz-Flores V, Blancas-Valencia JM. Enfermedad injerto contra huésped gastrointestinal. ¿Cuál es el papel de la cápsula endoscópica? Serie de casos. *Revista de Gastroenterología de México*. 2017;82:191–192.

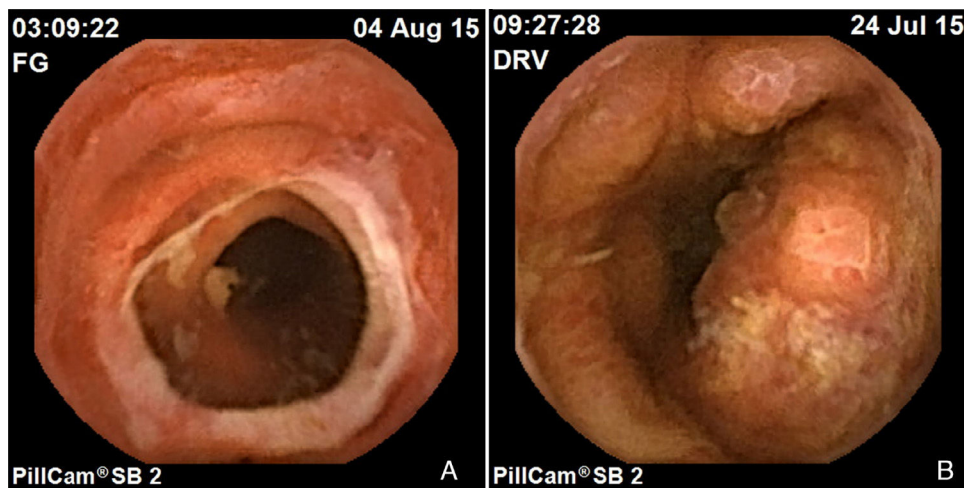


Figure 1 Enteritis due to GVHD. A) Stricture secondary to ulcer. B) Mucosa with villi loss, erosions, and ulcers.

Funding

No financial support was received in relation to this study.

Conflict of interest

The authors declare that there is no conflict of interest.

References

1. Kreisel W, Dahlberg M, Bertz H, et al. Endoscopic diagnosis of acute intestinal GVHD following allogenic hematopoietic SCT: A retrospective analysis in 175 patients. *Bone Marrow Transplant.* 2012;47:430–8.
2. Velasco-Guardado A, López-Corral L, Álvarez-Delgado A, et al. Evaluación endoscópica y hallazgos histológicos en la enfermedad de injerto contra huésped. *Rev Esp Enferm Dig.* 2012;104:310–4.
3. Castilla-Llorente C, Martin PJ, McDonald GB, et al. Prognostic factors and outcomes of severe gastrointestinal graft-vs-host disease after allogenic hematopoietic cell transplantation. *Bone Marrow Transplant.* 2014;49:966–71.
4. Gómez-Espín R, López-Higueras A, Gallego P, et al. Utilidad de la cápsula endoscópica de intestino delgado en la enfermedad de injerto contra huésped (EICH). *RAPD online.* 2012;35:87–92.
5. Varadarajan P, Dunford LM, Thomas A, et al. Seeing what's out of sight: Wireless capsule endoscopy's unique ability to visualize and accurately assess the severity of gastrointestinal graft-versus-host disease. *Biol Blood Marrow Transplant.* 2009;15:643–8.
6. Pennazio M, Spada C, Eliakim R, et al. Small-bowel capsule endoscopy and device-assisted enteroscopy for the diagnosis and treatment of small-bowel disorders: European Society of Gastrointestinal Endoscopy (ESGE) Clinical Guideline. *Endoscopy.* 2015;47:352–76.
7. Neumann S, Schoppmeyer K, Lange T, et al. Wireless capsule endoscopy for diagnosis of acute intestinal graft-versus-host disease. *Gastrointest Endosc.* 2007;65:403–9.
8. Yakoub-Agha I, Maunoury V, Wacrenier A, et al. Impact of small bowel exploration using video capsule endoscopy in the management of acute gastrointestinal graft-versus-host disease. *Transplantation.* 2004;78:1697–701.

G. Blanco-Velasco*, C. Cuba-Sascó,
O.V. Hernández-Mondragón, V. Paz-Flores,
J.M. Blancas-Valencia

Endoscopy Service, Hospital de Especialidades, Centro Médico Nacional Siglo XXI, Instituto Mexicano del Seguro Social, Mexico City, Mexico

* Corresponding author. Avenida Cuauhtémoc 330, Colonia Doctores, Delegación Cuauhtémoc, C.P. 06720, Mexico City, Mexico. Tel.: 5523077204 / 56276900 ext. 21317-21318.

E-mail address: gerardoblancov@hotmail.com
(G. Blanco-Velasco).

2255-534X/

© 2016 Asociación Mexicana de Gastroenterología. Published by Masson Doyma México S.A. This is an open access article under the CC BY-NC-ND license (<http://creativecommons.org/licenses/by-nc-nd/4.0/>).