



REVISTA DE GASTROENTEROLOGÍA DE MÉXICO

www.elsevier.es/rgmx



CLINICAL IMAGE IN GASTROENTEROLOGY

Endobiliary radiofrequency for iatrogenic bile duct lesion and hilar cholangiocarcinoma[☆]



Radiofrecuencia endobiliar para lesiones iatrogénicas de la vía biliar y colangiocarcinoma hilar

U.G. Rossi^{a,*}, P. Rigamonti^{a,b}, M. Cariatì^a

^a Department of Diagnostic Sciences – Division of Radiology and Interventional Radiology, San Carlo Borromeo Hospital, Milan, Italy

^b Department of Gastroenterology – Division of Endoscopy, San Carlo Borromeo Hospital, Milan, Italy

An 82-year-old man that had hilar biliary obstruction with right percutaneous internal-external biliary drainage (fig. 1A) underwent transluminal biliary forceps biopsy at the level of the hepatic hilum, resulting in iatrogenic injury (a small tear with a leak) to the bile duct with consequent intrahepatic collection (fig. 1B). The biopsy revealed malignant hilar cholangiocarcinoma, making the patient a candidate for palliative care. He underwent percutaneous endobiliary bipolar radiofrequency (Habib® EndoHPB; EMCision, London, UK) (fig. 1C) for: a) cauterizing the bile duct injury with the persistent intrahepatic collection, and b)

prolonging stent patency through partial tumor ablation and consequent tumor growth delay. In the same operating session, the bile duct lesion was treated with endobiliary radiofrequency and self-expandable bare metal stents with a T-configuration (10 x 80mm Zilver® Biliary Self-Expanding Stent, Cook Medical, Bloomington, IN, USA; and 10 x 100mm LCD® Biliary Stent, Taewoong Medical Co., Republic of Korea) were placed, resulting in significant reduction in the size of the endobiliary tumor mass (fig. 1D). Clinical and ultrasound follow-up at 4 months revealed no complications.

[☆] Please cite this article as: Rossi UG, Rigamonti P, Cariatì M. Radiofrecuencia endobiliar para lesiones iatrogénicas de la vía biliar y colangiocarcinoma hilar. Revista de Gastroenterología de México. 2016;82:172–173.

* Corresponding author. Department of Diagnostic Sciences – Division Radiology and Interventional Radiology, San Carlo Borromeo Hospital, Via Pio II, 3; 20153 Milan, Italy.

Tel.: +0039 02 49222465; fax: +0039 02 49222465.

E-mail address: urossi76@hotmail.com (U.G. Rossi).

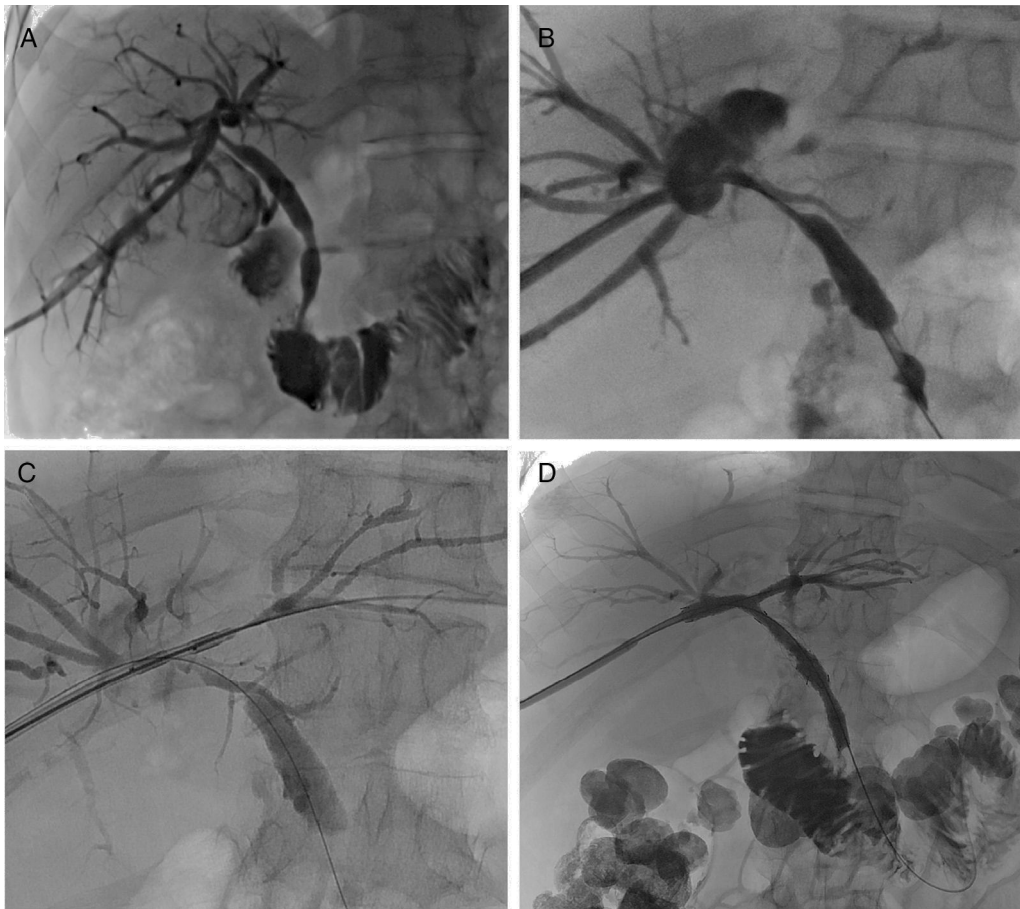


Figure 1 A) Cholangiography showing the right percutaneous internal-external biliary drainage, positioned for a suspected malignant hilar biliary obstruction. B) Cholangiography after transluminal biliary forceps biopsy at the level of the hepatic hilum that shows the iatrogenic injury to the bile duct with an intrahepatic collection. C) Radiologic control during percutaneous endobiliary bipolar radiofrequency at the level of the hepatic hilum. D) Final cholangiography showing improvement of the bile duct lesion, good expansion of the self-expandable bare metal stents with a T-configuration, and correct passage of the contrast agent from the biliary system into the duodenum.

Ethical responsibilities

Protection of persons and animals. The authors declare that no experiments were performed on humans or animals for this study.

Data confidentiality. The authors declare that no patient data appear in this article.

Right to privacy and informed consent. The authors declare that no patient data appear in this article.

Financial disclosure

No financial support was received in relation to this study/article.

Conflict of interest

The authors declare that there is no conflict of interest.