



CLINICAL IMAGE IN GASTROENTEROLOGY

## Giant right inguinal hernia<sup>☆</sup>

### Hernia inguinal derecha gigante

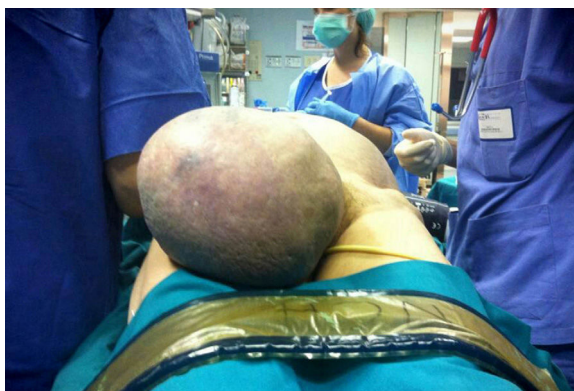
U.G. Rossi<sup>\*</sup>, P. Torcia, M. Cariati



Department of Diagnostic Science, Radiology and Interventional Radiology Unit,  
ASST Santi Paolo and Carlo – San Carlo Borromeo Hospital, Milan, Italy

A 67-year-old woman from a rural residence arrived at our emergency department presenting with a large right inguinal mass that had progressed in size over 10 years, now with acute onset of right inguinal pain and nausea.

Clinical examination revealed a large right inguinal hernia, 20 cm in length and 18 cm in width (fig. 1). The hernia



**Figure 1** Clinical examination that demonstrates the presence of the giant right inguinal hernia.

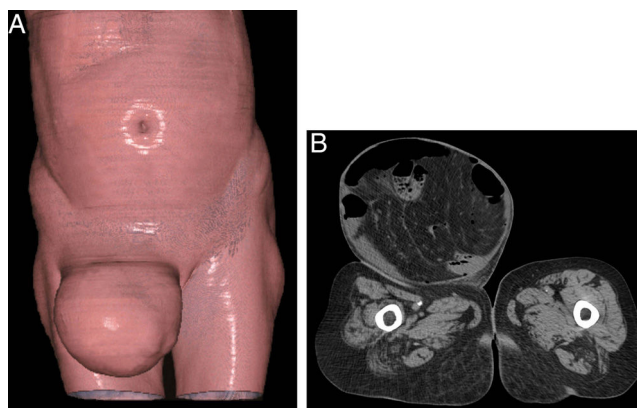
<sup>☆</sup> Please cite this article as: Rossi UG, Torcia P, Cariati M. Giant right inguinal hernia. *Revista de Gastroenterología de México*. 2017;82:85–86.

<sup>\*</sup> Corresponding author. Department of Diagnostic Science, Radiology and Interventional Radiology Unit, ASST Santi Paolo and Carlo – San Carlo Borromeo Hospital, Via Pio II, 3, 20153 Milan, Italy. Tel.: +39 02 40222465; Fax: +39 02 40222465.

E-mail address: [urossi76@hotmail.com](mailto:urossi76@hotmail.com) (U.G. Rossi).

was non-reducible when gentle pressure was applied and so a strangulated right inguinal hernia was diagnosed. The patient underwent abdominal computed tomography that identified a large right inguinal hernia with an initial radiologic sign of bowel suffering (fig. 2 A-B). The patient underwent urgent open surgical repair of the strangulated right inguinal hernia. No signs of bowel infarction were noted during the surgery. The postoperative course was uneventful and the patient was discharged on day 2.

Inguinal hernias are predominant in males and there is a higher age-related incidence in men in their fifties and



**Figure 2** A) Coronal Computed Tomography Volume Rendering Technique image that demonstrates the presence of the large right inguinal hernia. B) Axial Computed Tomography image that shows a direct hernia passing through the inguinal canal with bowel segment protrusion.

sixties. In females, chronic cough, older age, taller height, and rural residence have been associated with a higher incidence of inguinal hernia.<sup>1,2</sup> Giant inguinal hernia, however, is more unusual and significantly challenging in terms of surgical management.<sup>3</sup> For our case, rural residence and older age were the two main factors for the development of such a large inguinal hernia.

### Ethical responsibilities

**Protection of persons and animals.** The authors declare that no experiments on humans or animals were carried out in relation to this study.

**Data confidentiality.** The authors declare that no patient data appear in this article.

**Right to privacy and informed consent.** The authors declare that no patient data appear in this article.

### Financial disclosure

No financial support was received in relation to this study/article.

### Conflict of interest

The authors declare that there is no conflict of interest.

### References

1. McIntosh A, Hutchinson A, Roberts A, et al. Evidence-based management of groin hernia in primary care —a systematic review. *Fam Pract.* 2000;17:442–7.
2. Ruhl CE, Everhart JE. Risk factors for inguinal hernia among adults in the US population. *Am J Epidemiol.* 2007;165:1154–61.
3. Trakarnsagna A, Chinswangwatanakul V, Methasate A, et al. Giant inguinal hernia: Report of a case and reviews of surgical techniques. *Int J Surg Case Rep.* 2014;5:868–72.