



CLINICAL IMAGE IN GASTROENTEROLOGY

Giant inguinoscrotal hernia

Hernia gigante inguino-escrotal



J.E. Baca-Prieto^a, L.G. Domínguez-Carrillo^{b,*}

^a *Gastrosurgery Division, Hospital Ángeles León, León, Guanajuato, Mexico*

^b *Rehabilitation Department, School of Medicine of León, Universidad de Guanajuato, León, Guanajuato, Mexico*

A 55-year-old man with a 30-year history of giant inguinoscrotal hernia (fig. 1) came to the emergency department due to urinary obstruction. A Foley catheter was placed and an abdominal angiotomography scan was carried out that revealed the small bowel within a right inguinoscrotal hernial sac with no vascular involvement (figs. 2 and 3). Laboratory test values were normal. The patient was admitted to the hospital and a Tenckhoff catheter was placed by means of a Veress needle in the left abdominal upper quadrant (fig. 4). The abdominal cavity was insufflated with 800 to 1,000 cc of environmental air. The intra-abdominal pressure was monitored through the Foley catheter connected to an electric pressure transducer. The maximum intra-abdominal pressure gradually reached was 20 cmH₂O, corresponding to 27.9 mmHg. On the tenth day of hospitalization, surgery was carried out to place the bowel in the abdominal cavity and resect the hernial sac. The abdominal wall was strengthened with composite mesh. There were no postoperative complications (fig. 5). This type of surgery is the treatment model that can be offered to patients with giant inguinoscrotal hernia,^{1–3} enabling satisfactory quality of life.

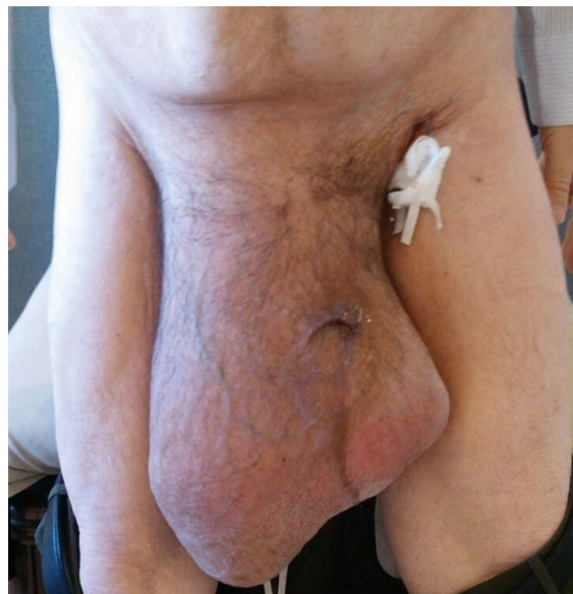

Figure 1 A 55-year-old man with a 30-year history of right inguinoscrotal hernia.

* Corresponding author. Calzada Los Paraísos 701, Col. Los Paraísos, León, Gto., C.P. 37320, Mexico.

E-mail address: lgdominguez@hotmail.com
(L.G. Domínguez-Carrillo).

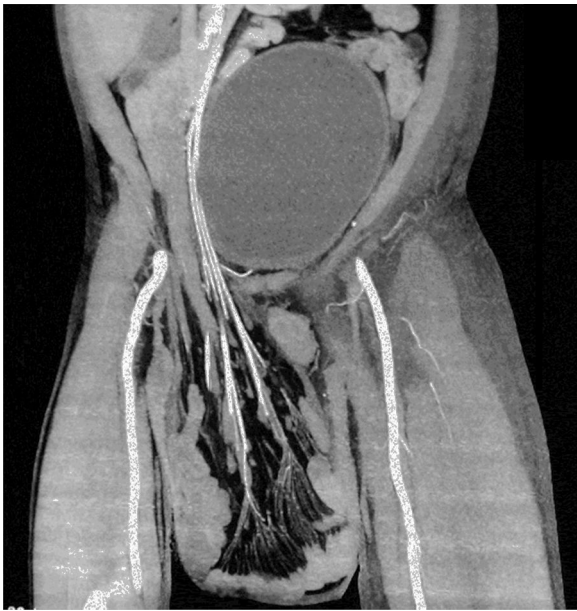

Figure 2 Coronal view of abdominal angiogram scan showing small bowel segments in the extra-abdominal hernial sac, with no vascular involvement, and a full bladder.

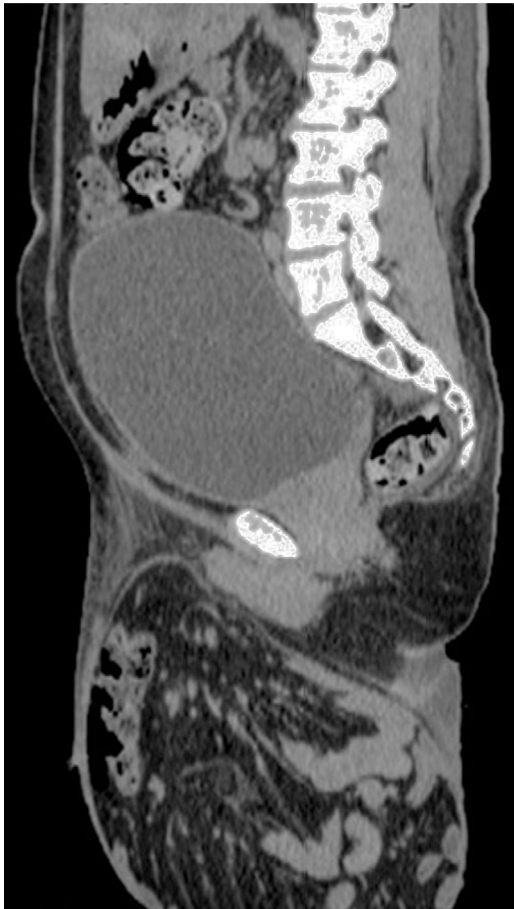

Figure 3 Sagittal view of abdominal tomographic image showing full bladder and small bowel segments in a giant extra-abdominal hernial sac.

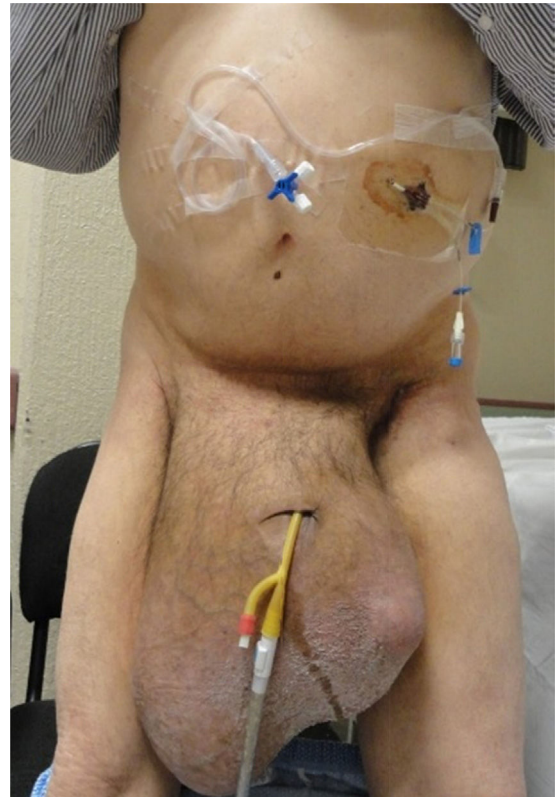


Figure 4 Patient in standing position with Foley catheter and Tenckhoff catheter placed in the left upper quadrant with a Veress needle used to insufflate the abdominal cavity.

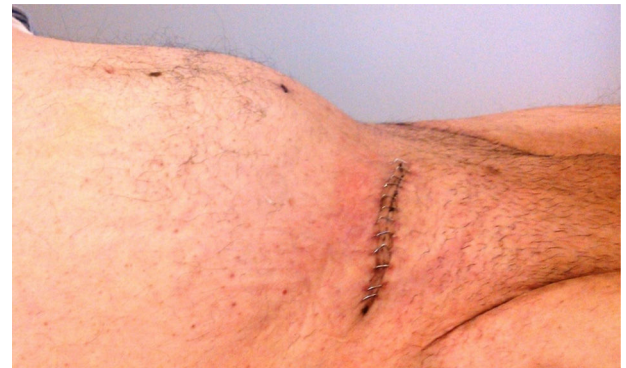

Figure 5 Scar from right inguinal incision 8 cm in length in the patient with previous inguinoscrotal hernia.

Ethical responsibilities

Protection of persons and animals. The authors declare that the procedures followed conformed to the ethical standards of the responsible committee on human experimentation and were in accordance with the World Medical Association and the Declaration of Helsinki.

Data confidentiality. The authors declare that no patient data appear in this article.

Right to privacy and informed consent. The authors declare that no patient data appear in this article.

Financial disclosure

No financial support was received in relation to this study.

Conflict of interest

The authors declare that there is no conflict of interest.

References

1. Vasiliadis K, Knaebel HP, Djakovic N, et al. Challenging surgical management of a giant inguinoscrotal hernia: Report of a case. *Surg Today*. 2010;40:684–7.
2. Karthikeyan VS, Sistla SC, Ram D, et al. Giant inguinoscrotal hernia—report of a rare case with literature review. *Int Surg*. 2014;99:560–4.
3. Tarchouli M, Ratbi MB, Bouzroud M, et al. Giant inguinoscrotal hernia containing intestinal segments and urinary bladder successfully repaired by simple hernioplasty technique: A case report. *J Med Case Rep*. 2015;9:276–7.