




REVISTA DE GASTROENTEROLOGÍA DE MÉXICO

www.elsevier.es/rgmx



CLINICAL IMAGE IN GASTROENTEROLOGY

Radiation enteritis diagnosed through capsule endoscopy, an uncommon cause of iron-deficiency anemia[☆]



Enteritis por radiación diagnosticada por cápsula endoscópica, una causa infrecuente de anemia ferropénica

J.F. Juanmartiñena Fernández^{a,*}, A. Elosua-González^a, L. Casanova-Ortiz^a,
S. Pardo-González^b, B. Zabalza Ollo^c, I. Fernández-Urién^a

^a Department of Gastroenterology, Complejo Hospitalario de Navarra, Pamplona, Navarra, Spain

^b Department of Anesthesiology and Resuscitation, Hospital Universitario Marqués de Valdecilla, Santander, Cantabria, Spain

^c Department of Clinical Analyses, Complejo Hospitalario de Navarra, Pamplona, Navarra, Spain

A 66-year-old woman was operated on in 1988 for an endometrial adenocarcinoma, after which she received adjuvant radiotherapy. The patient presented with 6-month, progressive iron-deficiency anemia. A complete endoscopic study (esophago-gastrosco-duodenoscopy and ileocolonoscopy) was performed; mucosal edema with superficial whitish spots in the terminal ileum (fig. 1A) was observed. Nonspecific chronic inflammation was reported in the histology study. To evaluate extension and small bowel involvement, a video capsule endoscopy was indicated. Diffuse and continuous involvement of the mucosa from the proximal jejunum to the terminal ileum was detected. The mucosal lesions ranged from mild edema with preservation

of the villous architecture in proximal segments (fig. 1B) to the presence of multiple ulcers that distorted and strictured the intestinal lumen (fig. 1C) in distal segments; the device could pass with no problems (fig. 1D). These findings were suggestive of post-radiation enteritis. Radiation enteritis is a phenomenon that appears in some patients that undergo abdominal radiotherapy. It can be acute or chronic, depending on the appearance of symptoms after treatment completion, among which the most frequent are nausea, vomiting, diarrhea, abdominal bloating, or gastrointestinal bleeding. Capsule endoscopy can be useful in these cases, and the Agile[®] Patency dissolvable capsule should be employed if there is suspicion or knowledge of bowel stricture.

[☆] Please cite this article as: Juanmartiñena Fernández JF, Elosua-González A, Casanova-Ortiz L, Pardo-González S, Zabalza Ollo B, Fernández-Urién I. Enteritis por radiación diagnosticada por cápsula endoscópica, una causa infrecuente de anemia ferropénica. Revista de Gastroenterología de México. 2017;82:339–340.

* Corresponding author. Departamento de Gastroenterología, Complejo Hospitalario de Navarra, C/ Irunlarrea 3, 31008 Pamplona, Navarra, Spain. Tel.: (+34) 658426309.

E-mail address: jf.juanmartinena@gmail.com
(J.F. Juanmartiñena Fernández).

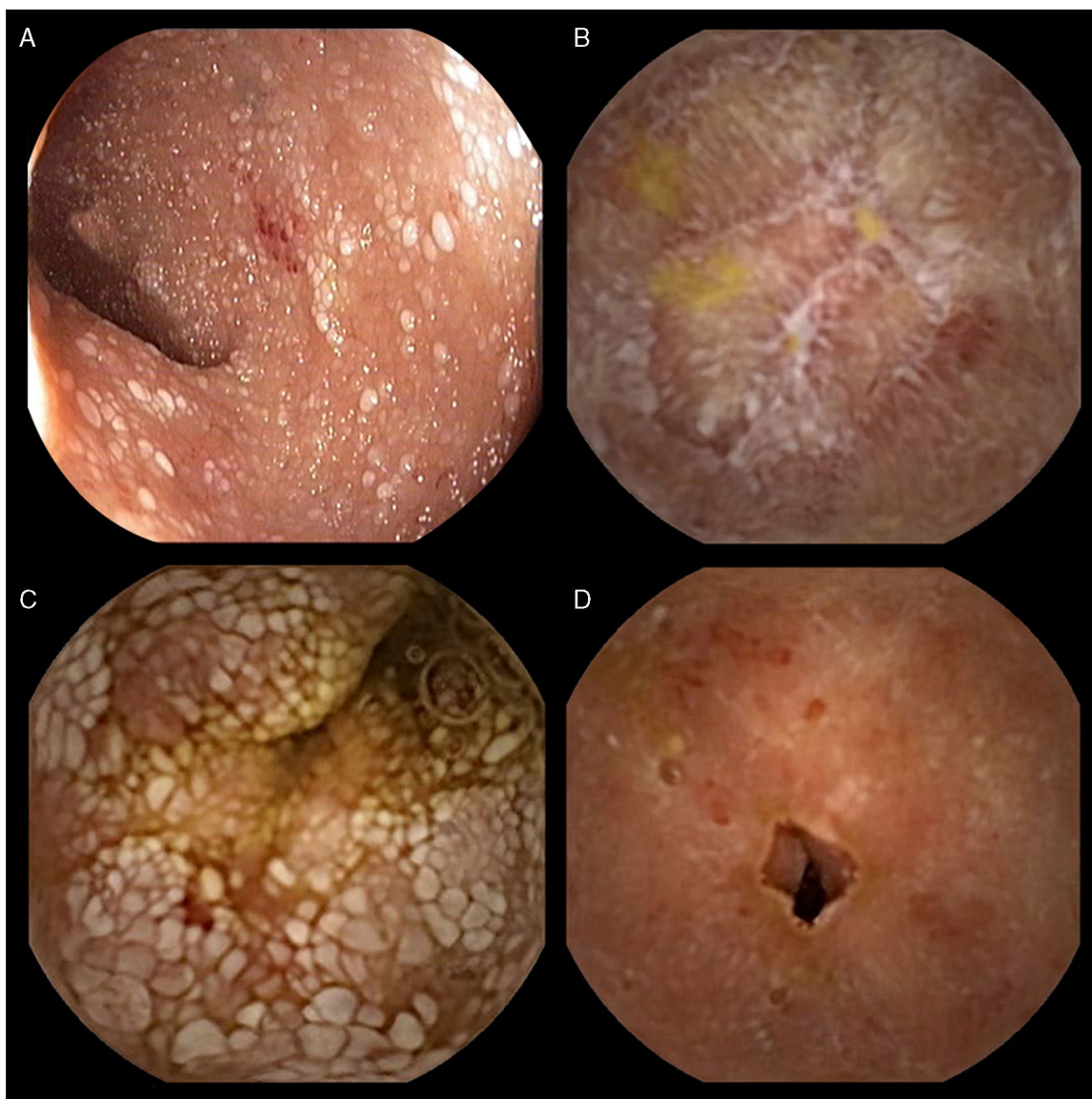


Figure 1 A) Mucosal edema of the terminal ileum with superficial whitish spots and nonspecific chronic inflammation in the histology report. B) The presence of multiple ulcers that distorted and strictured the intestinal lumen. C) Distal segments through which the device passed with no difficulty. (D) Post-radiation enteritis is shown.

Ethical disclosures

Protection of human and animal subjects. The authors declare that no experiments were performed on humans or animals for this study.

Confidentiality of data. The authors declare that no patient data appear in this article.

Right to privacy and informed consent. The authors declare that no patient data appear in this article.

Financial disclosure

No financial support was received in relation to this article.

Conflict of interest

The authors declare that there is no conflict of interest.