

7. Akintoye E, Kumar N, Obaitan, et al. Peroral endoscopic myotomy: A meta-analysis. *Endoscopy*. 2016;48:1059–68.
8. Geyl S, Legros R, Charissou A, et al. Peroral endoscopic pyloromyotomy accelerates gastric emptying in healthy pigs: proof of concept. *JT Endosc Int Open*. 2016;4:E796–9.
9. Khashab MA, Ngamruengphong S, Carr-locke D, et al. Gastric per-oral endoscopic myotomy for refractory gastroparesis: Results from the first multicenter study on endoscopic pyloromyotomy (with video). *Gastrointest Endosc*. 2017;85:123–8.
10. Gonzalez JM, Lestelle V, Benezech A, et al. Gastric per-oral endoscopic myotomy with antropyloromyotomy in the treatment of refractory gastroparesis: Clinical experience with follow-up and scintigraphic evaluation (with video). *Gastrointest Endosc*. 2016;85:1–8.
11. Revicki DA, Rentz AM, Dubois D, et al. Gastroparesis Cardinal Symptom Index (GCSI): Development and validation of a patient reported assessment of severity of gastroparesis symptoms. *Qual Life Res*. 2004;13:833–44.

O.V. Hernández-Mondragón^{a,*}, O.M. Solórzano-Pineda^b,
J.M. Blancas-Valencia^a, M.A. González-Martínez^a,
R.M. Villanueva-Pérez^c

^a Department of Endoscopy, Hospital de Especialidades Centro Médico Nacional Siglo XXI, Instituto Mexicano del Seguro Social, Mexico City, Mexico

^b Department of Gastrointestinal Endoscopy, Hospital de Especialidades Centro Médico Nacional Siglo XXI, Instituto Mexicano del Seguro Social, Mexico City, Mexico

^c Department of Nuclear Medicine, Centro Médico Nacional Siglo XXI, Instituto Mexicano del Seguro Social, Mexico City, Mexico

* Corresponding author. Departamento de Endoscopia del Hospital de Especialidades Centro Médico Nacional Siglo XXI, Avenida Cuauhtémoc 330, Col. Doctores, 06720 Mexico City, Mexico. Telephone: +56276900, extension 21317, 21318.

E-mail address: mondragonmd@yahoo.co.uk

(O.V. Hernández-Mondragón).

2255-534X/

© 2017 Asociación Mexicana de Gastroenterología. Published by Masson Doyma México S.A. This is an open access article under the CC BY-NC-ND license (<http://creativecommons.org/licenses/by-nc-nd/4.0/>).

Perianal basal cell carcinoma: An infrequent location[☆]



Carcinoma basocelular perianal: una localización infrecuente

Basal cell carcinoma (BCC) is the most frequent malignant neoplasia of the skin and makes up 75% of the non-melanocytic tumors.¹ It more commonly presents in the male sex (80% of the patients) and the mean presentation age varies from 65-75 years.² BCC frequently appears in areas exposed to ultraviolet radiation, mainly the head and neck. Its appearance at non-sun-exposed areas is atypical, and among those sites, location at the perianal region is extremely rare (0.1%), representing 0.2% of perianal tumors.³ Immunodeficiencies, infections, burns, chronic irritations, or previous radiation have been other etiopathogenic factors related to the appearance of this neoplasia. Likewise, certain hereditary syndromes, such as basal cell nevus syndrome or xeroderma pigmentosum, have also been implicated in its development.^{1,3}

We present herein an unusual case of BCC located at the perianal level, with no predisposing factors.

A 78-year-old woman with an unremarkable past medical history sought medical attention for a perianal lesion of 2-year progressive growth, associated with pruritus and occasional bleeding. Physical examination revealed a well-defined, ulcerated, erythematous neof ormation, 3 cm in

diameter, at the left anal margin (fig. 1A). Nodular BCC diagnosis was made from the biopsy (fig. 1B). Rectosigmoidoscopy was performed, ruling out anal canal involvement. A pelvic magnetic resonance (MR) study identified no evidence of infiltration into the sphincteric musculature. The lesion was locally excised and repaired through primary cutaneous closure (figs. C and D). The histopathologic study reported microscopic infiltration of the internal margin and re-intervention was carried out to widen the resection. Biopsy after reoperation confirmed tumor-free surgical margins. The patient had clinical follow-up and there are currently no signs of local recurrence at postoperative month 6.

BCC presents as a cutaneous lesion with erythematous papules, nodules, and ulcerations.⁴ Gibson and Ahmed⁵ described an ulcerous presentation of those tumors in up to 29.4% of patients. They also classified BCC into the following subtypes: nodular (66%), superficial (18%), infiltrative (8%), micronodular (4%), basosquamous (2%), and as fibroepithelioma of Pinkus (2%). A lesion with those characteristics should be biopsied to confirm the diagnosis and rule out other perianal diseases, such as Crohn's disease, squamous cell carcinoma, adenocarcinoma, melanoma, neuroendocrine tumors, gastrointestinal stromal tumors, verrucous carcinoma, Kaposi sarcoma, or Paget disease.^{4,6} The differential diagnosis should include entities of infectious origin, such as sexually transmitted diseases, or less common dermatoses, including candidiasis, tuberculosis granuloma, fungal infections, and amoebiasis.⁶ It is particularly important to differentiate BCC from cloacogenic carcinoma, which is an aggressive, invasive tumor.¹ Rectosigmoidoscopy and magnetic resonance imaging are the recommended complementary studies to rule out infiltration into the anal canal or sphincteric musculature invasion.

The current therapeutic options for BCC are exeresis, Mohs micrographic surgery, electrodesiccation and

[☆] Please cite this article as: Fernández-Martínez D, Rodríguez-Infante A, Sanz-Navarro S, Miguel-Ruiz C, Baldonado-Cernuda RF. Carcinoma basocelular perianal: una localización infrecuente. *Revista de Gastroenterología de México*. 2018;83:461–463.

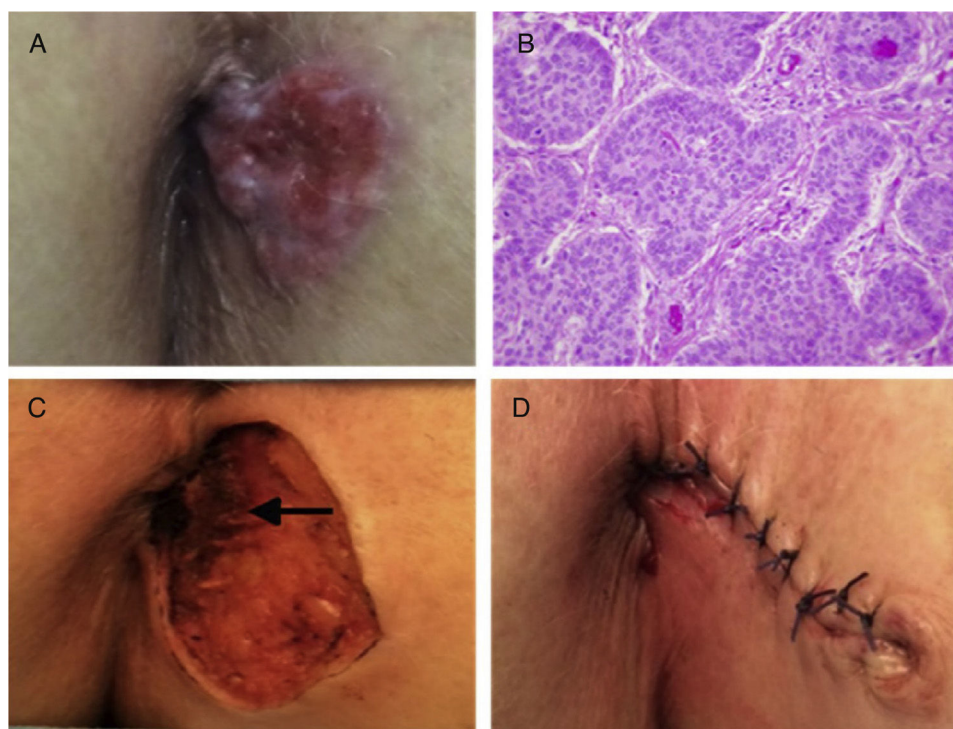


Figure 1 A) Perianal erythematous papular lesion with pearly nodules and superficial ulceration. B) Histopathologic study: Basaloid cell nests with peripheral palisading on top of subepidermal loose connective tissue, consistent with nodular basal cell carcinoma (H&E x40). C) Detail of the surgical site after resection, showing the absence of infiltration into the sphincteric musculature (arrow). D) Aspect of the operating area after surgical reconstruction.

curettage, cryosurgery, radiation, or photodynamic therapy with aminolevulinic acid.⁷ Nonsurgical treatment includes the use of immune response modifiers, such as imiquimod.⁸ Radiotherapy is the treatment of choice for lesions \geq T2, elderly patients, or patients with relevant comorbidities.^{3,4} Standard treatment is local wide resection, but abdominoperineal resection may be necessary as rescue therapy or first-line treatment in patients with invasion proximal to the dentate line or the anal sphincter.^{3,9} Mohs micrographic surgery is generally used in patients with large lesions, recurrent tumors, or with lesions in esthetically exposed areas, such as the face. However, surgical excision is generally preferred over Mohs micrographic surgery, given that the latter requires specialized training and has a longer operating time and higher costs.⁷ The recurrence rate after standard exeresis with wide oncologic margins varies from 0-29%.³ The lapse of time from tumor appearance, tumor size above 2 cm, or lesions with an infiltrative, micronodular, or morpheaform microscopic appearance are among the factors with a higher risk for recurrence.⁷ Vismodegib has been described as an efficacious therapeutic option in patients with locally advanced BCC or those with metastasis.¹⁰ Recurrences tend to be local and are treated with a new surgical resection or radiotherapy. BCC has a good prognosis, given that it is a slow-growing tumor with a low metastatic capacity.^{2,3} Five-year survival percentages of 100% have been reported in 2 large case series.^{2,5} The particularity of our case was the location of the pathology in a nonphotoexposed area and the absence of predisposing factors, emphasizing the fact that BCC should be included in

the differential diagnosis when there is a slow-progressing perianal lesion.

Conflict of interest

The authors declare that there is no conflict of interest.

References

1. Bulur I, Boyuk E, Saracoglu ZN, et al. Perianal Basal cell carcinoma. *Case Rep Dermatol.* 2015;7:25–8.
2. Paterson CA, Young-Fadok TM, Dozois RR. Basal cell carcinoma of the perianal region: 20-year experience. *Dis Colon Rectum.* 1999;42:1200–2.
3. Espino-Urbina LA, Espinosa-de-los-Monteros A, Domínguez-Cherit J, et al. Basal cell carcinoma of the perianal region: A case report and literature review. *Rev Gastroenterol Mex.* 2013;78:52–4.
4. Lee HS, Kim SK. Basal cell carcinoma presenting as a perianal ulcer and treated with radiotherapy. *Ann Dermatol.* 2015;27:212–4.
5. Gibson GE, Ahmed I. Perianal and genital basal cell carcinoma: A clinicopathologic review of 51 cases. *J Am Acad Dermatol.* 2001;45:68–71.
6. Rivera-Chavarría JP, Vargas-Villalobos F, Riggioni-Viquez S. Bilateral V-Y flap for a perianal basal cell carcinoma: A case report. *Int J Case Rep.* 2016;24:153–5.
7. Park J, Cho YS, Song KH, et al. Basal cell carcinoma on the pubic area: Report of a case and review of 19 Korean cases of BCC from non-sun-exposed areas. *Ann Dermatol.* 2011;23:405–8.

8. Rubin AI, Chen EH, Ratner D. Basal-cell carcinoma. *N Engl J Med.* 2005;353:2262–9.
9. Leonard D, Beddy D, Dozois EJ. Neoplasms of anal canal and perianal skin. *Clin Colon Rectal Surg.* 2011;24:54–63.
10. Sekulic A, Migden MR, Oro AE, et al. Efficacy and safety of vismodegib in advanced basal-cell carcinoma. *N Engl J Med.* 2012;366:2171–9.

D. Fernández-Martínez^{a,*}, A. Rodríguez-Infante^b,
S. Sanz-Navarro^a, C. Miguel-Ruiz^c,
R.F. Baldonado-Cernuda^a

^a *Servicio de Cirugía General y del Aparato Digestivo, Hospital Universitario Central de Asturias, Oviedo, Asturias, Spain*

^b *Servicio de Cirugía General y del Aparato Digestivo, Hospital Universitario San Agustín, Avilés, Asturias, Spain*
^c *Servicio de Anatomía Patológica, Hospital Universitario Central de Asturias, Oviedo, Asturias, Spain*

* Corresponding author at: Sección de Coloproctología, Servicio de Cirugía General y del Aparato Digestivo, Hospital Universitario Central de Asturias, Avda. de Roma s/n, 33011 Oviedo, Spain. Tel.: +0034 985 108 724.

E-mail address: cibea06@hotmail.com
(D. Fernández-Martínez).

2255-534X/

© 2017 Asociación Mexicana de Gastroenterología. Published by Masson Doyma México S.A. This is an open access article under the CC BY-NC-ND license (<http://creativecommons.org/licenses/by-nc-nd/4.0/>).

Primary mesothelial cyst of the spleen as an uncommon cause of dyspepsia: A case report[☆]



Quiste mesotelial primario esplénico como causa infrecuente de dispepsia: a propósito de un caso

Cysts of the spleen are an unusual pathology in daily clinical and surgical practice, with fewer than 1,000 cases reported in the literature. The majority of patients are asymptomatic, and diagnosis is usually based on imaging techniques. Surgical indication and treatment are a challenge for surgeons. We present herein the case of a patient with a primary cyst of the spleen as an infrequent cause of dyspepsia.

A 21-year-old woman with an unremarkable past history presented with clinical symptoms of early satiety, postprandial fullness, left epigastrium-hypochondrium pain upon eating, and a 3-kg weight loss. Physical examination revealed pain upon deep palpation of the left hemiabdomen. Abdominal ultrasound identified a 7-cm splenic lesion that was isoechoic, with little acoustic enhancement, and well-defined contours. Hemogram and biochemical tests were unaltered, hemagglutination-hydatidosis was negative, and the Ca 19.9 and carcinoembryonic antigen (CEA) markers were normal. The evaluation was completed through CT that showed an oval-shaped lesion with well-defined contours in the spleen. Its diameters measured 80 x 72 x 68 mm and there were no internal enhancements or solid poles. The stomach was displaced, but there were no signs suggestive of malignancy. Primary cyst of the spleen was suspected, and laparoscopic

fenestration was performed with no complications. The intraoperative cytology results were acellular serous diathesis and the histology study reported simple, flat epithelial lining that was positive for pankeratin (AE1-AE3) and calretinin and negative for CEA and Ca 19.9 (fig. 1A-D).

The symptoms of the patient improved and she gained 6 kg that she has maintained throughout her progression. The ultrasound study at 6 months after the intervention and the CT scan at one year showed a small cystic remnant and postoperative changes that did not affect the neighboring structures. The size of the remnant did not increase between the time the 2 imaging studies were carried out (fig. 2 A and B).

Cysts of the spleen are rare. The Mediterranean countries are endemic zones¹ where the *Echinococcus granulosus* parasites predominate. Noninfectious cysts include the primary cysts, which are characterized by the epithelial lining, and the secondary cysts (pseudocysts), which are more frequent and generally have a posttraumatic origin.

Primary cyst incidence is only 0.07%² and they are predominant in young women. They are usually incidental findings but can cause clinical symptoms due to adjacent organ compression, as occurred in our patient through gastric compression.

The etiopathogenesis of this disease is unknown. There are several types of epithelial lining: positivity for CEA and Ca 19.9 in epithelial cysts and positivity for pankeratin (AE1-AE3) and calretinin in mesothelial cysts stand out.³

The dilemma is when and how to treat them. Treatment is accepted for symptomatic cysts and those > 5 cm, due to the risk for complications, such as rupture, bleeding, and infection.

There are high rates of recurrence and complications with percutaneous treatment (aspiration and treatment with alcohol),⁴ and it is reserved for inoperable patients. Surgical techniques include total or partial splenectomy, decapsulation (complete membrane extirpation) and fenestration (resection that puts the cavity of the cyst in contact with the peritoneum)⁵ and all can be performed laparoscopically. The current trend is toward spleen-sparing techniques to prevent immunosuppression and thrombocytosis.

[☆] Please cite this article as: Elosua González A, Nantes Castillejo O, Tarifa Castilla A, Llanos Chávarri MC. Quiste mesotelial primario esplénico como causa infrecuente de dispepsia: a propósito de un caso. *Revista de Gastroenterología de México.* 2018;83:463–465.