




REVISTA DE GASTROENTEROLOGÍA DE MÉXICO

www.elsevier.es/rgmx



SCIENTIFIC LETTERS

Fournier's gangrene caused by *Streptococcus anginosus*, a rare etiologic agent[☆]



Gangrena de Fournier por *Streptococcus anginosus*, un agente etiológico poco habitual

Fournier's gangrene is a necrotizing fasciitis of the genital area. It progresses rapidly and its etiology is polymicrobial. The bacteria, aerobic and anaerobic, act synergically, causing great tissue destruction, and *Escherichia coli* is the most frequently identified microbe.¹ We present herein a case of Fournier's gangrene due to *Streptococcus anginosus*, an exceptional microorganism in this pathology.

A 56-year-old man, a smoker and occasional drinker, had a past medical history of meningoencephalitis of probable herpetic origin. In 2006, he was seen at the internal medicine department for gastric and duodenal ulcers and secondary iron-deficiency anemia (normal colonoscopy in 2006). In relation to his present illness, he came to the emergency department for pain in the perianal and genital area and increased scrotal volume associated with fever of 38 °C. Upon physical examination, the patient was hemodynamically stable, afebrile, and he had scrotal and perianal necrotic plaque in a horseshoe formation, with scrotal and penile edema and cellulitis that extended to the hypogastrium. The laboratory work-up results were leukocytosis (23,600 mm³) with left shift and C-reactive protein (CRP) of 38. An abdominopelvic computed axial tomography scan showed an increase in soft tissue in the anal region related to an infectious inflammatory process, with a great quantity of air in the right ischioanal fossa and root of the corpora cavernosa that extended into the perianal soft tissue and both sides of the scrotal sac, as well as into the subcutaneous cellular tissue in the area of the right gluteus and anterior abdominal wall at the level of the hypogastrium. He also presented with diffuse edema of the subcutaneous cellular tissue of the anterior, posterior, and left lateral abdominal wall. The patient was diagnosed with severe sepsis secondary to Fournier's gangrene. His fluid and electrolyte balance was restored and broad-spectrum antibiotic therapy was begun. Emergency

surgery was performed via perineal access and right iliac fossa (RIF) incision. During the procedure, abscess-cellulitis and necrosis at the level of both ischioanal fossae were found that extended to the testes and penis, causing ample plaques of cutaneous and soft tissue necrosis, also extending to both sides of the groin and to the pubis with fetid, subcutaneous necrosis. The perianal involvement separated the anterior rectal surface that presented with fat necrosis. The external genitalia were edematous, with necrotic plaques on both testes. Cellulitis was present in the proximal ends of the lower limbs, abdomen, and abdominal flanks, and reached the umbilical region. Ample cutaneous and subcutaneous debridement of the entire affected area was performed, a silastic drain was placed in the suprapubic region, and diverting loop colostomy in the left iliac fossa (LII) was carried out to isolate the perineum and enable better control of the septic focus at that level (figs. 1 and 2).

The patient was postoperatively admitted to the intensive care unit, continuing the restoration of fluid and electrolyte balance and hemodynamic support with vasopressors. He had good diuretic response and adequate peripheral perfusion. The antibiotics daptomycin, metronidazole, and imipenem were empirically administered to eradicate the polymicrobial flora and there was good control of the signs of sepsis. Multisensitive *Streptococcus anginosus* (an uncommon microbe in this pathology) was isolated from the wound exudate. Antibiotic treatment was adjusted (the antibiogram showed sensitivity to cefotaxime, ceftriaxone, clindamycin, vancomycin, erythromycin, and penicillin), completing the 12-day treatment cycle with imipenem as monotherapy. The patient had good respiratory progression, with a gradual decrease in respiratory support, and was extubated after 9 days of mechanical ventilation.

Once the patient had adequate sepsis control and his wounds were properly cleaned and debrided and had negative cultures, partially thick skin grafts were applied in a joint intervention with the plastic surgery department. The remainder of the postoperative period was unremarkable, and the patient was released from the hospital 41 days after his admission.

Fournier's gangrene is an infrequent pathology that has a 10:1 predominance in males.²

Patients with alcoholism, diabetes, malnutrition, or neoplasias are more highly predisposed to develop this pathology and its entryway tends to be a mild wound at the genital level. Symptoms also frequently develop from anal abscesses or fistulas, bowel perforations (of any etiology),

[☆] Please cite this article as: Soto-Sánchez A, Hernández-Barroso M, Hernández-Hernández G, Gamba-Michel L, Barrera-Gómez M. Gangrena de Fournier por *Streptococcus anginosus*, un agente etiológico poco habitual. Revista de Gastroenterología de México. 2018;83:348–350.

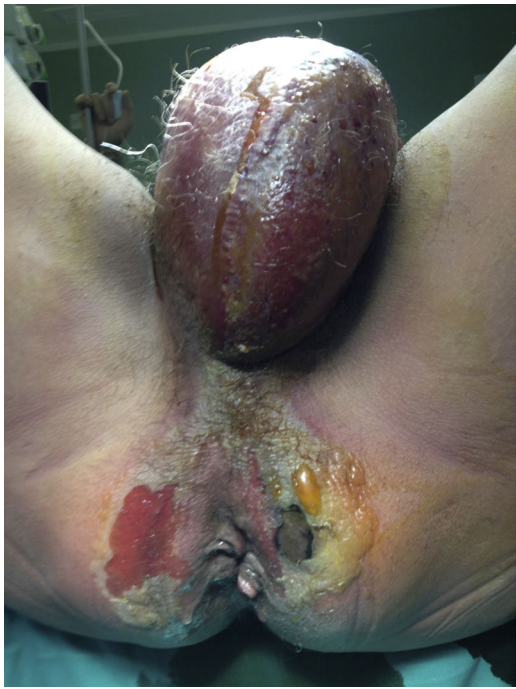

Figure 1 Preoperative image. Cellulitis and necrotic plaques at the level of the two ischioanal fossae, extending to the perineum and testes.

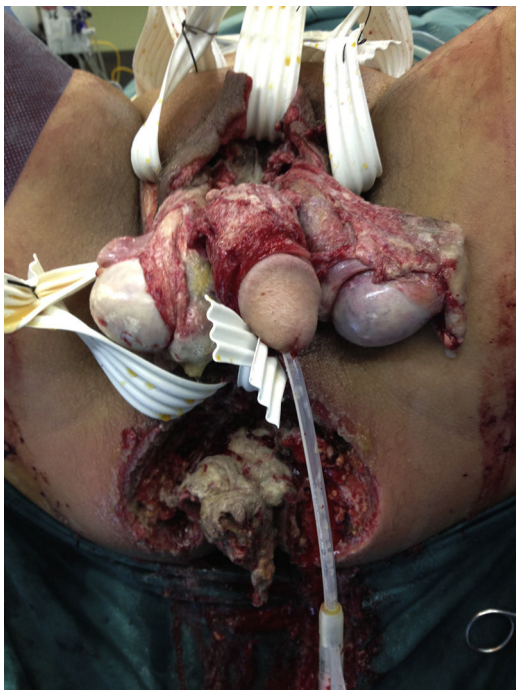


Figure 2 Postoperative image after ample debridement and placement of a silastic drain.

or hidradenitis. Prognosis is worse when the focus is anal or rectal.³

Surgical treatment in cases of Fournier's gangrene should be early and aggressive and reconstruction is dependent on the degree of tissue destruction. In severe cases, it is done

through free skin grafts, and musculocutaneous grafts are used to cover deep defects.⁴

Etiology is polymicrobial. In the majority of patients, multiple aerobic and anaerobic microorganisms that often act synergically are isolated. According to a study by Cohen MS, the most frequently isolated aerobic pathogens are Gram-negative (*E. coli*, 47%), and Bacteroides (44%) are the most frequently isolated anaerobic pathogens. *Streptococcus anginosus* was the microorganism isolated in our case.^{5,6}

The anginosus group streptococci are catalase-negative Gram-positive cocci in chains that belong to the genus *Streptococcus*.

Streptococcus anginosus forms part of the resident flora of the oronasopharynx, gingival sulci, gastrointestinal tract, and vagina and it can migrate from those sites and cause different pyogenic infections. Its role in severe pyogenic infections is recognized, unlike the rest of the microbes in the viridans streptococci group, but varies in accordance with different clinical symptoms. Its presentation as a causal agent of Fournier's gangrene is exceptional.⁷

Ethical disclosures

Protection of human and animal subjects. The authors declare that no experiments were performed on humans or animals for this study.

Confidentiality of data. The authors declare that they have followed the protocols of their work center on the publication of patient data.

Right to privacy and informed consent. The authors declare that no patient data appear in this article.

Conflict of interest

The authors declare that there is no conflict of interest.

References

1. Rudolph R, Soloway M, DePalma RG, et al. Fournier's syndrome: Synergistic gangrene of the scrotum. *Am J Surg.* 1975;129: 591-6.
2. Altarac S, Katusin D, Crnica S, et al. Fournier's gangrene: Etiology and outcome analysis of 41 patients. *Urol Int.* 2012;88: 289-93.
3. Vyas HG, Kumar A, Bhandari V, et al. Prospective evaluation of risk factors for mortality in patients of Fournier's gangrene: A single center experience. *Indian J Urol.* 2013;29: 161-5.
4. García-Marín A, Turégano-Fuentes F, Cuadrado-Ayuso M, et al. Predictive factors for mortality in Fournier' gangrene: A series of 59 cases. *Cir Esp.* 2015;93:12-7.
5. Broyles LN, van Beneden C, Beall B, et al. Population-based study of invasive disease due to β -hemolytic streptococci of groups other than A and B. *Clin Infect Dis.* 2009;48: 706-12.
6. Cohen MS. Gangrena de Fournier. *Casos prácticos de urología.* 1997;5:101-14.

7. Whiley RA, Beighton D. Emended descriptions and recognition of *Streptococcus constellatus*, *Streptococcus intermedius*, and *Streptococcus anginosus* as distinct species. *Int J Syst Bacteriol.* 1991;41:1-5.

A. Soto-Sánchez*, M. Hernández-Barroso,
G. Hernández-Hernández, L. Gamba-Michel,
M. Barrera-Gómez

*Servicio de Cirugía General y del Aparato Digestivo,
Hospital Universitario Nuestra Señora de Candelaria, Santa
Cruz de Tenerife, Tenerife, Spain*

*Corresponding author. Servicio de Cirugía General y del Aparato Digestivo, Hospital Universitario Nuestra Señora de Candelaria, Carretera del Rosario 145, 38010 Santa Cruz de Tenerife, Tenerife, Spain. Tel.: +639826675.

E-mail address: sotosanchezana@hotmail.com
(A. Soto-Sánchez).

2255-534X/

© 2017 Asociación Mexicana de Gastroenterología. Published by Masson Doyma México S.A. This is an open access article under the CC BY-NC-ND license (<http://creativecommons.org/licenses/by-nc-nd/4.0/>).

Upper gastrointestinal bleeding secondary to vigorous physical exercise[☆]



Hemorragia digestiva alta secundaria a ejercicio físico intenso

The appearance of digestive symptoms in athletes is relatively frequent, and according to published case series, varies from 30-81%. Gastroesophageal reflux, nausea, vomiting, diarrhea, or transitory abdominal pain linked to exercise are the most frequent manifestations. Since the 1980s, numerous observational studies have shown that intense exercise can cause iron-deficiency anemia due to the appearance of gastritis, gastroduodenal ulcers, or erosions in the small bowel and colon. Depending on the degree of exercise, 7 to 85% of athletes can present with a positive fecal occult blood test upon finishing their training. Marked gastrointestinal bleeding is much less frequent and only anecdotal cases are found in the literature.^{1,2} The first and only death due to gastrointestinal bleeding in a jogger was reported in 1982.³

A 30-year-old man with an unremarkable personal and family history came to the emergency department complaining of 3 bowel movements consistent with melena within the past 24h. He stated that he had not taken any drug or gastrotoxic agent, no nutritional supplement, and no tobacco, alcohol, or other toxic substance. When asked about his usual physical activity, the patient said he rode a bicycle 4-5 times a week for approximately 45 min. When questioned about his activity in the morning before coming to the emergency department, he stated that 6h before presenting with melena he had finished a 5-h bicycle ride at a much greater speed than usual. Physical examination revealed a heart rate of 105 bpm and the rest of his vital signs were normal. The laboratory work-up showed urea of 56 mg/dl (normal: 15-45 mg/dl) and hemoglobin of 12.7 g/dl (normal: 13-17.5g/dl). The remaining results were normal. An emergency upper gastrointestinal endoscopy was

performed that identified 10 linear ulcers in the gastric body of approximately 10-15mm in length and 2 mm in width, following the direction of the gastric folds. The ulcers had irregular edges and were covered with hematin (Forrest IIc) and fibrin (Forrest III) (fig. 1). Two biopsies were taken from the antrum, two from the gastric body, and one from each of the two largest ulcers. The patient remained under surveillance for 24h, presented with no other episodes of melena, and was released under treatment with omeprazole 20 mg/12 h for 8 weeks. The results of the gastric biopsies were negative for *H. pylori* and there were no foci of dysplasia or metaplasia. Only some alterations consistent with the base of an ulcer and a mild, nonspecific, acute inflammatory infiltrate were documented. Upper gastrointestinal endoscopy was repeated at 12 weeks, confirming the endoscopic and histologic cure of the lesions. During follow-up, two 13C-labelled urea tests were carried out (with no previous PPI or antibiotic ingestion) to detect *H. pylori*, and were negative. The laboratory work-up was extended to include PTH and gastrin determination, and both were normal. Abdominal ultrasound had no significant findings. One year after the initial episode the patient is asymptomatic.

In 2001, Choi et al. conducted one of the most demonstrative studies, despite its small sample size,

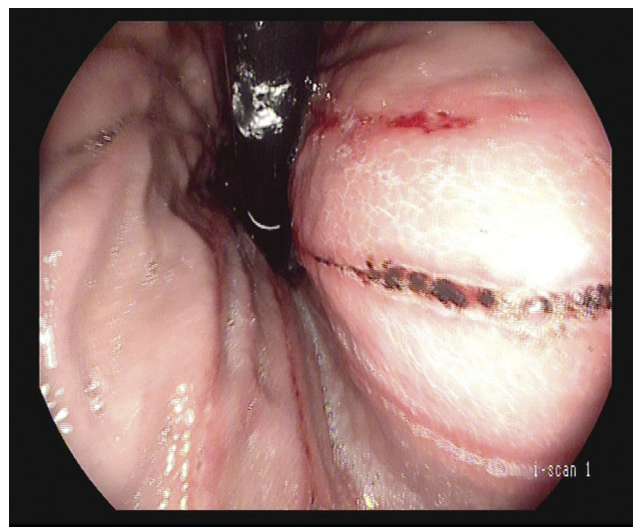


Figure 1 Retroflexed view of linear ulcers with hematin on their surface, Forrest IIc.

[☆] Please cite this article as: Rodríguez de Santiago E, Aguilera Castro L, García García de Paredes A, Ferre Aracil C, Martín de Argila de Prados C. Hemorragia digestiva alta secundaria a ejercicio físico intenso. *Revista de Gastroenterología de México.* 2018;83:350-351.