

Financial disclosure

No financial support was received in relation to this study/article.

Conflict of interest

The authors declare that there is no conflict of interest.

References

1. Armiñanzas C, Gutiérrez-Cuadra M, Fariñas MC. Hydatidosis: Epidemiological, clinical, diagnostic and therapeutic aspects. *Rev Esp Quimioter.* 2015;28:116–24.
2. Ingle SB, Hinge Ingle CR, Patrike S. Epithelial cysts of the spleen: A mini review. *World J Gastroenterol.* 2014;20:13899–903.
3. Palmieri I, Natale E, Crafa F, et al. Epithelial splenic cysts. *Anti-cancer Res.* 2005;25:515–21.
4. Amr AE. Splenic cysts, many questions are yet to be answered: a case report. *Cases J.* 2009;2:8474.

5. Chin EH, Shapiro R, Hazzan D, et al. A ten-year experience with laparoscopic treatment of splenic cysts. *JSL.* 2007;11:20–3.

A. Elosua González^{a,*}, O. Nantes Castillejo^a,
A. Tarifa Castilla^b, M.C. Llanos Chávarri^c

^a *Digestive tract Service, Complejo Hospitalario de Navarra, Pamplona, Spain*

^b *General Surgery Service, Complejo Hospitalario de Navarra, Pamplona, Spain*

^c *Pathologic Anatomy Service, Complejo Hospitalario de Navarra, Pamplona, Spain*

*Corresponding author. Servicio de Aparato Digestivo, Complejo Hospitalario de Navarra, C/ Irunlarrea, Núm. 3, 31008 Pamplona, Navarra, Spain. Tel.: +34848422114.

E-mail address: alfonso.elosua@gmail.com

(A. Elosua González).

2255-534X/

© 2018 Published by Masson Doyma México S.A. on behalf of Asociación Mexicana de Gastroenterología. This is an open access article under the CC BY-NC-ND license (<http://creativecommons.org/licenses/by-nc-nd/4.0/>).

Radiation-induced leiomyosarcoma of the rectum after cervical cancer treatment[☆]



Leiomiosarcoma de recto radio inducido posterior a tratamiento de cáncer cérvico uterino

Over the last few decades, multidisciplinary treatment of cancer patients has improved survival rates and the disease-free periods. However, the number of tumors associated with treatment, particularly radiotherapy, has also increased.¹

That association has been made from the cases of persons that survived the nuclear disasters of Japan and Chernobyl. Its justification is based on the concept of oncogenesis due to radiation, established by Cahan et al. in 1948,² and those criteria are still valid. Their only controversial point is the time necessary for cancer to be associated with radiotherapy. The original criteria stated 5 years, but it has currently been shown that the period can be shorter, with the appearance of radiation-induced tumors from 6 months to 20 years after treatment completion.³

It is known that the development of these tumors is the result of the interaction of many etiologic factors. The role of mutations has been studied in animal models, especially that of p53, the main form of which is the deletion of

that gene (52% of mutations) in radiation-induced sarcomas, compared with sporadic sarcomas (less than 10%). However, this is not yet conclusive in humans.^{4,5} The p53 mutations, as well as genetic alterations due to genomic instability, are the most widely studied. Their mechanisms include abnormal intracellular signaling, cytokine production, the creation of free radicals, and the secondary triggering of an inflammatory response.⁶

A 58-year-old woman had a past medical history of clinical stage IIB (FIGO) cervical cancer (squamous cell carcinoma), treated with chemotherapy (CT) based on 4 cycles of cisplatin and concomitant radiotherapy (RT) of 50 Gy to the pelvis and brachytherapy (BT) of 35 Gy. She had complete response and was kept under surveillance. Eight years later, with no apparent recurrence, the patient presented with rectal tenesmus associated with rectal bleeding. Physical examination revealed an ulcerated exophytic tumor 3 cm from the anal margin that occluded 50% of the lumen, with no apparent involvement of the rectovaginal septum. Rectosigmoidoscopy identified the tumor at 6 cm from the anal margin, occluding up to 70% of the lumen. Biopsy revealed mesenchymal neoplasia with the following immunoprofile: positive actin, negative CD34, CD117, DOG1, PS100, CKAE1/AE3, and P16. The diagnosis was high-grade leiomyosarcoma. Nuclear magnetic resonance (NMR) imaging corroborated the dependence on the rectal wall, as well as the involvement of the muscles of the perineum and the fat of both buttocks in the anal region (fig. 1). The rest of the extension studies were negative for distant disease. The multidisciplinary team began treating the patient with induction CT (doxorubicin and gemcitabine), after performing a sigmoid loop diversion colostomy. Response to the third CT cycle was partial and total pelvic exenteration with vulvectomy was indicated. Intraoperative findings were a tumor in the perineal region involving the gluteus maximus and levator ani muscles,

[☆] Please cite this article as: Garcia-Ortega DY, Reyes-Garcia N, Martínez-Said H, Caro-Sánchez CHS, Cuellar-Hubbe M. Leiomiosarcoma de recto radio inducido posterior a tratamiento de cáncer cérvico uterino. *Revista de Gastroenterología de México.* 2018;83:465–467.

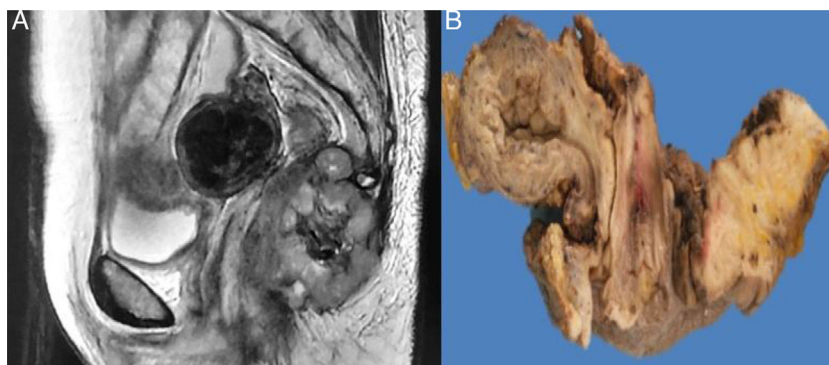


Figure 1 Abdominopelvic NMR image. A) Neof ormation dependent on the lower rectum, extending to the anal region and involving the muscles of the perineum and both buttocks. B) Sagittal slice of the surgical specimen.

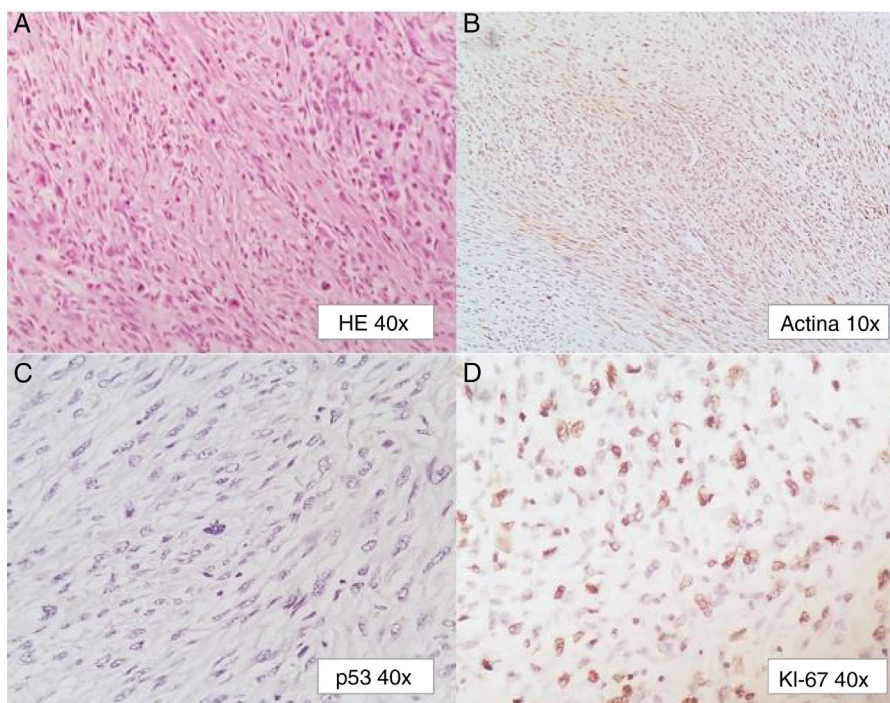


Figure 2 Photomicrographs: A) H&E x40. B) Actin x10. C) p53 x40. D) Ki-67 x40.

with no separating plane of the uterus and bladder. Urinary reconstruction through ileal conduit and diversion colostomy was performed. The patient had adequate progression with no complications. Surgical specimen examination corroborated the differentiation to high-grade smooth muscle tumor. It measured 7 x 4 x 3 cm, compromising the perineal edge up to the rectovaginal septum and infiltrating the anal sphincter muscles and skin. There was also lymphovascular and perineural invasion. The surgical margins were free from neoplasia and the immunohistochemistry pattern was similar to the previous one, adding positive P53 and Ki67 in 1% and 90% of the neoplastic cells, respectively (fig. 2).

Primary leiomyosarcomas of the rectum make up less than 0.1% of colorectal tumors. Not more than 290 cases are reported in the literature and there is still no solid association between rectal leiomyosarcoma and pelvic radiation.⁷

Due to their rareness, leiomyosarcomas, and radiation-induced sarcomas in general, are difficult to diagnose. They are more aggressive than non-radiation-induced sarcomas and are usually identified at advanced stages. Radiation-induced sarcomas are generally high-grade, thus having poor outcome. The rareness of the tumor and its broad presentation spectrum make high clinical suspicion necessary. Recurrence of the primary tumor with sarcomatoid morphology must be ruled out. This was corroborated in our patient due to the absence of immunohistochemical markers, such as p16 and CKAE1/AE3. Interestingly, despite the fact that there is a relatively frequent marked expression of p53, which is associated with a p53 mutation and worse outcome, its presence is not indispensable for this type of neoplasia. Surgery is the treatment of choice that offers the best oncologic results in these cases. It is also

the only viable form of treatment, given that a very low response to systemic treatment, as well as the impossibility of reirradiation has been described.^{1,8}

Financial disclosure

No financial support was received in relation to this study/article.

Conflict of interest

The authors declare that there is no conflict of interest.

References

- Walton A, Broadbent AL. Radiation-induced second malignancies. *J Palliat Med.* 2008;11:1345–52.
- Cahan WG, Woodward HQ, Higinbotham NL, et al. Sarcoma arising in irradiated bone: report of eleven cases. *Cancer.* 1948;1:3–29.
- Mahmood S, Vu K, Tai P, et al. Radiation-induced second malignancies. *Anticancer Res.* 2015;35:2431–4.
- Travis LB. Therapy-associated solid tumors. *Acta Oncol.* 2002;41:323–33.
- Gonin-Laurent N, Gibaud A, Huyghe M, et al. Specific TP53 mutation pattern in radiation-induced sarcomas. *Carcinogenesis.* 2006;27:1266–72.
- Lorimore Sally A, Philip Coates J, Wright EG. Radiation-induced genomic instability and bystander effects: Inter-related non-targeted effects of exposure to ionizing radiation. *Oncogene.* 2003;22:7058–69.
- Basu I, Lemonas P. Leiomyosarcoma of the rectum following pelvic irradiation: A difficult histological diagnosis. *Ann R Coll Surg Engl.* 2011;94:e44–5.
- Hall EJ, Wu CS. Radiation-induced second cancers: The impact of 3D-CRT and IMRT. *Int J Radiat Oncol Biol Phys.* 2003; 56:83–8.

D.Y. Garcia-Ortega^{a,*}, N. Reyes-Garcia^b, H. Martinez-Said^a, C.H.S. Caro-Sanchez^a, M. Cuellar-Hubbe^a

^a *Departamento de Piel y Partes Blandas, Instituto Nacional de Cancerología, Mexico City, Mexico*

^b *Instituto Nacional de Cancerología, Mexico City, Mexico*

* Corresponding author. Avenida San Fernando #22, Colonia sección XVI, C.P. 14080, Mexico City, Mexico. Phones: +56280400 / 56554766.

E-mail address: dr_doriangarcia@me.com

(D.Y. Garcia-Ortega).

2255-534X/

© 2018 Asociación Mexicana de Gastroenterología. Published by Masson Doyma México S.A. This is an open access article under the CC BY-NC-ND license (<http://creativecommons.org/licenses/by-nc-nd/4.0/>).

Chronic diarrhea: A case of Waldenström Macroglobulinemia[☆]



Diarrea crónica: un caso de macroglobulinemia de Waldenström

Waldenström macroglobulinemia (WM), or lymphoplasmacytic lymphoma, is a type of slow-growing non-Hodgkin's lymphoma with an annual incidence of 3 cases per 1 million.¹ Its presentation is varied, given its systemic involvement and chronic course. The 5-year survival rate, once treatment is begun, is 87% in low-risk patients, 68% in intermediate-risk patients, and 36% in high-risk patients.²

Gastrointestinal involvement is infrequent, at less than 5%. Seventy-two years ago, Waldenström first described 3 cases, one of which presented with intense abdominal pain and bloating.³ Later reports included symptoms of pseudo-obstruction, protein-losing enteropathy associated with duodenal lymphangiectasia, severe malnutrition, and important impact on the quality of life of those patients,⁴ digestive tract bleeding due to hyperviscosity or infiltration, hepatosplenic thrombosis associated with hypercoagulability, and symptoms of bowel perforation during

treatment.^{5,6} Most cases of hemolytic anemia in WM are associated with cold antibodies, with a prevalence of 1.1%.⁷

A 49-year-old woman with symptoms of 1-year progression initially presented with normocytic anemia with documented indirect hyperbilirubinemia, elevated LDH, and positive Coombs test for IgM, IgG, and C3d, suggestive of mixed antibody autoimmune hemolytic anemia. She was managed with prednisolone and azathioprine and her response was adequate at the follow-up at 2 months. The patient later sought medical attention at other hospitals due to intermittent diarrhea with characteristics of malabsorption, which worsened 2 months prior to hospital admission, and was associated with a 12-kg weight loss. A new hemogram showed high volumes of leukopenia and anemia, with a MCV of 108 fL. Tests reported noninflammatory diarrhea, severe hypoalbuminemia of 1.6 g/dL, and prolonged coagulation times. Studies were performed considering neoplasia in the differential diagnosis of an autoimmune disorder. Antinuclear antibodies, beta-2 microglobulin, and anticardiolipin antibodies were negative, there was complement consumption, and the lupus anticoagulant was positive.

Because of the macrocytosis, vitamin B12 and folic acid studies were carried out, with normal results. There was a decrease in iron. Active hemolysis was no longer present and the extended blood test showed the rouleaux formation phenomenon.

Tomography scans of the chest and abdomen revealed no masses, but identified diffuse thickening of the intestinal segments, especially at the level of the duodenum.

[☆] Please cite this article as: Amado Garzón SB, Villanueva Ortega MM, Botero Bahamón JD. Diarrea crónica: un caso de macroglobulinemia de Waldenström. *Revista de Gastroenterología de México.* 2018;83:467–469.