



REVISTA DE GASTROENTEROLOGÍA DE MÉXICO

www.elsevier.es/rgmx



CLINICAL IMAGE IN GASTROENTEROLOGY

10-hour asymptomatic endoscopic capsule broncoaspiration[☆]



Broncoaspiración asintomática de cápsula endoscópica por 10 horas

D. Keil-Ríos*, D. Angulo-Molina, A. Farca-Belsaguy

Unidad Avanzada de Endoscopia, Centro Médico ABC, Campus Observatorio, Mexico City, Mexico

An 84-year-old man sought medical attention due to fever and ileal wall thickening, for which capsule endoscopy was performed. Capsule administration and exam were uneventful. The patient stated he had no discomfort but did not expel the capsule through a bowel movement (figs. 1 a and b). Hours later, he began to cough and 10 hours after the procedure he spontaneously expectorated the video capsule (figs. 1c and d). The images were reviewed, confirming the aspiration of the capsule when it was administered. A new video capsule was endoscopically placed in the duodenum, with no further complications.

Capsule endoscopy aspiration is a rare complication. The largest case series conducted on the topic reports a frequency of 0.003%, occurring mainly in elderly, fragile patients with swallowing disorders. In general, respiratory symptoms present immediately. There are few reports of cases of asymptomatic aspiration of the capsule endoscopy camera and only one report in which the duration was longer than the 10 h in our case.

[☆] Please cite this article as: Keil-Ríos D, Angulo-Molina D, Farca-Belsaguy A. Broncoaspiración asintomática de cápsula endoscópica por 10 horas. *Revista de Gastroenterología de México*. 2018;83:451–452.

* Corresponding author. Sur 136 no. 116 consultorio 2A, Colonia Las Américas, Mexico City, C.P. 01120. Phone/Fax: +52724919. E-mail address: danielkeil@gmail.com (D. Keil-Ríos).

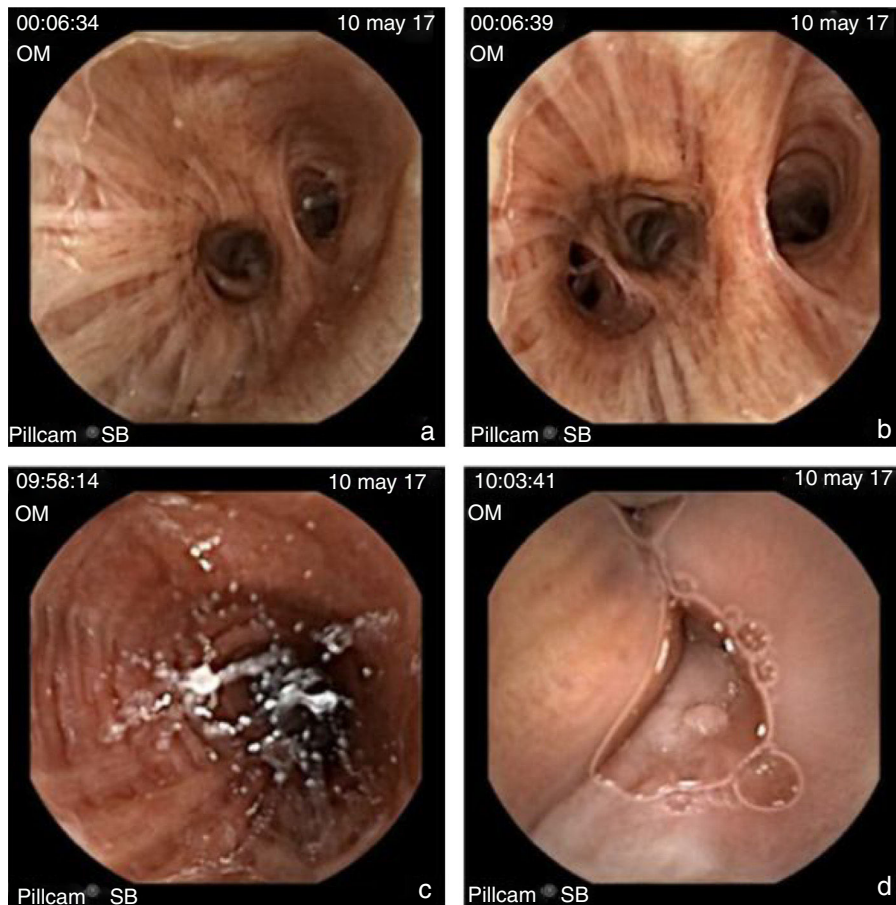


Figure 1 Secondary bronchi at the time of capsule administration (a and b). Bronchus during expectoration of the capsule (c). Hypopharynx during capsule expectoration (d).

Ethical disclosures

Protection of human and animal subjects.

The authors declare that the procedures followed were in accordance with the regulations of the relevant clinical research ethics committee and with those of the Code of Ethics of the World Medical Association (Declaration of Helsinki).

Confidentiality of data.

The authors declare that no patient data appear in this article.

Right to privacy and informed consent.

The authors declare that no patient data appear in this article.

Financial disclosure

No financial support was received in relation to this article.

Conflict of interest

The authors declare that there is no conflict of interest.