

## Hirschsprung's disease as a rare cause of refractory constipation in an adult patient<sup>☆</sup>



### Enfermedad de Hirschsprung como causa rara de estreñimiento refractario en un paciente adulto

A 27-year-old woman with an unremarkable past medical history was referred to us for an anorectal manometry study due to clinical symptoms characterized by chronic constipation since infancy that did not respond to treatments with laxatives or enemas. Symptoms had worsened in recent months, prompting her to seek the evaluation of a proctologist.

Physical examination revealed a mildly distended abdomen and no other relevant alterations. No abnormalities resulted from the rectal examination.

General laboratory tests were performed (complete blood count, blood chemistry, and TSH) and the results were within the normal ranges.

A barium enema study identified megarectum (fig. 1).

The anorectal manometry study revealed an anal canal with normal length, baseline and phasic canal pressures within normal values, adequate rectal sensitivity and capacity, the Valsalva maneuver with no escape, inhibitory rectoanal reflex absent up to the maximum tolerable rectal capacity (120 cc), and positive balloon expulsion maneuver. The results were consistent with Hirschsprung's disease (fig. 2).

A full-thickness biopsy was taken from the wall of the rectum, with the following findings: absence of mature and immature ganglion cells in the submucosal plexus of the wall of the rectum and a marked reduction of interstitial cells of Cajal in the muscle wall.

Auerbach's myenteric plexus was not identified. Immunohistochemistry with: S-100 protein (detection of neuronal cells): positive in the plexuses.

Chromogranin (detection of neuroendocrine cells): negative.

Calretinin (detection of ganglion cells): negative.

Bcl-2 (detection of enteric neurons): negative.

CD117 (detection of interstitial cells of Cajal): positive in interstitial cells of Cajal that were reduced in number.

Wall of the rectum with aganglionosis consistent with Hirschsprung's disease (fig. 3).

Hirschsprung's disease was described in 1886, with the report of 20 cases of congenital megacolon in children. It was later related to the absence of ganglion cells. Surgical treatment for the disease was described in 1948.<sup>1</sup>

It is a rare condition that affects 1:5,000 births.

Based on the length of the affected segment, it is classified as: short-segment (not extending beyond the sigmoid

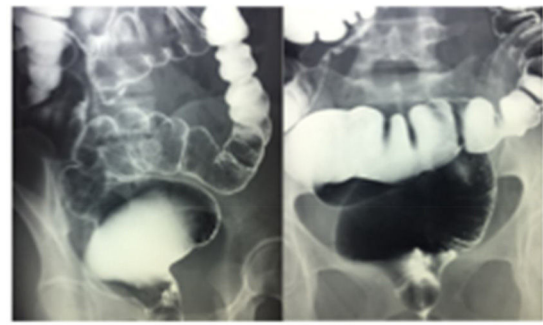


Figure 1 Barium enema showing megarectum.

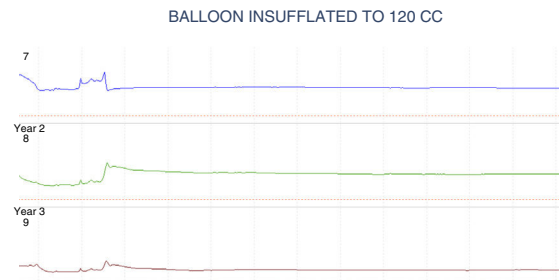


Figure 2 Conventional anorectal manometry trace showing the absence of the inhibitory rectoanal reflex with the maximum tolerable rectal capacity.

colon), which is the most frequent presentation (80%); Ultra-short or juxta-anal segment (patients with that presentation are considered to have more probability of reaching adulthood undiagnosed), and long-segment when it is proximal to the sigmoid colon.<sup>2</sup>

It is a rare disease in adulthood, but its diagnosis should be considered in cases of constipation that is refractory to conventional medical therapy.<sup>3</sup>

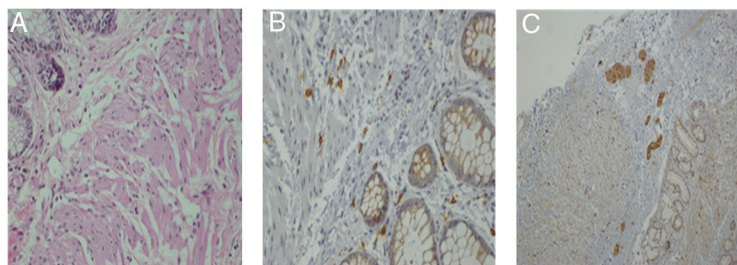
The disease predominates in females in patients above 10 years of age with a ratio of 3:1. However, aganglionosis of the short-segment pathology is more frequent in males, with a mean age of 20 years at the time of medical consultation. It can cause symptoms of severe chronic constipation or frequent episodes of fecal impaction.<sup>4</sup>

Diagnosis is based on the combination of anorectal physiology studies (sensitivity 91%, specificity 94%) and the characteristic finding is absence of the inhibitory rectoanal reflex. Baritaded imaging studies (sensitivity 70%, specificity 83%) can identify the so-called «transition zone» and inversion of the rectosigmoid index. It should be emphasized that the aganglionic segment is strictured. Full-thickness biopsies of the wall of the rectum are considered the gold standard (100% sensitivity and specificity), in which the absence of ganglion cells in the submucosa and the myenteric plexus is pathognomonic.<sup>5</sup>

The treatment of choice is surgical and aganglionic segment resection and anastomosis of the healthy colonic segment to the anal canal can be performed laparoscopically.<sup>6</sup>

In adults, the treatment of choice is the Duhamel operation, which results in reduced fecal impaction after the procedure.<sup>3</sup>

<sup>☆</sup> Please cite this article as: Alcocer-Sánchez E, Pérez y López N, Fernández-Álvarez J, Zárate-Osorno A. Enfermedad de Hirschsprung como causa rara de estreñimiento refractario en un paciente adulto. Revista de Gastroenterología de México. 2019;84:253-254.



**Figure 3** Biopsies of the rectum. A. H-E stain x100 in which no ganglion cells are observed. B. IHC x100 with CD117 showing a reduced number of interstitial cells of Cajal. C. IHC x100 positive for S100 in the nerve plexuses.

There are few reports on this disease in stages after infancy in the national and international literature.<sup>1,3-6</sup>

It is important to consider the presence of this rare pathologic process in young adult patients with treatment-refractory chronic constipation, in whom other more common diseases have been ruled out through easily accessed studies, such as imaging or anorectal physiology studies.

### Financial disclosure

No financial support was received in relation to this study/article.

### Conflict of interest

The authors declare that there is no conflict of interest.

### References

1. Prieto E, Medina JL, Casillas R, et al. Enfermedad de Hirschsprung: un caso de constipación en el adulto. *Cirujano General*. 2008;30:231-3.
2. De Manueles J, de la Rubia L. Enfermedad de Hirschsprung. *Rev Col Gastroenterol*. 2016;31:47-54.
3. Burlando E, Bernhardt R, Barraud C, et al. Enfermedad de Hirschsprung del adulto. Corrección quirúrgica. *Rev Argent Resid Cir*. 2009;13:79-81.

4. Fortea C, Martínez D, Rivadulla I, et al. Hirschsprung's disease in adults. *Rev Esp Enferm Dig*. 2001;3:150-1.
5. Icaza M, Takahashi Monroy T, Uribe Uribe N, et al. Enfermedad de Hirschsprung en el adulto. *Rev Gastroenterol Mex*. 2000;65:171-4.
6. Lombana J. Surgery in adult Hirschsprung's disease. *Rev Col Gastroenterol*. 2007;22:231-7.

E. Alcocer-Sánchez<sup>a</sup>, N. Pérez y López<sup>b,\*</sup>, J. Fernández-Álvarez<sup>c</sup>, A. Zárate-Osorno<sup>d</sup>

<sup>a</sup> *Coloproctology Service, Hospital Español de México, Mexico City, Mexico*

<sup>b</sup> *Motility Laboratory, Gastroenterology Service, Hospital Juárez de México, Mexico City, Mexico*

<sup>c</sup> *General Surgery Service, Hospital Español de México, Mexico City, Mexico*

<sup>d</sup> *Pathology service, Hospital Español de México, Mexico City, Mexico*

\* Corresponding author. Av. Ejército Nacional 617-402. Col. Granada. Del. Miguel Hidalgo. Mexico City, Mexico. CP 11520. Tel.: +52504827 / 5520670809.

E-mail address: [sonelle74@hotmail.com](mailto:sonelle74@hotmail.com) (N. Pérez y López). 2255-534X/

© 2018 Published by Masson Doyma México S.A. on behalf of Asociación Mexicana de Gastroenterología. This is an open access article under the CC BY-NC-ND license (<http://creativecommons.org/licenses/by-nc-nd/4.0/>).

## Primary lymphoma of the appendix: A case report and review of the literature<sup>☆</sup>



### Linfoma primario de apéndice: reporte de un caso y revisión de la literatura

Primary lymphoma of the appendix is an extremely rare entity that accounts for approximately 0.015% of the lym-

phomas of the gastrointestinal tract. There are very few published reports of the pathology. Burkitt's lymphoma is more frequent in children, whereas the majority of cases in adults correspond to large B-cell non-Hodgkin lymphoma.<sup>1-4</sup>

The majority of articles found in the international literature correspond to case reports. In the case series by Marcelo Zamorano et al., from a total of 7626 appendectomy specimens, there were only 25 appendiceal tumors and just 2 of them were primary lymphomas.<sup>5</sup> In another case series that included 5307 appendectomy specimens, Daniel Esmer et al. found a total of 31 cases (0.58%) of appendiceal tumor, none of which corresponded to appendiceal lymphoma.<sup>4</sup> A total of 1060 appendectomy specimens were reviewed over a 10-year period at the Kamineni Hospitals in India and only one case of appendiceal lymphoma was found,<sup>1</sup> illustrating the rareness of the pathology.

<sup>☆</sup> Please cite this article as: García-Norzagaray JC, Villalobos-López JA, Flores-Nájera H, Valle Leal JG, García Torres CD. Linfoma primario de apéndice: reporte de un caso y revisión de la literatura. *Revista de Gastroenterología de México*. 2019;84:254-257.