

8. Rubin AI, Chen EH, Ratner D. Basal-cell carcinoma. *N Engl J Med.* 2005;353:2262–9.
9. Leonard D, Beddy D, Dozois EJ. Neoplasms of anal canal and perianal skin. *Clin Colon Rectal Surg.* 2011;24:54–63.
10. Sekulic A, Migden MR, Oro AE, et al. Efficacy and safety of vismodegib in advanced basal-cell carcinoma. *N Engl J Med.* 2012;366:2171–9.

D. Fernández-Martínez^{a,*}, A. Rodríguez-Infante^b,
S. Sanz-Navarro^a, C. Miguel-Ruiz^c,
R.F. Baldonado-Cernuda^a

^a Servicio de Cirugía General y del Aparato Digestivo,
Hospital Universitario Central de Asturias, Oviedo,
Asturias, Spain

^b Servicio de Cirugía General y del Aparato Digestivo,
Hospital Universitario San Agustín, Avilés, Asturias, Spain
^c Servicio de Anatomía Patológica, Hospital Universitario
Central de Asturias, Oviedo, Asturias, Spain

* Corresponding author at: Sección de Coloproctología, Ser-
vicio de Cirugía General y del Aparato Digestivo, Hospital
Universitario Central de Asturias, Avda. de Roma s/n, 33011
Oviedo, Spain. Tel.: +0034 985 108 724.

E-mail address: cibea06@hotmail.com
(D. Fernández-Martínez).

2255-534X/

© 2017 Asociación Mexicana de Gastroenterología. Published by
Masson Doyma México S.A. This is an open access article under the
CC BY-NC-ND license (<http://creativecommons.org/licenses/by-nc-nd/4.0/>).

Primary mesothelial cyst of the spleen as an uncommon cause of dyspepsia: A case report[☆]



Quiste mesotelial primario esplénico como causa infrecuente de dispepsia: a propósito de un caso

Cysts of the spleen are an unusual pathology in daily clinical and surgical practice, with fewer than 1,000 cases reported in the literature. The majority of patients are asymptomatic, and diagnosis is usually based on imaging techniques. Surgical indication and treatment are a challenge for surgeons. We present herein the case of a patient with a primary cyst of the spleen as an infrequent cause of dyspepsia.

A 21-year-old woman with an unremarkable past history presented with clinical symptoms of early satiety, postprandial fullness, left epigastrium-hypochondrium pain upon eating, and a 3-kg weight loss. Physical examination revealed pain upon deep palpation of the left hemiabdomen. Abdominal ultrasound identified a 7-cm splenic lesion that was isoechoic, with little acoustic enhancement, and well-defined contours. Hemogram and biochemical tests were unaltered, hemagglutination-hydatidosis was negative, and the Ca 19.9 and carcinoembryonic antigen (CEA) markers were normal. The evaluation was completed through CT that showed an oval-shaped lesion with well-defined contours in the spleen. Its diameters measured 80 x 72 x 68 mm and there were no internal enhancements or solid poles. The stomach was displaced, but there were no signs suggestive of malignancy. Primary cyst of the spleen was suspected, and laparoscopic

fenestration was performed with no complications. The intraoperative cytology results were acellular serous diathesis and the histology study reported simple, flat epithelial lining that was positive for pankeratin (AE1-AE3) and calretinin and negative for CEA and Ca 19.9 (fig. 1A-D).

The symptoms of the patient improved and she gained 6 kg that she has maintained throughout her progression. The ultrasound study at 6 months after the intervention and the CT scan at one year showed a small cystic remnant and postoperative changes that did not affect the neighboring structures. The size of the remnant did not increase between the time the 2 imaging studies were carried out (fig. 2 A and B).

Cysts of the spleen are rare. The Mediterranean countries are endemic zones¹ where the *Echinococcus granulosus* parasites predominate. Noninfectious cysts include the primary cysts, which are characterized by the epithelial lining, and the secondary cysts (pseudocysts), which are more frequent and generally have a posttraumatic origin.

Primary cyst incidence is only 0.07%² and they are predominant in young women. They are usually incidental findings but can cause clinical symptoms due to adjacent organ compression, as occurred in our patient through gastric compression.

The etiopathogenesis of this disease is unknown. There are several types of epithelial lining: positivity for CEA and Ca 19.9 in epithelial cysts and positivity for pankeratin (AE1-AE3) and calretinin in mesothelial cysts stand out.³

The dilemma is when and how to treat them. Treatment is accepted for symptomatic cysts and those > 5 cm, due to the risk for complications, such as rupture, bleeding, and infection.

There are high rates of recurrence and complications with percutaneous treatment (aspiration and treatment with alcohol),⁴ and it is reserved for inoperable patients. Surgical techniques include total or partial splenectomy, decapsulation (complete membrane extirpation) and fenestration (resection that puts the cavity of the cyst in contact with the peritoneum)⁵ and all can be performed laparoscopically. The current trend is toward spleen-sparing techniques to prevent immunosuppression and thrombocytosis.

[☆] Please cite this article as: Elosua González A, Nantes Castillejo O, Tarifa Castilla A, Llanos Chávarri MC. Quiste mesotelial primario esplénico como causa infrecuente de dispepsia: a propósito de un caso. *Revista de Gastroenterología de México.* 2018;83:463–465.

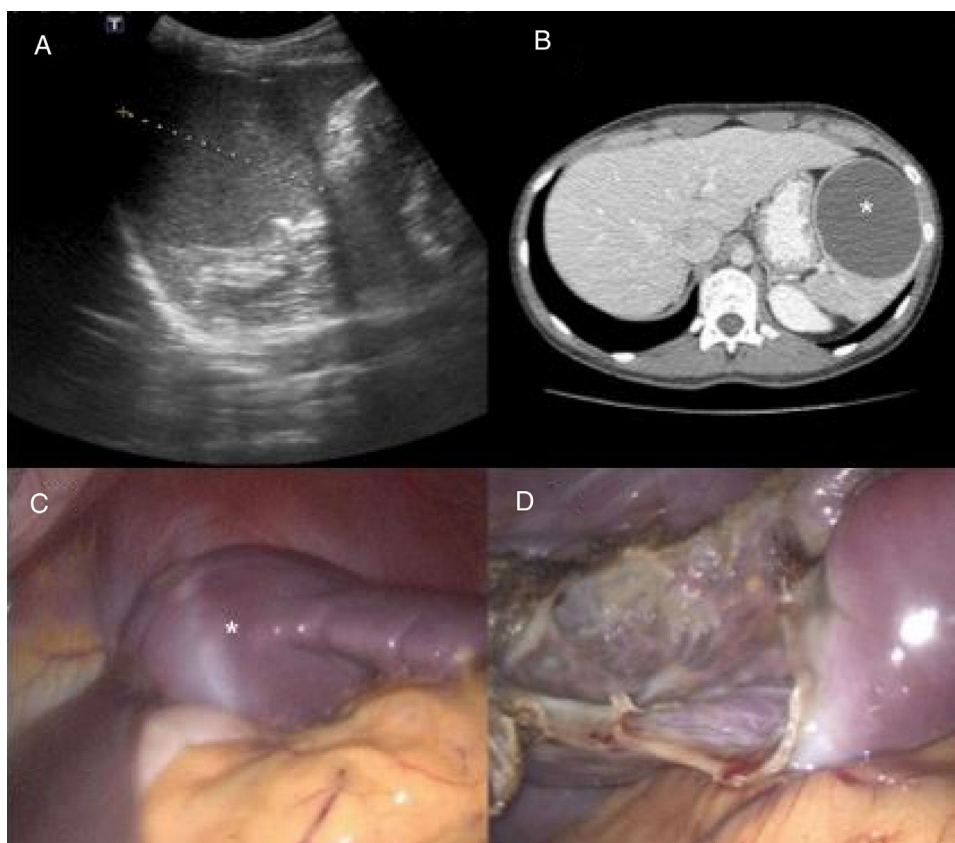


Figure 1 A) Preoperative abdominal ultrasound: splenic lesion measuring 7 cm in diameter with little acoustic enhancement and well-defined contours. B) Preoperative computed tomography scan: well-defined oval-shaped lesion consistent with a cyst of the spleen (asterisk). Note the displacement of the stomach. C) Laparoscopic intraoperative image: splenic cyst (asterisk) compressing the stomach before fenestration. D) Laparoscopic intraoperative image: remnant of the splenic parenchyma after fenestration.

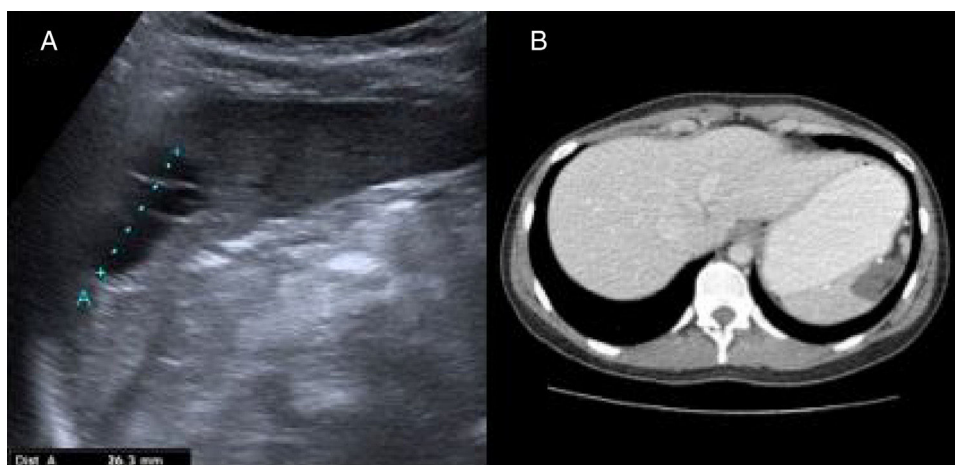


Figure 2 A) Postoperative abdominal ultrasound: a well-defined, anechoic, polylobulated lesion with echogenic internal septa in the interpolar region of the spleen, measuring 32 mm in diameter, consistent with a cystic remnant. B) Computed tomography scan: altered splenic contour with a 22 x 23 mm uniform hypodense lesion consistent with a postoperative cystic remnant.

Financial disclosure

No financial support was received in relation to this study/article.

Conflict of interest

The authors declare that there is no conflict of interest.

References

1. Armiñanzas C, Gutiérrez-Cuadra M, Fariñas MC. Hydatidosis: Epidemiological, clinical, diagnostic and therapeutic aspects. *Rev Esp Quimioter*. 2015;28:116–24.
2. Ingle SB, Hinge Ingle CR, Patrike S. Epithelial cysts of the spleen: A mini review. *World J Gastroenterol*. 2014;20:13899–903.
3. Palmieri I, Natale E, Crafa F, et al. Epithelial splenic cysts. *Anti-cancer Res*. 2005;25:515–21.
4. Amr AE. Splenic cysts, many questions are yet to be answered: a case report. *Cases J*. 2009;2:8474.
5. Chin EH, Shapiro R, Hazzan D, et al. A ten-year experience with laparoscopic treatment of splenic cysts. *JSL*. 2007;11:20–3.

A. Elosua González^{a,*}, O. Nantes Castillejo^a,
A. Tarifa Castilla^b, M.C. Llanos Chávarri^c

^a *Digestive tract Service, Complejo Hospitalario de Navarra, Pamplona, Spain*

^b *General Surgery Service, Complejo Hospitalario de Navarra, Pamplona, Spain*

^c *Pathologic Anatomy Service, Complejo Hospitalario de Navarra, Pamplona, Spain*

*Corresponding author. Servicio de Aparato Digestivo, Complejo Hospitalario de Navarra, C/ Irunlarrea, Núm. 3, 31008 Pamplona, Navarra, Spain. Tel.: +34848422114.

E-mail address: alfonso.elosua@gmail.com

(A. Elosua González).

2255-534X/

© 2018 Published by Masson Doyma México S.A. on behalf of Asociación Mexicana de Gastroenterología. This is an open access article under the CC BY-NC-ND license (<http://creativecommons.org/licenses/by-nc-nd/4.0/>).

Radiation-induced leiomyosarcoma of the rectum after cervical cancer treatment[☆]



Leiomiosarcoma de recto radio inducido posterior a tratamiento de cáncer cérvico uterino

Over the last few decades, multidisciplinary treatment of cancer patients has improved survival rates and the disease-free periods. However, the number of tumors associated with treatment, particularly radiotherapy, has also increased.¹

That association has been made from the cases of persons that survived the nuclear disasters of Japan and Chernobyl. Its justification is based on the concept of oncogenesis due to radiation, established by Cahan et al. in 1948,² and those criteria are still valid. Their only controversial point is the time necessary for cancer to be associated with radiotherapy. The original criteria stated 5 years, but it has currently been shown that the period can be shorter, with the appearance of radiation-induced tumors from 6 months to 20 years after treatment completion.³

It is known that the development of these tumors is the result of the interaction of many etiologic factors. The role of mutations has been studied in animal models, especially that of p53, the main form of which is the deletion of

that gene (52% of mutations) in radiation-induced sarcomas, compared with sporadic sarcomas (less than 10%). However, this is not yet conclusive in humans.^{4,5} The p53 mutations, as well as genetic alterations due to genomic instability, are the most widely studied. Their mechanisms include abnormal intracellular signaling, cytokine production, the creation of free radicals, and the secondary triggering of an inflammatory response.⁶

A 58-year-old woman had a past medical history of clinical stage IIB (FIGO) cervical cancer (squamous cell carcinoma), treated with chemotherapy (CT) based on 4 cycles of cisplatin and concomitant radiotherapy (RT) of 50 Gy to the pelvis and brachytherapy (BT) of 35 Gy. She had complete response and was kept under surveillance. Eight years later, with no apparent recurrence, the patient presented with rectal tenesmus associated with rectal bleeding. Physical examination revealed an ulcerated exophytic tumor 3 cm from the anal margin that occluded 50% of the lumen, with no apparent involvement of the rectovaginal septum. Rectosigmoidoscopy identified the tumor at 6 cm from the anal margin, occluding up to 70% of the lumen. Biopsy revealed mesenchymal neoplasia with the following immunoprofile: positive actin, negative CD34, CD117, DOG1, PS100, CKAE1/AE3, and P16. The diagnosis was high-grade leiomyosarcoma. Nuclear magnetic resonance (NMR) imaging corroborated the dependence on the rectal wall, as well as the involvement of the muscles of the perineum and the fat of both buttocks in the anal region (fig. 1). The rest of the extension studies were negative for distant disease. The multidisciplinary team began treating the patient with induction CT (doxorubicin and gemcitabine), after performing a sigmoid loop diversion colostomy. Response to the third CT cycle was partial and total pelvic exenteration with vulvectomy was indicated. Intraoperative findings were a tumor in the perineal region involving the gluteus maximus and levator ani muscles,

[☆] Please cite this article as: Garcia-Ortega DY, Reyes-Garcia N, Martínez-Said H, Caro-Sánchez CHS, Cuellar-Hubbe M. Leiomiosarcoma de recto radio inducido posterior a tratamiento de cáncer cérvico uterino. *Revista de Gastroenterología de México*. 2018;83:465–467.