

Ethical disclosures

Protection of human and animal subjects. The authors declare that no experiments were performed on humans or animals for this study.

Confidentiality of data. The authors declare that they have followed the protocols of their work center on the publication of patient data.

Right to privacy and informed consent. The authors declare that no patient data appear in this article.

Right to privacy and informed consent. The authors have obtained the written informed consent of the patients or subjects mentioned in the article. The corresponding author is in possession of this document.

Financial disclosure

No financial support was received in relation to this study/article.

Conflict of interest

The authors declare that there is no conflict of interest.

References

- Du Boulay CE, Fairbrother J, Isaacson PG. Mucosal prolapse syndrome—a unifying concept for solitary ulcer syndrome and related disorders. *J Clin Pathol.* 1983;36:1264–8.
- Alexander-Williams J. Solitary-ulcer syndrome of the rectum. Its association with occult rectal prolapse. *Lancet.* 1977;1:170–1.
- Womack NR, Williams NS, Holmfield JH, et al. Pressure and prolapse—the cause of solitary rectal ulceration. *Gut.* 1987;28:1228–33.
- Saul SH. Inflammatory cloacogenic polyp: Relationship to solitary rectal ulcer syndrome/mucosal prolapse and other bowel disorders. *Hum Pathol.* 1987;18:1120–5.
- Jabbari M, Cherry R, Lough JO, et al. Gastric antral vascular ectasia: The watermelon stomach. *Gastroenterology.* 1984;87:1165–70.
- Campbell AP, Cobb CA, Chapman RW, et al. Cap polyposis—an unusual cause of diarrhoea. *Gut.* 1993;34:562–4.
- Franzin G, Fratton A, Manfrini C. Polypoid lesions associated with diverticular disease of the sigmoid colon. *Gastrointest Endosc.* 1985;31:196–9.
- Kelly JK. Polypoid prolapsing mucosal folds in diverticular disease. *Am J Surg Pathol.* 1991;15:871–8.
- Oriuchi T, Kinouchi Y, Kimura M, et al. Successful treatment of cap polyposis by avoidance of intraluminal trauma: Clues to pathogenesis. *Am J Gastroenterol.* 2000;95:2095–8.
- Mathus Vliegen EM, Tytgat GN. Polyp-simulating mucosal prolapse syndrome in (pre-) diverticular disease. *Endoscopy.* 1986;18:84–6.
- Tendler DA, Aboudola S, Zacks JF, O'Brien MJ, Kelly CP. Prolapsing mucosal polyps: an underrecognized form of colonic polyp, a clinicopathological study of 15 cases. *Am J Gastroenterol.* 2002;97:370–6.

R. Monreal-Robles, J.A. González-González,
D.E. Benavides-Salgado*, H.J. Maldonado-Garza

*Servicio de Gastroenterología y Endoscopia Digestiva,
Hospital Universitario «Dr. José E. González», Universidad
Autónoma de Nuevo León, Monterrey, Nuevo León, Mexico*

*Corresponding author. Av. Madero y Gonzalitos s/n, Col. Mitras Centro, Monterrey, Nuevo León, Mexico, C.P. 64460, University Hospital, Universidad Autónoma de Nuevo León. Phone: +52 81 83 89 11 11.

E-mail address: Daniel-benavides@live.com

(D.E. Benavides-Salgado).

2255-534X/

© 2019 Asociación Mexicana de Gastroenterología. Published by Masson Doyma México S.A. This is an open access article under the CC BY-NC-ND license (<http://creativecommons.org/licenses/by-nc-nd/4.0/>).

Gastrointestinal mucormycosis: An atypical cause of abdominal pain in an immunocompromised patient[☆]



Mucormycosis gastrointestinal: causa atípica de dolor abdominal en un paciente inmunocomprometido

Abdominal pain in immunocompromised patients is a diagnostic and therapeutic challenge for clinicians because it

presents as a nonspecific manifestation due to the inability of the patient to mount an adequate immune response.

Immunocompromised patients are those that have chronic diseases managed through immunomodulators and that suffer from an alteration in the immune response that is innate or secondary to some other pathology. That group of patients includes persons that are advanced in age, that have diabetes mellitus, HIV infection, or neoplasia. It also includes transplanted patients and those that take medications that modify the immune response, such as steroids, anti-TNF alpha, methotrexate, cyclosporine, and tacrolimus, among others.¹ Myelosuppression is a major systemic toxicity generally associated with chemotherapy treatments. It considerably increases morbidity and mortality, as well as delays in oncologic treatment, thus altering overall survival in those patients.²

A 38-year-old woman diagnosed with acute myeloid leukemia sought medical attention at the emergency service due to painful abdominal syndrome. The patient was in

[☆] Please cite this article as: Clemente-Gutiérrez U, Perez-Soto RH, Álvarez-Bautista FE, Domínguez-Rosado I, Cuellar-Mendoza M. Mucormycosis gastrointestinal: causa atípica de dolor abdominal en un paciente inmunocomprometido. *Revista de Gastroenterología de México.* 2019;84:409–411.

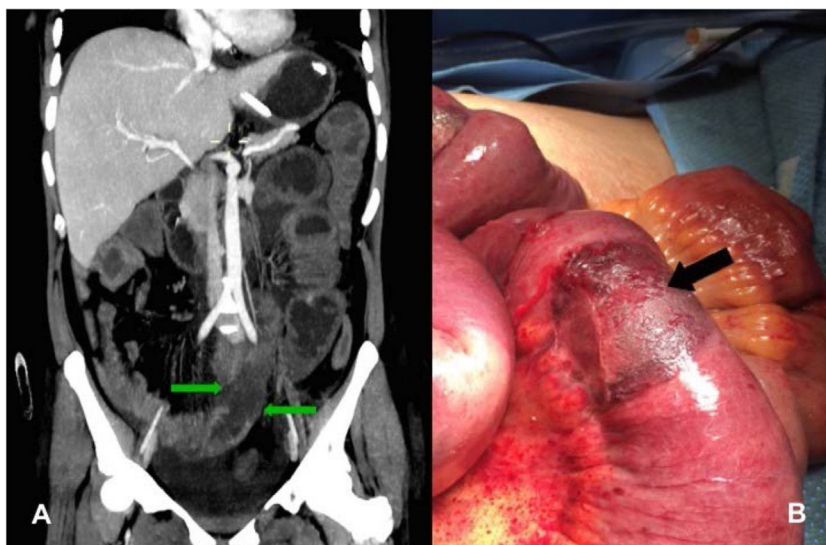


Figure 1 A) Computed tomography scan of the stomach showing segmental areas of hypoperfusion of the intestinal wall (green arrows). B) Intraoperative image with numerous well-limited, circumferential, ischemic zones in the small bowel (black arrow).

her first relapse since treatment with chemotherapy and had no previous surgical history. Upon her arrival at the emergency service, she presented with diffuse abdominal pain, nausea, vomiting, and fever. Physical examination revealed abdominal distension and amphoric bowel sounds, and intestinal occlusion was diagnosed. Laboratory study results reported leukocytes $0.6 \times 10^3/\text{mm}^3$ with 93.4% neutrophils ($560/\text{mm}^3$ total) and lactate concentration of 2.3 mmol/l. Treatment was begun with fasting and a nasogastric tube, but after 48 h the patient showed no clinical improvement. An intravenous contrast-enhanced abdominal tomography scan identified segmental areas of hypoperfusion in the wall of the small bowel (fig. 1A). The patient underwent exploratory laparotomy, revealing multiple circumferential lesions in the small bowel that appeared to be ischemic (fig. 1B). Intestinal resection and anastomosis were performed during the surgery. Figure 2 shows the

histopathologic findings consistent with mucosal ulceration and bleeding, as well as thick hyphae with focal bulbous dilation and branching at right angles, resulting in the diagnosis of intestinal mucormycosis. Oral diet was begun on the third postoperative day and the patient received antifungal treatment with amphotericin B for 6 weeks. She was released on day 50 of her hospitalization.

Abdominal pain is estimated to be the reason for emergency service visits in 40% of patients with cancer. The gastrointestinal signs and symptoms in those patients can be directly related to the oncologic diagnosis or be complications of treatment with chemotherapy or radiotherapy. Chemotherapy can cause abdominal pain, nausea, vomiting, or diarrhea, whereas radiation can cause progressive occlusive vasculitis or intestinal stricture.³

Among the group of cancer patients that develop severe neutropenia and fever, more than 80% have hematologic

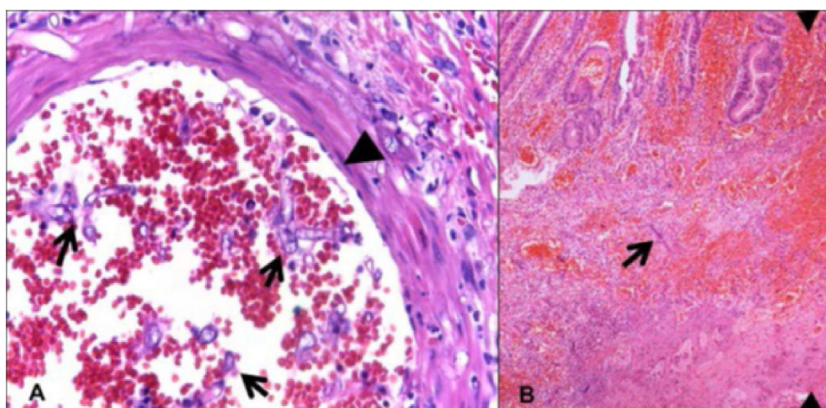


Figure 2 A) Histopathologic study of the intestinal mucosa showing ulceration and bleeding and thick hyphae with focal bulbous dilation and branching at right angles. B) Vascular invasion with bleeding, thrombosis, ischemic necrosis, and acute inflammatory infiltrate is also shown.

malignancies resulting from clinically documented infections or positive hemocultures, 80% of which are caused by endogenous microbiota.⁴ The differential diagnosis for abdominal pain in patients with severe neutropenia is broad and includes neutropenic enterocolitis, *Clostridium difficile* infection, diverticulitis, appendicitis, and cholecystitis, among the most common pathologies.⁵

Patients with acute myeloid leukemia and deep neutropenia have up to 20 times more risk for invasive mycosis, the diagnosis and treatment of which is complex.⁴ Mucormycosis is an opportunistic fungal infection. It is caused by fungi that belong to the class *Zygomycetes*, the order *Mucorales*, the family *Mucoraceae*, and the genus *Rhizopus* is the most common. They are aerogenic microorganisms and therefore the main sites of infection are the paranasal sinuses and the lungs. Nevertheless, they have been documented to have different clinical forms, including rhinocerebral in 44 to 49% of patients, pulmonary in 10-11%, cutaneous in 10-16%, disseminated in 6-12%, and gastrointestinal in 2-7%. Despite its low frequency, intra-abdominal infection has devastating consequences, with a mortality rate as high as 85 to 90%.⁶

With respect to gastrointestinal site involvement, 57.7% of cases are in the stomach, 32.3% in the colon, 6.9% in the ileum, 7% in the esophagus, 2.3% in the duodenum, and 1.1% in the jejunum. Diagnosis has been reported to be antemortem in only 25% of the cases.⁷ Lesions are typically observed as dark ulcers with well-defined edges, with necrosis and thrombosis in the adjacent vessels. Histologic examination reveals thick hyphae with focal bulbous dilation and branching at right angles. Ninety-four percent of the specimens show zones of infarction and angioinvasion.⁸ Treatment consists of debridement, resection of the affected tissue, and antifungal therapy with amphotericin B.

Gastrointestinal mucormycosis is a diagnostic challenge for physicians and therefore requires a high degree of suspicion. The approach and treatment should be carried out by a multidisciplinary team.

Ethical disclosures

Protection of human and animal subjects. The authors declare that no experiments were performed on humans or animals for this study.

Confidentiality of data. The authors declare that they have followed the protocols of their work center on the publication of patient data.

Right to privacy and informed consent. The authors declare that no patient data appear in this article.

Financial disclosure

No financial support was received in relation to this article.

Conflict of interest

The authors declare that there is no conflict of interest.

References

1. Spencer S, Power N. The acute abdomen in the immune compromised host. *Cancer Imaging*. 2008;8:93-101.
2. Rivas Llamas R, Best Aguilera C, Fernández Figueroa YM, et al. Consenso mexicano para el abordaje diagnóstico y terapéutico del paciente con neutropenia febril. *Rev Hematol Mex*. 2014;15 Suppl. 2:S207-68.
3. Chen EH, Mills AM. Abdominal pain in special populations. *Emerg Med Clin North Am*. 2011;29:249-58.
4. Freifeld AG, Bow EJ, Sepkowitz KA, et al. Clinical practice guideline for the use of antimicrobial agents in neutropenic patients with cancer: 2010 Update by the Infectious Diseases Society of America. *Clin Infect Dis*. 2011;52:e56-93.
5. Badgwell BD, Cormier JN, Wray CJ, et al. Challenges in surgical management of abdominal pain in the neutropenic cancer patient. *Ann Surg*. 2008;248:104-9.
6. Lo OS, Law WL. Ileocolonic mucormycosis in adult immunocompromised patients: A surgeon's perspective. *World J Gastroenterol*. 2010;16:1165-70.
7. Thomson SR, Bade PG, Taams M, et al. Gastrointestinal mucormycosis. *Br J Surg*. 1991;78:952-4.
8. Frater JL, Hall GS, Procop GW. Histologic features of zygomycosis: Emphasis on perineural invasion and fungal morphology. *Arch Pathol Lab Med*. 2001;125:375-8.

U. Clemente-Gutiérrez^{a,*}, R.H. Perez-Soto^a,
F.E. Álvarez-Bautista^a, I. Domínguez-Rosado^a,
M. Cuellar-Mendoza^b

^a *Departamento de Cirugía, Instituto Nacional de Ciencias Médicas y Nutrición Salvador Zubirán, Mexico City, Mexico*
^b *Departamento de Anatomía Patológica, Instituto Nacional de Ciencias Médicas y Nutrición Salvador Zubirán, Mexico City, Mexico*

*Corresponding author. Vasco de Quiroga 15, Colonia Belisario Domínguez, Sección XVI, Delegación Tlalpan, Mexico City, Mexico, C.P. 14000. Tel.: +52 15554870900 ext. 7464; fax: +52 15555730778.

E-mail address: uclementeg@gmail.com

(U. Clemente-Gutiérrez).

2255-534X/

© 2018 Asociación Mexicana de Gastroenterología. Published by Masson Doyma México S.A. This is an open access article under the CC BY-NC-ND license (<http://creativecommons.org/licenses/by-nc-nd/4.0/>).