

M.A. Acosta-Mérida\*, D. Ortiz-López, M.M. Callejón-Cara, A. Rahy-Martín, J. Marchena-Gómez

*Servicio de Cirugía General y Aparato Digestivo, Hospital Universitario de Gran Canaria Dr. Negrín, Las Palmas de Gran Canaria, Las Palmas, Spain*

\*Corresponding author. Barranco de la Ballena s/n, 35010 Las Palmas de Gran Canaria, Spain. Tel.: +34 928450000.

E-mail address: [maacosta03@yahoo.es](mailto:maacosta03@yahoo.es)

(M.A. Acosta-Mérida).

2255-534X/

© 2018 Published by Masson Doyma México S.A. on behalf of Asociación Mexicana de Gastroenterología. This is an open access article under the CC BY-NC-ND license (<http://creativecommons.org/licenses/by-nc-nd/4.0/>).

## Prolapsing mucosal polyp: A form of colonic polyp not to be forgotten<sup>☆</sup>



### Pólipo prolapsado de mucosa: una forma de pólipo del colon que no debe ser olvidada

Prolapsing mucosal polyps of the colon are an uncommon finding during colonoscopy. However, when present, those lesions, which are a form of colonic polyps, are frequently unrecognized and misdiagnosed as neoplastic lesions, sometimes leading to unnecessary endoscopic or surgical resection.

We present herein a case of symptomatic prolapsing mucosal polyp of the colon. We also reviewed the clinical, endoscopic, and histopathologic characteristics, as well as the potential management, of that entity.

A 62-year-old woman with no relevant past medical history was referred to our outpatient clinic for resection of a polypoid lesion, previously detected during colonoscopy, that was located in the sigmoid colon. She had a 6-month history of nonspecific gastrointestinal symptoms consisting of constipation and abdominal bloating. Physical examination revealed mild abdominal tenderness in the left lower quadrant upon palpation. Laboratory tests were within normal range.

At flexible rectosigmoidoscopy, we found a 2 cm, lobulated, bright, hyperemic mass projecting into the lumen of the sigmoid colon, with the morphologic characteristics of a polyp (Paris Ip – pedunculated polyp). It had a broad stalk with normal surrounding mucosa, as shown in [fig. 1](#). We also observed a spastic colon and associated sigmoid diverticula. Hot snare polypectomy was performed.

The pathology analysis of the resected lesion, as shown in [fig. 2](#), identified glandular crypt abnormalities and a thickened muscularis mucosae, with fibromuscular obliteration of the lamina propria, all of which are characteristic features of a prolapsing mucosal polyp.

The patient was treated with a high-fiber diet, reporting symptom resolution, along with normal bowel movement frequency and stool consistency.

Prolapsing mucosal polyps are the result of chronic prolapse of the intestinal mucosa. They have been described in

patients undergoing colonoscopic evaluation as large redundant hyperemic mucosal folds that mimic the appearance of a polypoid mass projecting into the lumen of the sigmoid colon. Due to under-recognition or misdiagnosis of said lesion, its true prevalence at endoscopic evaluation is unknown.

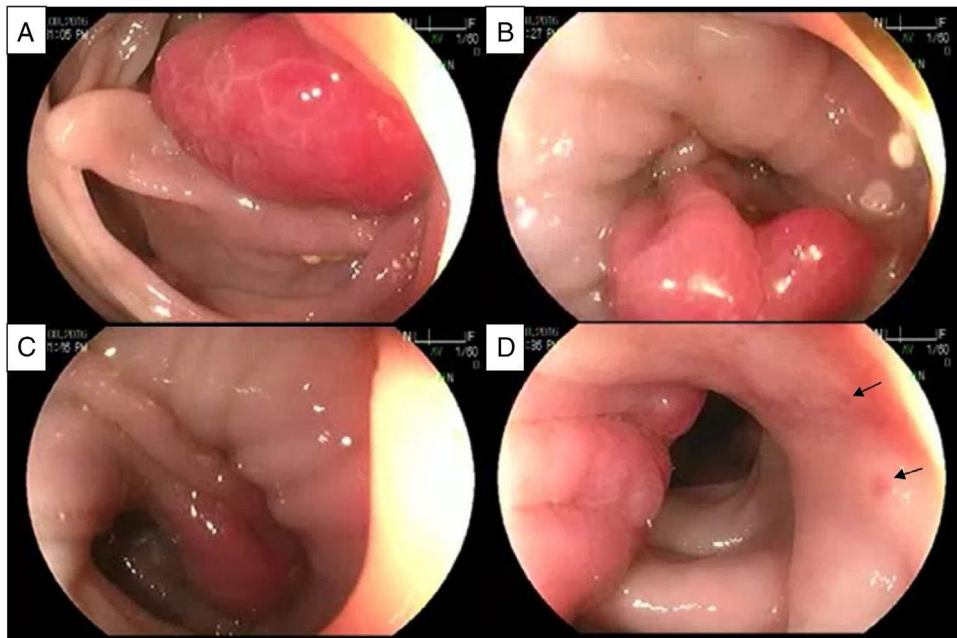
Prolapsing mucosal polyps form part of the spectrum of lesions called “mucosal prolapse syndrome”. That term was proposed in 1977 by Du Boulay et al. to encompass a variety of disorders with similar clinical and histologic characteristics.<sup>1</sup> The proposed conditions that make up part of the so-called mucosal prolapse syndrome include solitary rectal ulcer syndrome,<sup>2-4</sup> gastric antral vascular ectasia,<sup>5</sup> inflammatory cloacogenic polyps,<sup>4</sup> inflammatory “cap” polyps,<sup>6</sup> and prolapsing mucosal polyps,<sup>6</sup> all of which share similar histologic features.<sup>7</sup>

Prolapsing mucosal polyps have been described to occur in the sigmoid colon in association with diverticular disease.<sup>7,8</sup> The exact mechanism leading to the formation of a prolapsing mucosal polyp is uncertain. However, in patients with a long history of defecation straining, a combination of venous congestion and mucosal redundancy secondary to repeated colonic spastic contractions is the most probable mechanism.<sup>8-10</sup> In the largest case series available, Tendler et al.<sup>11</sup> reported on 15 patients with prolapsing mucosal polyps in the sigmoid colon, describing their clinical, endoscopic, and histologic features. Occult gastrointestinal bleeding, hematochezia, cramping abdominal pain, and altered bowel habits were the most frequent presenting symptoms. The main endoscopic features were the presence of hyperemic polyps and prominent redundant folds with petechiae, all involving the sigmoid colon. The most frequently encountered histopathologic findings were glandular crypt abnormalities (hyperplasia, branching, elongation, distortion) in 100%, fibromuscular obliteration of the lamina propria in 93%, hypertrophy and extension of fibromuscular tissue into the lamina propria in 87%, and mucosal capillary abnormalities (congestion, hyalinization, thrombosis, dilation) in 87%.

Common differential diagnoses in patients with prolapsing mucosal polyps are adenomatous polyps, malignancy, ulcerative colitis, and hemangiomas. To the best of our knowledge there are no reports of malignant transformation of prolapsing mucosal polyps.

Currently, there is no consensus on the standard treatment of prolapsing mucosal polyps. Some reports have shown that conservative management based on a high-fiber diet results in a significant regression of those hyperemic polypoid lesions.<sup>10</sup> Their clinical significance lies in the fact

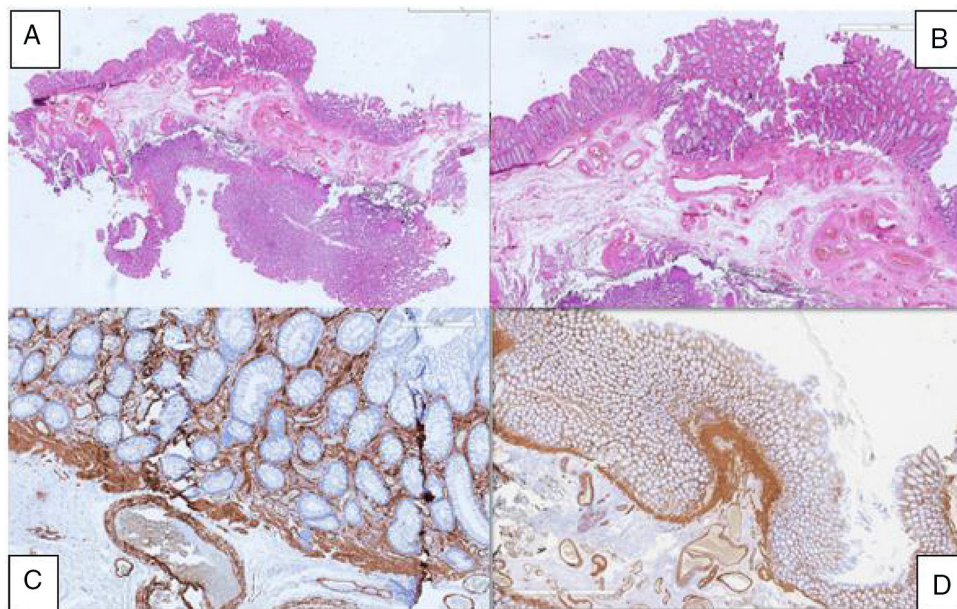
<sup>☆</sup> Please cite this article as: Monreal-Robles R, González-González JA, Benavides-Salgado DE, Maldonado-Garza HJ. Pólipo prolapsado de mucosa: una forma de pólipo del colon que no debe ser olvidada. *Revista de Gastroenterología de México*. 2019;84:407-409.



**Figure 1** Sequential images of the endoscopic appearance of a prolapsing mucosal polyp. A) Lobulated, bright, hyperemic mass. B) Obliteration of the lumen and long-standing spasm are present, showing a prolapsing mucosal polyp with a broad stalk. C) Retraction of the prolapsing mucosal polyp that continues with redundant mucosal folds. Notice the transition from congestive hyperemic mucosa to normal-looking surrounding mucosa. D) Lateral aspect of the lesion showing the redundant mucosal folds with petechiae (arrows).

that they may be responsible for recurrent/persistent overt or occult bleeding and/or obstructive symptoms, settings in which surgical resection is a reasonable option. Long-term follow-up studies are needed to establish the significance and appropriate management of said hyperemic polypoid lesions.

Based on the best available data, endoscopists and pathologists should be familiarized with and recognize the characteristic features of prolapsing mucosal polyps, to prevent the morbidity and related costs of unnecessary endoscopic follow-up, polypectomy, or surgical resection.



**Figure 2** Anatomopathologic analysis of the specimen. A) Panoramic view of the specimen. B) Chronic inflammatory infiltrate and mucosal thickening. C) Glandular abnormalities. D) Thickening of the muscularis mucosae.

## Ethical disclosures

**Protection of human and animal subjects.** The authors declare that no experiments were performed on humans or animals for this study.

**Confidentiality of data.** The authors declare that they have followed the protocols of their work center on the publication of patient data.

**Right to privacy and informed consent.** The authors declare that no patient data appear in this article.

**Right to privacy and informed consent.** The authors have obtained the written informed consent of the patients or subjects mentioned in the article. The corresponding author is in possession of this document.

## Financial disclosure

No financial support was received in relation to this study/article.

## Conflict of interest

The authors declare that there is no conflict of interest.

## References

- Du Boulay CE, Fairbrother J, Isaacson PG. Mucosal prolapse syndrome—a unifying concept for solitary ulcer syndrome and related disorders. *J Clin Pathol.* 1983;36:1264–8.
- Alexander-Williams J. Solitary-ulcer syndrome of the rectum. Its association with occult rectal prolapse. *Lancet.* 1977;1:170–1.
- Womack NR, Williams NS, Holmfield JH, et al. Pressure and prolapse—the cause of solitary rectal ulceration. *Gut.* 1987;28:1228–33.
- Saul SH. Inflammatory cloacogenic polyp: Relationship to solitary rectal ulcer syndrome/mucosal prolapse and other bowel disorders. *Hum Pathol.* 1987;18:1120–5.
- Jabbari M, Cherry R, Lough JO, et al. Gastric antral vascular ectasia: The watermelon stomach. *Gastroenterology.* 1984;87:1165–70.
- Campbell AP, Cobb CA, Chapman RW, et al. Cap polyposis—an unusual cause of diarrhoea. *Gut.* 1993;34:562–4.
- Franzin G, Fratton A, Manfrini C. Polypoid lesions associated with diverticular disease of the sigmoid colon. *Gastrointest Endosc.* 1985;31:196–9.
- Kelly JK. Polypoid prolapsing mucosal folds in diverticular disease. *Am J Surg Pathol.* 1991;15:871–8.
- Oriuchi T, Kinouchi Y, Kimura M, et al. Successful treatment of cap polyposis by avoidance of intraluminal trauma: Clues to pathogenesis. *Am J Gastroenterol.* 2000;95:2095–8.
- Mathus Vliegen EM, Tytgat GN. Polyp-simulating mucosal prolapse syndrome in (pre-) diverticular disease. *Endoscopy.* 1986;18:84–6.
- Tendler DA, Aboudola S, Zacks JF, O'Brien MJ, Kelly CP. Prolapsing mucosal polyps: an underrecognized form of colonic polyp, a clinicopathological study of 15 cases. *Am J Gastroenterol.* 2002;97:370–6.

R. Monreal-Robles, J.A. González-González,  
D.E. Benavides-Salgado\*, H.J. Maldonado-Garza

*Servicio de Gastroenterología y Endoscopia Digestiva,  
Hospital Universitario «Dr. José E. González», Universidad  
Autónoma de Nuevo León, Monterrey, Nuevo León, Mexico*

\*Corresponding author. Av. Madero y Gonzalitos s/n, Col. Mitras Centro, Monterrey, Nuevo León, Mexico, C.P. 64460, University Hospital, Universidad Autónoma de Nuevo León. Phone: +52 81 83 89 11 11.

*E-mail address:* Daniel-benavides@live.com

(D.E. Benavides-Salgado).

2255-534X/

© 2019 Asociación Mexicana de Gastroenterología. Published by Masson Doyma México S.A. This is an open access article under the CC BY-NC-ND license (<http://creativecommons.org/licenses/by-nc-nd/4.0/>).

## Gastrointestinal mucormycosis: An atypical cause of abdominal pain in an immunocompromised patient<sup>☆</sup>



## Mucormycosis gastrointestinal: causa atípica de dolor abdominal en un paciente inmunocomprometido

Abdominal pain in immunocompromised patients is a diagnostic and therapeutic challenge for clinicians because it

presents as a nonspecific manifestation due to the inability of the patient to mount an adequate immune response.

Immunocompromised patients are those that have chronic diseases managed through immunomodulators and that suffer from an alteration in the immune response that is innate or secondary to some other pathology. That group of patients includes persons that are advanced in age, that have diabetes mellitus, HIV infection, or neoplasia. It also includes transplanted patients and those that take medications that modify the immune response, such as steroids, anti-TNF alpha, methotrexate, cyclosporine, and tacrolimus, among others.<sup>1</sup> Myelosuppression is a major systemic toxicity generally associated with chemotherapy treatments. It considerably increases morbidity and mortality, as well as delays in oncologic treatment, thus altering overall survival in those patients.<sup>2</sup>

A 38-year-old woman diagnosed with acute myeloid leukemia sought medical attention at the emergency service due to painful abdominal syndrome. The patient was in

<sup>☆</sup> Please cite this article as: Clemente-Gutiérrez U, Perez-Soto RH, Álvarez-Bautista FE, Domínguez-Rosado I, Cuellar-Mendoza M. Mucormycosis gastrointestinal: causa atípica de dolor abdominal en un paciente inmunocomprometido. *Revista de Gastroenterología de México.* 2019;84:409–411.