

Conflict of interest

The authors declare that there is no conflict of interest.

References

1. Gerson L, Fidler J, Cave D, et al. ACG Clinical Guideline: Diagnosis and Management of Small Bowel Bleeding. *Am J Gastroenterol*. 2015;110:1265–87.
2. Leclaire S, Iwanicki-Caron I, Di-Fiore A, et al. Yield and impact of emergency capsule enteroscopy in severe obscure-overt gastrointestinal bleeding. *Endoscopy*. 2012;44:337–42.
3. Heine G, Hadithi M, Groenen M, et al. Double balloon enteroscopy: Indications, diagnostic yield and complications in a series of 275 patients suspected of small bowel disease. *Endoscopy*. 2006;38:42–8.
4. Casali PG, Abecassis N, Bauer S, et al., ESMO Guidelines Committee and EURACAN. Gastrointestinal stromal tumours: ESMO-EURACAN Clinical Practice Guidelines for diagnosis, treatment and follow-up. *Ann Oncol*. 2018;29 Suppl 4:68–78.

5. Blanco E, Conde B, Cacho A, et al. Tumores del estroma gastrointestinal: evaluación por tomografía mediante los criterios de Choi. *An Radiol Mex*. 2014;13:181–7.

J.J. Aliaga Ramos^{a,*}, J. Espinoza Ríos^a,
J.L. Pinto Valdivia^a, Y. Salas Dueñas^b, R. Chancafe Morgan^b

^a Servicio de Gastroenterología, Hospital Nacional Cayetano Heredia, Lima, Peru

^b Servicio de Anatomía Patológica, Hospital Nacional Cayetano Heredia, Lima, Peru

* Corresponding author. Calle Walter Stubbs 229, Lima, Peru, Tel.: +961-100-593

E-mail address: arjosue3000@gmail.com (J.J.A. Ramos).

23 August 2018 26 November 2018

2255-534X/

© 2018 Asociación Mexicana de Gastroenterología. Published by Masson Doyma México S.A. This is an open access article under the CC BY-NC-ND license (<http://creativecommons.org/licenses/by-nc-nd/4.0/>).

Thrombosis of an infrarenal aortic aneurysm secondary to *Salmonella enteritidis* infection[☆]



Trombosis de aneurisma aórtico infrarrenal secundario a infección por *Salmonella enteritidis*

Acute gastroenteritis after egg ingestion is the most frequent manifestation of *Salmonella enteritidis* (*S. enteritidis*) infection. However, invasive pathology, such as the formation of aortic aneurysms due to invasion of the endothelium, is rare.

We present herein a case of acute gastroenteritis due to *S. enteritidis* complicated by the formation of a previously unknown infrarenal aortic aneurysm, in turn, associated with complete arterial thrombosis of the aneurysm, with the consequent acute arterial ischemia. To the best of our knowledge, the present case of arterial thrombosis associated with an aneurysm infected by *Salmonella* is the first to be described in the literature.

A 57-year-old man had a history of mild chronic obstructive pulmonary disease (COPD) and was under treatment with glycopyrronium bromide.

He sought medical attention at the emergency service due to paresthesia and the inability to walk of 48-h progression. In the days beforehand, he had presented with symptoms of acute gastroenteritis after eating eggs, that

included vomiting, greenish diarrhea with up to 18 bowel movements daily, fever of 38 °C, and general malaise.

Upon his arrival at the emergency service, the patient presented with blood pressure of 181/118 mmHg, heart rate of 118 bpm, and temperature of 35.4 °C. Physical examination revealed peripheral hypoperfusion in both lower limbs, with *livedo reticularis* up to the pelvis. Laboratory test results showed hemoglobin 15 mg/dL, leukocytes $5.9\text{--}10.70 \times 10^3/\text{L}$, creatinine 2.45 mg/dL, creatine kinase 20,000 U/L, sodium 140 mEq/L, potassium 5.5 mEq/L, pH 7.15, pCO₂ 44 mm Hg, pO₂ 98 mm Hg, and lactic acid 10.1 mg/dL.

With the suspicion of acute arterial ischemia, a contrast-enhanced abdominal computed tomography (CT) scan was carried out that showed dilation of the aneurysm and complete thrombosis of the infrarenal abdominal aorta (Fig. 1). Anticoagulation with low-molecular-weight heparin was begun and emergency right axillofemoral bypass was performed (Fig. 2). Immediate postoperative progression was good. Empiric antibiotic therapy was started with meropenem and vancomycin. Multi-sensitive serogroup D *Salmonella* was isolated in blood cultures and the antibiotic was downscaled to 4 weeks of treatment with ceftriaxone 2 g daily.

Daily fever peaks persisted despite the antibiotic therapy. Infection of the vascular stent was suspected and so a positron emission tomography (PET-CT) scan and a scintigram with analogous leukocytes labeled with HMPAO-Tc99m were carried out, through which infection at the level of the bypass was ruled out.

Acute gastroenteritis due to *Salmonella* spp. is the most frequent manifestation of infection caused by that Gram-negative bacillus. Invasive disease due to *S. enteritidis* is 6 times more frequent than other causes of bacterial gastroenteritis and is more frequent in persons above 60 years of age and in children.¹

As in the case presented herein, the formation of mycotic or infected aneurysms is a rare manifestation of systemic

[☆] Please cite this article as: García-Fernández-Bravo I, González-Munera A, Ordieres-Ortega L, González-Leyte M. Trombosis de aneurisma aórtico infrarrenal secundario a infección por *Salmonella enteritidis*. *Revista de Gastroenterología de México*. 2019;84:522–524. <https://doi.org/10.1016/j.rgmx.2018.12.002>.

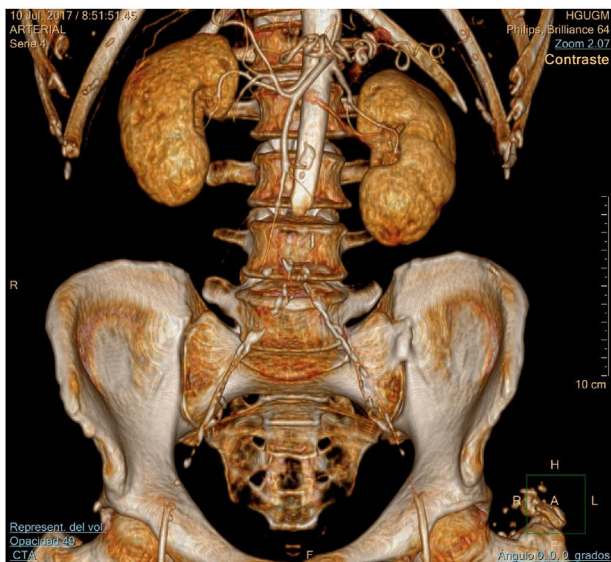


Figure 1 Thrombosed infrarenal aortic aneurysm.

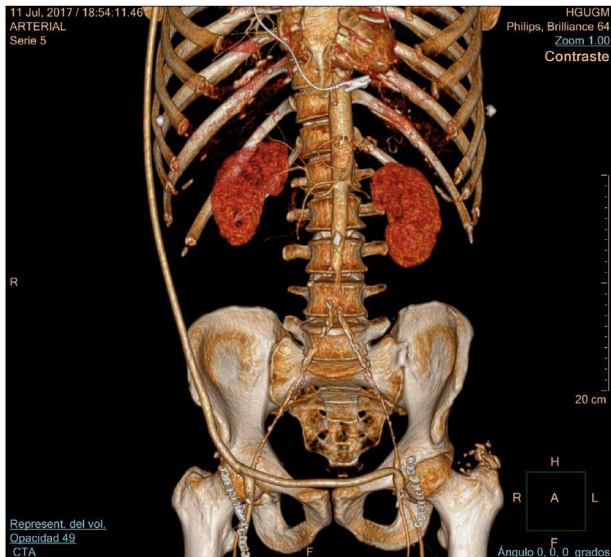


Figure 2 Axillobifemoral bypass.

infection and requires the combination of antibiotic therapy and aggressive surgical debridement as initial treatment.^{2,3}

Iatrogenic arterial injury or that caused by intravenous drug injection, active infection (such as pneumonia, spondylodiscitis, or buccal infection), immunosuppressive factors, atherosclerosis, and infection secondary to a pre-existing aneurysm are the outstanding risk factors for the formation of infected aneurysms.

In the present case, there was no previous diagnosis of aortic aneurysm, despite the fact that the patient's age and sex put him in the at-risk population. However, the patient did not present with any risk factor related to his superinfection.

The rare complication of thrombosis of an aortic aneurysm that occurred in the present case should be underlined. Despite the fact that the surgically extracted thrombus was not cultured, the hyper-acute clinical man-

ifestation of arterial ischemia in both lower limbs and the rapid positivity of the blood cultures led us to suppose the coexistence of the two events and the probability that the *Salmonella* infection was the cause of the formation of the thrombus.

The diagnosis was made through the rapid growth of ciprofloxacin-resistant serogroup D *Salmonella* in the blood cultures, enabling early directed treatment and antibiotic therapy adjustment to be carried out, even before the emergency axillobifemoral bypass procedure.

The most frequent clinical feature of a superficial infected aneurysm, when there is fever of unclear origin, is a mass that is painful and pulsatile upon palpation, associated with elevated acute-phase reactants in the laboratory analysis. In the case of a deep-seated infected aneurysm, diagnosis tends to be made through a CT or PET-CT scan, as occurred in the present case.⁴⁻⁶ The location of the aneurysm is important for patient outcome, and the infrarenal location has a higher survival rate.

Because there are no randomized studies on the different types of possible treatments for infected aneurysms, management recommendations are based on clinical experience and case series reported in the literature.

Standard treatment consists of antibiotic therapy combined with surgical debridement, with or without associated immediate or deferred revascularization. Endovascular techniques are currently emerging as alternative treatment in high-risk surgical patients.⁷⁻⁹ In cases of thrombosed mycotic aneurysms, antibiotic treatment should be added to the anticoagulant and/or interventionist management. As empiric antibiotic therapy, the combination of vancomycin to cover methicillin-resistant *Staphylococcus aureus* and ceftriaxone, fluoroquinolones, or piperacillin-tazobactam to cover Gram-negative bacteria is recommended.¹⁰ Optimum treatment duration is uncertain and should be individualized, depending on immune status, location, and the causal microorganism. In many studies, a minimum of 6 weeks of parenteral treatment is recommended, before the later decision on long-term antibiotic therapy, albeit said duration can vary and in some cases is indefinite.⁹

Finally, after a prolonged hospital stay of 2 months with numerous complications, the patient described herein was afebrile after completing 8 weeks of endovenous antibiotic therapy and control blood cultures were negative. He was released from the hospital, maintaining anticoagulant treatment, but with no need to continue oral antibiotic therapy.

Ethical disclosures

The authors declare that both verbal and written informed consent was obtained from the patient described in the article for his participation in the study, the handling of his personal data, and the publication of the images. The study was also approved by the hospital ethics committee.

Financial disclosure

No financial support was received in relation to this article.

Conflict of interest

The authors declare that there is no conflict of interest.

References

1. European Food Safety Authority (EFSA) and European Centre for Disease Prevention and Control (ECDC). EU Summary Report on antimicrobial resistance in zoonotic and indicator bacteria from humans, animals and food in 2014. *EFSA J.* 2016;14:4380.
2. Osler W. The Gulstonian lectures, on malignant endocarditis. *Br Med J.* 1885;1:467–70.
3. Maeda H, Umezawa H, Goshima M, et al. Primary infected abdominal aortic aneurysm: surgical procedures, early mortality rates, and a survey of the prevalence of infectious organisms over a 30-year period. *Surg Today.* 2011;41:346–51.
4. Brown SL, Busuttill RW, Baker JD, et al. Bacteriologic and surgical determinants of survival in patients with mycotic aneurysms. *J Vasc Surg.* 1984;1:541–7.
5. Choi SJ, Lee JS, Cheong MH, et al. F-18 FDG PET/CT in the management of infected abdominal aortic aneurysm due to *Salmonella*. *Clin Nucl Med.* 2008;33:492–5.
6. Spacek M, Stadler P, Belohlávek O, et al. Contribution to FDG-PET/CT diagnostics and post-operative monitoring of patients with mycotic aneurysm of the thoracic aorta. *Acta Chir Belg.* 2010;110:106–8.
7. Davison JM, Montilla-Soler JL, Broussard E, et al. F-18 FDG PET-CT imaging of a mycotic aneurysm. *Clin Nucl Med.* 2005;30:483–7.
8. Sörelíus K, Mani K, Björck M, et al. Endovascular treatment of mycotic aortic aneurysms: a European multicentre study. *Circulation.* 2014;130:2136–42.
9. Heinola I, Sörelíus K, Wyss TR, et al. Open repair of mycotic abdominal aortic aneurysms with biological grafts: an international multicentre study. *J Am Heart Assoc.* 2018;7:e008104.
10. Forbes TL, Harding GE. Endovascular repair of *Salmonella*-infected abdominal aortic aneurysms: a word of caution. *J Vasc Surg.* 2006;44:198–200.

I. García-Fernández-Bravo^{a,*}, A. González-Munera^a, L. Ordieres-Ortega^a, D. Ruiz Chiriboga^b y M. González-Leyte^c

^a Servicio de Medicina Interna, Hospital General Universitario Gregorio Marañón, Madrid, España

^b Servicio de Angiología y Cirugía Vascul, Hospital General Universitario Gregorio Marañón, Madrid, España

^c Unidad de Radiología Vascul, Servicio de Radiodiagnóstico, Hospital General Universitario Gregorio Marañón, Madrid, España

* Corresponding author. Calle Bravo Murillo 53. Código postal: 28003, Madrid, Spain.

E-mail address: irenegfb@gmail.com

(I. García-Fernández-Bravo).

2255-534X/

© 2019 Asociación Mexicana de Gastroenterología. Published by Masson Doyma México S.A. This is an open access article under the CC BY-NC-ND license (<http://creativecommons.org/licenses/by-nc-nd/4.0/>).

Rectal tuberculosis: An uncommon clinical presentation and differential diagnosis with Crohn's disease[☆]



Tuberculosis rectal: presentación clínica infrecuente y diagnóstico diferencial con enfermedad de Crohn

Tuberculosis (TB) is an infectious disease caused by *Mycobacterium tuberculosis* and its most frequent location is the lung. In order of frequency, extrapulmonary TB can affect the lymph nodes, the genitourinary tract, the osteoarticular system, the meninges, and the digestive tract. Digestive involvement can present at any segment of the gastrointestinal tract, and most frequently affects the ileocecal region.^{1–3}

The clinical and endoscopic presentations of intestinal TB can be similar to those of other diseases, such as neoplasias and Crohn's disease (CD). Therefore, a high level of suspicion is required, as well as the performance of microbiologic

studies, to opportunely confirm the diagnosis. The differential diagnosis with CD can be difficult, especially in areas of endemic infection and in immunosuppressed patients, but it is important to make it, given that in the case of an erroneous diagnosis of CD, beginning immunosuppressant treatment could exacerbate the TB.^{1–4}

In Latin America, the incidence of TB in 2015 was 22 cases per 100,000 inhabitants. In Mexico, the figures were 17 cases per 100,000 inhabitants, signifying that the disease continues to be a public health problem. In Chile, the reported incidence of TB in 2014 was 12.3 cases per 100,000 inhabitants and 21.3% of the new cases were extrapulmonary TB. Coinfection due to HIV is one of the main risk factors for the development of the disease.^{5,6}

The clinical manifestation of TB depends on the intestinal segment involved and abdominal pain is described in 85% of the patients, weight loss in 66%, fever in 35–50%, and diarrhea in 20% of the cases. Cases with clinical pictures of bowel obstruction and massive gastrointestinal bleeding secondary to TB are reported in the literature.^{2,3,7}

TB affecting the rectum is rare, even in areas of high prevalence of the disease, such as Asia and Africa. Its clinical presentation can be rectal bleeding or diarrhea. Endoscopic study usually reveals a concentric stricture, suggesting the differential diagnosis with neoplasia and requiring endoscopic biopsy. Surgical resection for making the diagnosis has been reported in some cases.^{1–4,8}

[☆] Please cite this article as: Gompertz M, Carreño L, Gil La Rotta LC. Tuberculosis rectal: presentación clínica infrecuente y diagnóstico diferencial con enfermedad de Crohn. *Rev Gastroenterol Méx.* 2019;84:524–526.