



# REVISTA DE GASTROENTEROLOGÍA DE MÉXICO

[www.elsevier.es/rgmx](http://www.elsevier.es/rgmx)



## CLINICAL IMAGE IN GASTROENTEROLOGY

# The anatomic variant of common celiacomesenteric trunk<sup>☆</sup>



## La variante anatómica del tronco celiaco mesentérico común

U.G. Rossi<sup>a,d,\*</sup>, A.M. Ierardi<sup>b,c</sup>, M. Cariati<sup>d</sup>

<sup>a</sup> Departamento de Imagen Diagnóstica, Unidad de Radiología Intervencionista, E.O. Hospital Galliera, Genoa, Italy

<sup>b</sup> Departamento de Radiología Diagnóstica e Intervencionista, Universidad de Milán, Milan, Italy

<sup>c</sup> Unidad de Radiología y de Radiología Intervencionista, ASST Santi Paolo y Carlo, Hospital San Paolo, Milan, Italy

<sup>d</sup> Departamento de Diagnóstico y Terapia de Tecnología Avanzada, Hospital San Carlo Borromeo, Milan, Italy

A 74-year-old man came to our emergency department due to abdominal trauma. He underwent an abdominal multidetector computed tomography scan that ruled out traumatic abdominal pathologies. Vascular para-coronal volume rendering reconstruction highlighted an asymptomatic common celiacomesenteric trunk vascular variant (Fig. 1).

The patient was discharged with an annual clinical, laboratory, and imaging follow-up program.

Multiple arterial splanchnic vasculature variants may occur during the embryologic process.

Common celiacomesenteric trunk, in which the celiac trunk and superior mesenteric artery have a common aortic origin, is the least frequent abdominal vascular anatomic variant. It causes unique vascular variants of its collateral vessels and patients are mostly asymptomatic. However, when symptoms appear or pathology is

suspected (aneurysm, dissection, nutcracker syndrome, etc.), those patients must be studied. Multidetector computed tomography is considered the first-line noninvasive diagnostic method for characterizing the abdominal vascular anatomy.

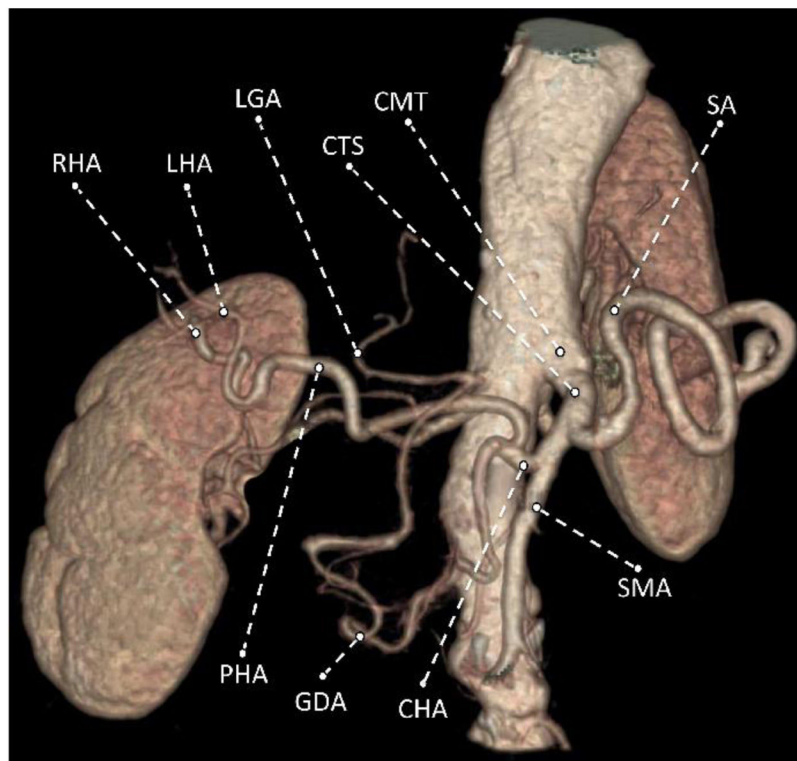
### Ethical disclosures

**Protection of humans and animal subjects.** The authors declare that no experiments were performed on humans or animals for this study. The procedures carried out were in accordance with the regulations of the relevant clinical research ethics committees and with those of the Code of Ethics of the World Medical Association (Declaration of Helsinki).

<sup>☆</sup> Please cite this article as: Rossi UG, Ierardi AM, Cariati M. La variante anatómica del tronco celiaco mesentérico común. Revista de Gastroenterología de México. 2020;85:86–87.

\* Corresponding author.

E-mail address: [urossi76@hotmail.com](mailto:urossi76@hotmail.com) (U.G. Rossi).



**Figure 1** Multidetector computed tomography with volume rendering technique reconstruction that shows the vascular anatomic variant of common celiacomesenteric trunk.

CMT: common celiacomesenteric trunk; CHA: common hepatic artery; CTS: celiac trunk segment; GDA: gastroduodenal artery; LGA: left gastric artery; LHA: left hepatic artery; PHA: proper hepatic artery; RHA: right hepatic artery; SA: splenic artery; SMA: superior mesenteric artery.

**Confidentiality of data.** The authors declare that they have followed the protocols of their work center on the publication of patient data.

**Right to privacy and informed consent.** The authors have obtained the written informed consent of the patients or subjects mentioned in the article. The corresponding author is in possession of this document.

### Financial disclosure

No financial support was received in relation to this study/article.

### Conflict of interest

The authors declare that there is no conflict of interest.