



REVISTA DE GASTROENTEROLOGÍA DE MÉXICO

www.elsevier.es/rgmx



CLINICAL IMAGE IN GASTROENTEROLOGY

The portal, splenic, and mesenteric vein system[☆]

El sistema venoso portal, esplénico y mesentérico



U.G. Rossi^{a,c,*}, G.A. Rollandi^b, M. Cariati^c

^a *Departamento de Imagen Diagnóstica, Unidad de Radiología Interventiva, E.O. Hospital Galliera, Genoa, Italy*

^b *Departamento de Imagen Diagnóstica, Unidad de Radiología, E.O. Hospital Galliera, Genoa, Italy*

^c *Unidad de Radiología Interventiva, Departamento de Tecnología Avanzada de Diagnóstico y Terapia, ASST Santi Paolo y Carlo-Hospital San CarloBorromeo, Milan, Italy*

An 85-year-old woman, with a clinical history of previous surgical and percutaneous treatments for hepatocellular carcinoma, had periodic follow-up examinations. In post-treatment imaging surveillance, a contrast-enhanced multidetector computed tomography (MD-CT) scan was performed to evaluate the possible presence of new lesions and to study the hepatic vasculature. The examination revealed a new nodular lesion in the eighth hepatic segment that was consistent with hepatocellular carcinoma.

Image postprocessing for the hepatic arterial and venous vascular system was performed. Through MD-CT with volume rendering, reconstruction of the portal, splenic, and mesenteric vein system was unremarkable, with no vascular pathologies or anatomic variations (Fig. 1). Consequently, the patient underwent transarterial chemoembolization, with technical and clinical success.

[☆] Please cite this article as: Rossi UG, Rollandi GA, Cariati M. El sistema venoso portal, esplénico y mesentérico. *Revista de Gastroenterología de México*. 2020;85:209–210.

* Corresponding author. Unidad de Radiología Interventiva, Departamento de Imagen Diagnóstica, E.O. Hospital Galliera, Mura delle Cappuccine, 14 - 16128 Genoa, Italy. Tel.: +39 010 5634154; Fax: +-39 010 5634154.

E-mail address: urossi76@hotmail.com (U.G. Rossi).

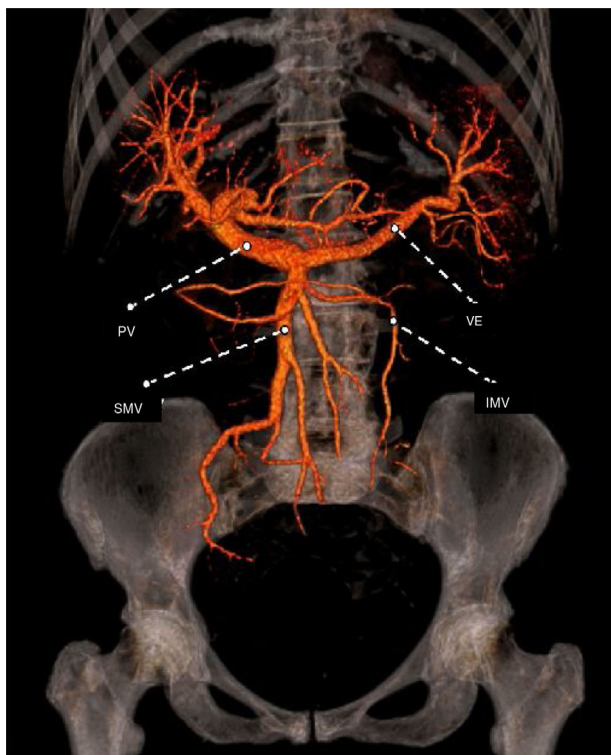


Figure 1 Coronal view of the reconstruction of the portal, splenic, and mesenteric vein system through MD-CT with volume rendering.

Ethical disclosures

Protection of human and animal subjects. The authors declare that no experiments were performed on humans or animals for this research.

Confidentiality of data. The authors declare that they have followed the protocols of their work center on the publication of patient data.

Ethics committee. E.O. Galliera Hospital and Regional Ethics Committee.

Right to privacy and informed consent. The authors declare that patient anonymity was preserved at all times, making informed consent unnecessary for the publication of the present article.

Financial disclosure

No financial support was received in relation to this article.

Conflict of interest

The authors declare that there is no conflict of interest.

IMV: inferior mesenteric vein; PV: portal vein; SMV: superior mesenteric vein; SV: splenic vein.