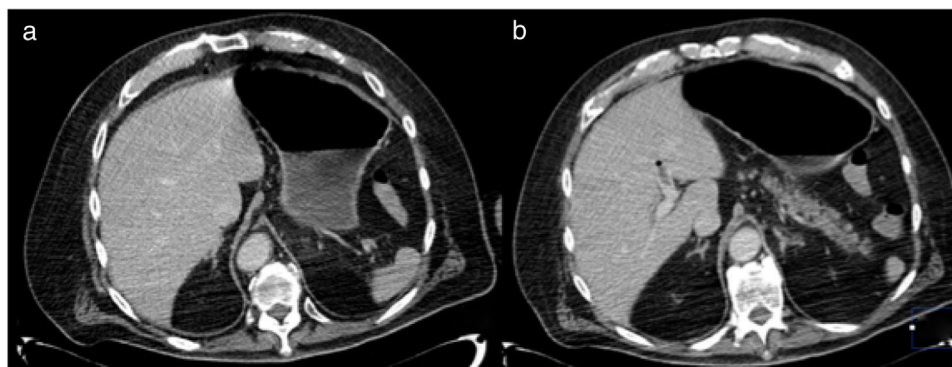

**Figure 2** a) CAT scan showing no evidence of abnormal thickening of the stomach, and resolution of the pneumatosis can be seen; b) Decrease in portal vein gas, with the presence of a thrombus in the left branch.

Authorization from the bioethics committee was obtained, explaining that no personal information that could identify the patient appears in the present article.

### Financial disclosure

No financial support was received in relation to this article.

### Conflict of interest

The authors declare that there is no conflict of interest.

### References

- González IB, Soliva Martínez D, Castro García A, et al. Neumatosis gástrica: cuándo no operar. *Cir Esp*. 2018;96:121–3, <http://dx.doi.org/10.1016/j.cireng.2018.01.009>.
- Szuchmacher M, Bedford T, Sukharamwala P, et al. Is surgical intervention avoidable in cases of emphysematous gastritis? A case presentation and literature review. *Int J Surg Case Rep*. 2013;4:456–9.
- Zenooz N, Robbin MR, Pérez V. Gastric pneumatosis following nasogastric tube placement a case report with literature review. *Emerg Radiol*. 2007;13:205–7.
- St Peter SD, Abbas MA, Kelly KA. The Spectrum of Pneumatosis Intestinalis. *Arch Surg*. 2003;138:68–75.
- Matsushima K, Won EJ, Tangel MR, et al. Emphysematous Gastritis and Gastric Emphysema: Similar Radiographic Finding Distinct Clinical Entities. *World J Surg*. 2015;39:1008–17.
- Reimunde E, Gutiérrez M, Balboa O, et al. Neumatosis gástrica. *Gastroenterol Hepatol*. 2002;25:458–61.

F.U. Pastor-Sifuentes\*, P. Moctezuma-Velázquez, J. Aguilar-Frasco

*Departamento de Cirugía, Instituto Nacional de Ciencias Médicas y Nutrición Salvador Zubirán, Mexico City, Mexico*

\* Corresponding author. Vasco de Quiroga, Colonia Sección XVI, Tlalpan C.P. 1400, Mexico City, Mexico. Tel.: + 54870900, Ext.: 2133

E-mail address: [pacopastor1189@gmail.com](mailto:pacopastor1189@gmail.com) (F.U. Pastor-Sifuentes).

2255-534X/ © 2019 Asociación Mexicana de Gastroenterología. Published by Masson Doyma México S.A. This is an open access article under the CC BY-NC-ND license (<http://creativecommons.org/licenses/by-nc-nd/4.0/>).

## Severe olmesartan-induced sprue-like enteropathy with good corticosteroid treatment response<sup>☆</sup>



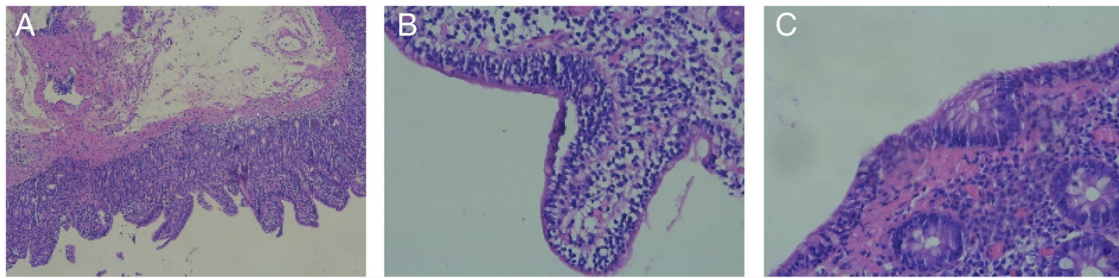
### Enteropatía *sprue-like* grave por olmesartán con buena respuesta a tratamiento esteroideo

Sprue-like enteropathy due to olmesartan produces symptoms of diarrhea and weight loss, as well as intestinal histologic

changes associated with its use. The entity was described in 2012 in a study on 22 patients.<sup>1</sup> In 2013, the Food and Drug Administration (FDA) released an alert about the relation between olmesartan use and enteropathy, and numerous cases have been reported since then.<sup>2</sup>

We present herein the case of a 74-year-old woman, with chronic ischemic heart disease and multiple cardiovascular risk factors, that was admitted to our center due to the sudden onset of diarrhea of 3-week progression. Stools were watery, with no pathologic product, and the patient presented with more than 10 evacuations daily. There were no other accompanying clinical manifestations. Symptoms resolved spontaneously after 48 h of hospital admission and the patient was released. Five days later, the patient returned, complaining of the same symptoms. They again resolved after 24h of conservative hospital treatment and the patient was discharged to her home. Forty-eight hours after her second release, the patient was admitted to

<sup>☆</sup> Please cite this article as: Alonso-Beato R, González-Pérez JA, Demelo-Rodríguez P. Enteropatía *sprue-like* grave por olmesartán con buena respuesta a tratamiento esteroideo. *Revista de Gastroenterología de México*. 2020;85:220–222.



**Figure 1** A) duodenal slice showing villous atrophy consistent with Marsh classification grade 3a (magnification  $\times 5$ ), B) duodenal slice showing intraepithelial lymphocytosis (magnification  $\times 20$ ), and C) colonic slice showing intraepithelial lymphocytosis (magnification  $\times 30$ ).

the intensive care unit, presenting with new episodes of diarrhea, hypotension that was refractory to fluid therapy, and acute kidney failure. She received support treatment, without requiring vasoactive drugs, and the diarrhea resolved after the first 72 h.

Adult celiac disease testing was negative, with normal IgA levels and negative results for IgA anti-tissue transglutaminase antibodies. Gastroscopy and colonoscopy were performed, and the histologic findings were villous atrophy, intraepithelial lymphocytes, and crypt hyperplasia, consistent with Marsh classification grade 3a (fig. 1A and B). Biopsy of the colon revealed intraepithelial lymphocytosis (Fig. 1C). Those findings were consistent with the histology described for olmesartan-induced sprue-like enteropathy.<sup>3</sup>

Finally, given the case progression, and after reviewing the literature, treatment with olmesartan was suspended; the drug had not been administered during the patient's hospital admissions because it was not available at our hospital center's pharmacy. Steroid treatment (methylprednisolone 16 mg/12 h) was begun, symptoms improved, and the patient was discharged to her home, with tapering of the corticosteroid therapy. At month six of follow-up, the patient has not presented with new episodes of diarrhea.

The real incidence of olmesartan-induced sprue-like enteropathy is currently unknown, albeit there are an increasing number of reported cases. The previously undescribed particularity observed in the progression of our patient was its severity, resulting in her admission to the intensive care unit. Symptom response to the suspension of olmesartan, as well as to corticoid treatment, which is the only management alternative described once the clinical presentation has occurred, should also be emphasized.<sup>4</sup> Nevertheless, maintaining a high level of suspicion regarding the pathology appears to be the most important aspect, to prevent the performance of unnecessary studies and the prolongation of symptoms that can become severe, as seen in our patient.

In conclusion, olmesartan-induced sprue-like enteropathy is an emerging pathology that has begun to be diagnosed exponentially, since the detection of the first cases, and should be kept in mind in the differential diagnosis of diarrhea. In addition, it exemplifies the important role of drugs as etiologic factors of numerous pathologies, reminding us not to ignore them as possible causes.

## Ethical disclosures

**Protection of human and animal subjects.** The authors declare that the procedures followed were in accordance with the regulations of the relevant clinical research ethics committee and with those of the Code of Ethics of the World Medical Association (Declaration of Helsinki).

**Confidentiality of data.** The authors declare that they have treated all patient data with confidentiality and anonymity, following the protocols of their work center. Because our center's treatment protocol for this pathology was followed, authorization from the bioethical committee was not required.

## Financial disclosure

No specific grants were received from public sector agencies, the business sector, or non-profit organizations in relation to this study.

## Conflict of interest

The authors declare that there is no conflict of interest.

## References

1. Rubio-Tapia A, Herman ML, Ludvigsson JF, et al. Severe sprue-like enteropathy associated with olmesartan. *Mayo Clin Proc.* 2012;87:732–8.
2. FDA Drug Safety Communication: FDA approves label changes to include intestinal problems (sprue-like enteropathy) linked to blood pressure medicine olmesartan medoxomil; 2013.
3. Carneiro L, Moreira A, Pereira A, et al. Olmesartan-induced sprue like enteropathy. *GE Port J Gastroenterol.* 2016;23:101–5.
4. DeGaetani M, Tennyson CA, Lebwohl B, et al. Villous atrophy and negative celiac serology: a diagnostic and therapeutic dilemma. *Am J Gastroenterol.* 2013;108:647–53.

R. Alonso-Beato\*, J.A. González-Pérez,  
P. Demelo-Rodríguez

*Servicio de Medicina interna, Hospital General Universitario Gregorio Marañón, Madrid, Spain*

\*Corresponding author at: Hospital General Universitario Gregorio Marañón, C/ Doctor Esquerdo, 46, CP 28007 Madrid. Tel.: 617164609  
E-mail address: ralonso\_92@hotmail.com (R. Alonso-Beato).

2255-534X/ © 2020 Asociación Mexicana de Gastroenterología. Published by Masson Doyma México S.A. This is an open access article under the CC BY-NC-ND license (<http://creativecommons.org/licenses/by-nc-nd/4.0/>).

## Three case reports of impacted biliary stone extraction basket<sup>☆</sup>



### Tres reportes de caso de canastilla de extracción de cálculo biliar impactada

Endoscopic retrograde cholangiopancreatography (ERCP) is a widely performed procedure for the treatment of choledocholithiasis, and more than 90% of bile duct stones can be removed endoscopically.<sup>1</sup> Biliary lithotriptors are commonly used to capture and extract the stones, as well as for the performance of mechanical lithotripsy.<sup>2</sup>

Failure of mechanical lithotripsy can occur when there is a discrepancy between the size of the bile duct stone and the diameter of the distal bile duct,<sup>3</sup> or if the stone is large (>10 mm) and hard.<sup>4</sup> Possible complications are impaction of the stone extraction basket, rupture of the traction wire or the main operation wire, malfunction of the mechanical lithotripter crank handle, or ductal injury, which occur in 0.6–5.9% of procedures.<sup>5</sup>

Rapid removal of an impacted biliary stone extraction basket is obligatory to avoid injury to the bile ducts or the intestine. Endoscopic success is achieved in more than 94% of mechanical lithotripsy procedures<sup>5</sup> but surgical intervention is necessary in some patients.<sup>2–5</sup>

We describe herein 3 cases in which an impacted stone extraction basket was retrieved.

#### Case 1

A 64-year-old man was admitted to the hospital with jaundice, upper abdominal pain, and nausea. Abdominal computed tomography revealed *situs inversus totalis* and a large bile duct stone. ERCP was performed with a 180° rotation of the duodenoscope in the second portion of the duodenum, and cholangioscopy revealed 3 giant stones in the common bile duct (the largest measuring 27 mm) (Fig. 1A). Mechanical lithotripsy was attempted but was complicated by a traction wire fracture. Rescue-retrieval forceps were used to dislodge the basket-stone complex, the impacted mechanical lithotripter was removed uneventfully, and a bile duct plastic stent was placed. Three days later, intraductal cholangioscopy utilizing the SpyGlass® DS system (Boston Scientific Inc., Marlborough, Massachusetts, USA) and laser lithotripsy were successfully performed.

#### Case 2

A 64-year-old man was initially evaluated at a different hospital for jaundice of one-week progression. Abdominal computed tomography showed a dilated intrahepatic bile duct and extra-

hepatic common bile duct secondary to a 13 mm stone. ERCP was attempted and failed, and a bile duct stent was placed. The patient was referred to our hospital for definitive management. ERCP was performed, and the stent was removed with a snare. Cholangiography revealed a large stone in the common bile duct. After maximal sphincterotomy and biliary balloon dilatation, attempts to clear the stone with a balloon catheter failed. A mechanical lithotripter basket was advanced, and the stone was captured. The stone could not be pulled out of the bile duct into the duodenum, and the basket traction wire fractured near the handle. Soehendra® mechanical lithotripsy was attempted, and another traction wire fracture occurred. The stone-lithotripter complex became stuck in the common bile duct. The proximal piece of the basket was then grasped with a pair of rescue-retrieval forceps and successfully removed (Fig. 1B and C, Appendix B supplementary video: demonstration of the recovery of the impacted biliary stone extraction basket, utilizing a rescue-retrieval forceps). The ERCP process was completed with the insertion of a plastic biliary stent. At the follow-up ERCP one week later, the plastic stent and the stone had spontaneously passed out of the bile duct.

#### Case 3

A 66-year-old woman was referred to our hospital due to intermediate risk of choledocholithiasis. An endoscopic ultrasound study identified intrahepatic and extrahepatic bile duct dilatation, associated with multiple stones in the common bile duct. An ERCP was attempted. Cholangiography revealed multiple stones, the largest of which had a diameter of 32 × 65 mm. Sphincterotomy with balloon sphincteroplasty was performed. Seven stones were pulled into the duodenum with a balloon catheter. Biliary extraction basket lithotripsy was attempted for the largest stone, but failed, becoming impacted in the bile duct. Soehendra® mechanical lithotripsy was attempted but was complicated by a traction wire fracture, making extraction impossible. After covering the metallic sheath with a plastic one, the patient was sent to surgery for lithotripter extraction (Fig. 1D).

Basket impaction is an uncommon but recognized complication of ERCP stone extraction, and is a medical emergency.<sup>3</sup> The usefulness of certain maneuvers to retrieve baskets is anecdotal. Some successful techniques have been the use of a Soehendra® mechanical lithotripter, extracorporeal shock-wave lithotripsy,<sup>2</sup> traction with biopsy forceps,<sup>6</sup> endoscopic intracorporeal electrohydraulic shock-wave lithotripsy,<sup>1</sup> endoscopic laser lithotripsy,<sup>7</sup> post-cut technique with a needle knife,<sup>8</sup> flipping the tip” of an impacted basket with a second basket, the use of rat-tooth forceps, and stenting the fractured wire outside the mouth with shorter metal sheaths.<sup>3,4</sup>

Those salvage methods are not always successful. A watchful waiting strategy can be employed in some cases, after providing biliary drainage or management through a percutaneous transhepatic approach,<sup>9,10</sup> whereas other patients will end up in the operating room.<sup>10</sup> Such cases are a therapeutic challenge. To the best of our knowledge, the case of the successful removal of the impacted biliary stone extraction basket utilizing rescue-retrieval forceps with no complications in the patient

<sup>☆</sup> Please cite this article as: Tepox-Padrón A, Romano-Munive F, Ramírez-Polo AI, Téllez-Ávila FI. Tres reportes de caso de canastilla de extracción de cálculo biliar impactada. *Revista de Gastroenterología de México*. 2020;85:222–224.