

9. Zappa MA, Aiolfi A, Antonini I, Musolino CD, Porta A. Subcapsular hepatic haematoma of the right lobe following endoscopic retrograde cholangiopancreatography: case report and literature review. *World J Gastroenterol.* 2016;22:4411–5.

E.R. Fernández-Enríquez\*, O. Bada-Yllán, M.A. López y López, R. Delano-Alonso, J.J. Herrera-Esquivel

*División de Cirugía General y Endoscópica, Hospital General Dr. Manuel Gea González, Mexico City, Mexico*

\*Corresponding author at: Calzada de Tlalpan 4800, Col. Sección XVI Tlalpan, C.P 4800, Mexico City, Mexico. Tel.: +55 44 41 40 93 28; fax: +55 4000 3000.

E-mail address: [dr.enriquefdez@gmail.com](mailto:dr.enriquefdez@gmail.com) (E.R. Fernández-Enríquez).

2255-534X/ © 2019 Asociación Mexicana de Gastroenterología. Published by Masson Doyma México S.A. This is an open access article under the CC BY-NC-ND license (<http://creativecommons.org/licenses/by-nc-nd/4.0/>).

## Transgastric drainage of a liver abscess through endoscopic ultrasound in a patient with multiple organ failure<sup>☆</sup>



### Drenaje transgástrico por ultrasonido endoscópico de un absceso hepático en paciente con disfunción multiorgánica

Liver abscesses are defined as single or multiple encapsulated collections of purulent material, in the hepatic parenchyma.<sup>1</sup> Etiology is varied and can be pyogenic and/or amoebic. Infections due to other microorganisms are less frequent. The estimated prevalence of liver abscesses is low, but according to reports in the literature, the mortality rate is high, ranging from 8 to 31%.<sup>2-3</sup> Patient progression depends on etiology, comorbidities, and the interval of time from diagnosis to treatment. There are numerous therapeutic strategies: medical management with antibiotics, surgical drainage, and more recently, drainage through endoscopic ultrasound in selected cases,<sup>4-6</sup> and said advances have helped decrease morbidity and mortality in those patients.

A 54-year-old woman from a rural area, with an unremarkable pathologic history, sought medical attention for pain of 10-day progression in the right hypochondrium, associated with bilious vomiting, fever, and general symptoms. The emergency room evaluation revealed fever, abdominal pain, low blood pressure, tachycardia, and hypoxemia. The patient was transferred to the special care unit to begin vasopressor support. Hospital admission laboratory test results reported elevated CRP (27 mg/dl), thrombocytopenia (77,000 mm<sup>3</sup>), elevated creatinine (5.21 mg/dl), and ureic nitrogen of 103.6 mg/dl. There was compromised liver function, with ALT 357 U/l, AST 309 U/l, total bilirubin 3.01 mg/dl, alkaline phosphatase 360 U/l, and metabolic acidemia with hyperlactatemia. An abdominal ultrasound study identified a large 10.05 × 10.21 cm hepatic lesion not suitable for percutaneous drainage due to its apparently dense consistency (Fig. 1A). The patient received support measures and empiric antibiotic treatment, but her clinical

progression did not improve, and she presented with multiple organ failure involving 4 systems: renal, ventilatory, circulatory, and hematologic. Her liver profile tests revealed a cholestatic pattern, and bacteremia due to multidrug resistant *Klebsiella pneumoniae* was also reported. The patient had a score of 16 points on the SOFA and 36 points on the APACHE II sepsis severity scales, predicting high in-hospital mortality.

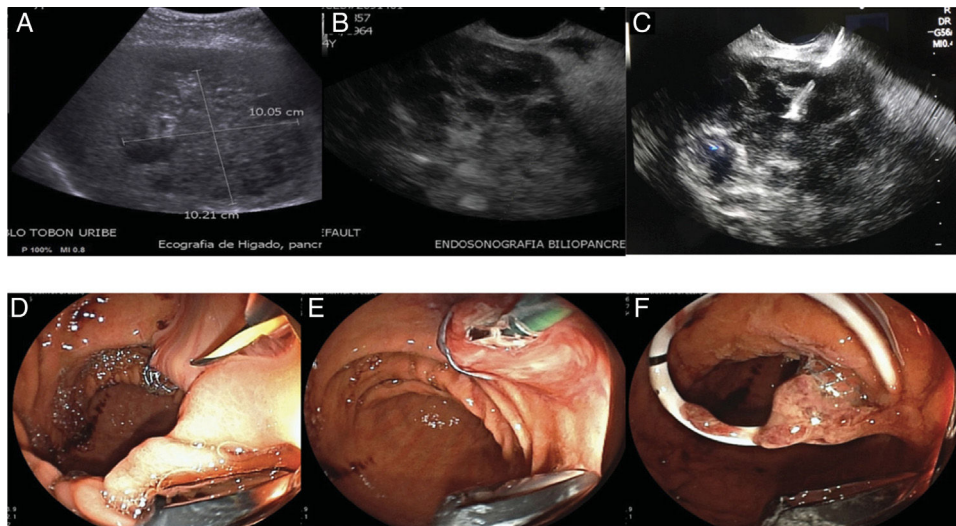
Due to her clinical conditions, the surgical team did not consider the patient to be a candidate for surgical drainage. A hepatic-biliary-pancreatic endosonography study was performed that ruled out choledocholithiasis and confirmed the presence of a dense, heterogeneous liver collection, 10 cm in diameter, located between segments IV-V of the liver that was suitable for endosonography-guided transgastric drainage (Fig. 1B).

The procedure was carried out, with the patient under general anesthesia. The transgastric puncture was performed using a linear echoendoscope with a 19 G (Expect™) needle, obtaining 20 ml of pus that was sent for microbiologic study (Fig. 1C). Contrast medium was then injected to delimit the collection and rule out biliary tract leakage, to then be able to introduce a fluoroscopic and endosonographic guidewire. A 0.035 mm Jagwire hydrophilic guidewire was advanced under fluoroscopic and endosonographic guidance. A Rigiflex 6 Fr cystotome was advanced over the guidewire. Using a 30W cutting current, a tract was created and dilated, and a 10 mm × 60 mm fully covered self-expanding metallic stent was then inserted (Fig. 1D). The most proximal portion of the stent was dilated with an 8 mm CRE balloon to allow the passage of an 8.5 Fr × 7 cm coaxial double-pigtail drain into the metallic stent (Fig. 1E and F). The drainage of abundant, thick pus from the metallic stent was observed. At the end of the procedure, an endoclip was placed to fix the proximal end of the stent to the gastric wall to prevent its migration.

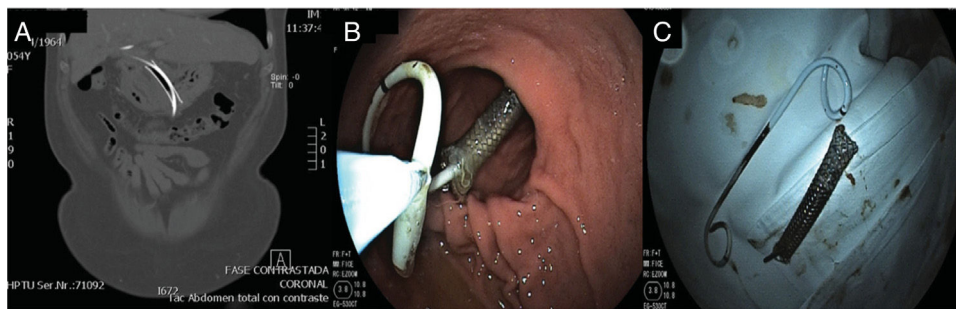
After the drainage, the patient's general status improved rapidly. The inflammatory response decreased and the ventilatory and hemodynamic parameters improved, as did kidney function and coagulation. Two days after the drainage, the vasopressor and ventilatory support was withdrawn. The patient was released one week after the transgastric drainage and she completed oral antibiotic treatment in 4 weeks.

At 3 months, a control abdominal CAT scan showed complete resolution of the abscess and the presence of the metallic stent with the coaxial double-pigtail, which were then endoscopically removed with no complications (Fig. 2).

<sup>☆</sup> Please cite this article as: Carvajal JJ, Betancur Salazar K, Mosquera-Klinger G. Drenaje transgástrico por ultrasonido endoscópico de un absceso hepático en paciente con disfunción multiorgánica. *Revista de Gastroenterología de México.* 2021;86:94–96.



**Figure 1** A) Hepatobiliary ultrasound identifying a liver abscess larger than 10 cm. B) Linear view of the liver abscess, through endoscopic ultrasound. C) Transgastric puncture of the abscess, D) passage of the covered metallic stent, in which drainage of abundant thick purulent material can be seen. E) Dilatation of the proximal end of the stent, F) passage of the coaxial double-pigtail catheter into the metallic stent.



**Figure 2** A) Coronal CAT scan performed 3 months later, showing complete resolution of the abscess and the presence of the stents. B) Endoscopic view of the removal of both stents. C) Plastic double-pigtail stent and metallic stent, after their removal from the patient.

Percutaneous drainage through interventional radiology with concomitant antibiotic treatment has been the conventional approach to liver abscesses.<sup>7</sup> Reported complications range from bleeding, needle tract infection, sepsis, hepatovenous fistula, and discomfort associated with external drainage.<sup>8</sup> There are possible therapeutic limitations regarding both the use of stents with a maximum 12 Fr caliber in very dense abscesses and the passage of the percutaneous stent in cases involving the inferior or left segments of the liver.

Currently, transmural drainage through endoscopic ultrasound is a useful and potentially ideal option in cases of abscesses that involve the left or caudate lobe of the liver due to the fact that the transgastric approach is carried out by direct puncture under real-time vision and vascular complications are prevented through Doppler imaging at the time of the puncture. In addition, different types of metallic stents that are favorable for draining very dense or very large collections (self-expanding stents or lumen-apposing stents that have a large diameter of 10 mm–15 mm [30 Fr–45 Fr]) can be released.<sup>4,9–10</sup>

In conclusion, percutaneous drainage is the treatment of choice in liver abscesses larger than 5 cm, but there could be technical limitations in patients with abscesses in the inferior or left segments of the liver. In addition, when the material of the abscess is very thick, drainage difficulties related to the small diameters of the percutaneous stents can occur. In such a scenario, drainage utilizing endosonography-guided metallic stents can be an adequate, safe, and efficacious option for those patients.

### Financial disclosure

No financial support was received in relation to this article.

### Conflict of interest

The authors declare that there is no conflict of interest.

### References

1. Lardière-Deguelte S, Ragot E, Armoun K, et al. Hepatic abscess: diagnosis and management. *J Visc Surg.* 2015;152:231–43, <http://dx.doi.org/10.1016/j.jviscsurg.2015.01.013>.
2. Lee KT, Wong SR, Sheen PC. Pyogenic liver abscess: an audit of 10 years' experience and analysis of risk factors. *Dig Surg.* 2001;18:459–66.
3. Barakate MS, Stephen MS, Wangh RC, et al. Pyogenic liver abscess: a review of 10 years' experience and management. *Aust N Z J Surg.* 1999;69:205–9.
4. Alcaide N, Vargas-García AL, de la serna-Higuera C, et al. EUS-guided drainage of liver abscess by using a lumen-apposing metal stent (with video). *Gastrointest Endosc.* 2013;78:941–2, <http://dx.doi.org/10.1016/gie.2013.07.034>.
5. Medrano BF, Carneiro FO, Vilaça TG, et al. Endoscopic ultrasound-guided drainage of giant liver abscess. *Endoscopy.* 2013;45:E331–2.
6. Seewald S, Imazu H, Omar S, et al. EUS-guided drainage of hepatic abscess. *Gastrointest Endosc.* 2005;61:495–8.
7. Singhal S, Changela K, Lane D, et al. Endoscopic ultrasound-guided hepatic and perihepatic abscess drainage: an evolving technique. *Therap Adv Gastroenterol.* 2014;7:93–8.
8. Chung YF, Tay KH, Stan B, et al. Percutaneous drainage of liver abscess complicated by hepato-venous fistula. *Singapore Med J.* 2003;44:299–301.
9. Noh SH, Park do DH, Kim YR, et al. EUS-guided drainage of hepatic abscesses not accessible to percutaneous drainage (with videos). *Gastrointest Endosc.* 2010;71:1314–9.
10. Ogura T, Masuda D, Saori O, et al. Clinical outcome of endoscopic ultrasound-guided liver abscess drainage using self-expandable covered metallic stent (with video). *Dig Dis Sci.* 2016;61:303–8, <http://dx.doi.org/10.1007/s10620-015-3841-3>.

J.J. Carvajal<sup>a</sup>, K. Betancur Salazar<sup>b</sup>,  
G. Mosquera-Klinger<sup>a,\*</sup>

<sup>a</sup> *Unidad de Gastroenterología y Endoscopia Digestiva, Hospital Pablo Tobón Uribe, Medellín, Colombia*

<sup>b</sup> *Universidad Pontificia Bolivariana, Medellín, Colombia*

\* Corresponding author at: Hospital Pablo Tobón Uribe, Consultorio 154, Calle 78B # 69-240, Medellín, Colombia. Phone 4459154.

E-mail address: [gami8203@yahoo.com](mailto:gami8203@yahoo.com)  
(G. Mosquera-Klinger).

2255-534X/ © 2020 Asociación Mexicana de Gastroenterología. Published by Masson Doyma México S.A. This is an open access article under the CC BY-NC-ND license (<http://creativecommons.org/licenses/by-nc-nd/4.0/>).

## Successful management through laparoscopic-assisted antegrade enteroscopy of duodenal perforation caused by a wire bristle: A case report<sup>☆</sup>



### Manejo exitoso de perforación duodenal por cerda de alambre mediante enteroscopia anterógrada asistida con laparoscopia: reporte de caso

A large part of the general population commonly uses wire bristle brushes to clean their grills. Said habit can result in the involuntary ingestion of bristles that are adhered to the food being cooked on the surface of the grill. An increase in incidence has been seen over the past 10 years, based on reports in the medical literature and data obtained from the United States Consumer Product Safety Commission.<sup>1,2</sup>

A 45-year-old man, with no known comorbidities, had a history of 2 episodes of colonic diverticulitis 4 years earlier that was treated conservatively. During a tourist trip to Argentina, he presented with postprandial stabbing pain of mild intensity at the level of the left hemiabdomen, with no other associated symptoms. Upon his return to Peru, he presented with the same abdominal pain, which became

permanent and more intense. Three days later, he sought medical attention at the emergency service. Physical examination found the patient hemodynamically stable with no significant alterations. Laboratory test results were normal for the complete blood count and C-reactive protein, and an abdominal ultrasound did not aid in making a diagnosis. An abdominal tomography scan revealed the presence of an image at the level of the small bowel that was suggestive of a radio-opaque foreign body. It measured 2.50 cm in length, had pointed ends, and was embedded in the intestinal wall. An inflammatory mass was also observed at the level of the proximal jejunum (Fig. 1).

The patient immediately underwent a simple balloon-assisted antegrade enteroscopy, with laparoscopic support, that identified a wire bristle embedded in the fourth part of the duodenum. It was extracted using a biopsy forceps and the sheath of the enteroscope (Fig. 1). No type of additional surgical and/or endoscopic procedure was needed, and the 2.50 cm-long wire bristle from a brush used for cleaning grills was successfully retrieved (Fig. 2). The patient had favorable progression, with complete symptom resolution.

There are currently few studies that demonstrate the epidemiology of lesions caused by the unusual foreign body described herein.<sup>1,2</sup> One of the most representative was the study by Baugh et al.<sup>3</sup> that found a total of 43 cases in the National Electronic Injury Surveillance System database, over a 12-year period. Extrapolated to the national level, they resulted in a total of 1698 lesions registered at emergency services. The most common site of injury was the oropharynx, with 53.4% of cases (23/43), coinciding with the 30.5% (11/36) reported in the international literature, whereas the oral cavity was the predominant site found in the US Consumer Product Safety Commission database, at

<sup>☆</sup> Please cite this article as: Cedrón Cheng H, Aliaga Ramos J, Camacho Zacarias F. Manejo exitoso de perforación duodenal por cerda de alambre mediante enteroscopia anterógrada asistida con laparoscopia: reporte de caso. *Revista de Gastroenterología de México.* 2021;86:96–98.