

Laparoscopic-endoscopic transgastric (intraluminal) resection of subepithelial lesions in the cardia. A case series[☆]



Resección laparoscópica-endoscópica transgástrica (intraluminal) de lesiones subepiteliales cardiales. Serie de casos

About one-fifth of gastric subepithelial lesions (SLs) are leiomyomas.¹ Those located in the cardia or proximal to the esophagogastric junction (EGJ) are surgically demanding and associated with risks for stricture, leaks, or postoperative physiologic alterations. Many of those lesions can currently be resected through endoscopic submucosal dissection (ESD), a technique begun in Asia and subsequently carried out in the rest of the world. In Latin America, the experience with said procedure is still developing. The morbidity rate associated with SL resection using ESD ranges from 6.7 to 55.4% and includes bleeding, perforations, subcutaneous emphysema, pneumomediastinum, and fistulas secondary to failed closure of incised layers.² Likewise, the manipulation of lesions greater than 40 mm can be complex and result in incomplete resections.^{3,4} The combination of flexible videoendoscopy (FVE) and transgastric intraluminal laparoscopy (TGIL) is a therapeutic alternative and a strategy of special interest for the treatment of gastric SLs.

We describe herein the technique employed and evaluated the results of the resection of the SLs in the cardia, in three patients operated on within the time frame of June 2012 and October 2017. Variables were expressed in absolute values. The arithmetic mean and range of the continuous variables were calculated, and the categorical variables were expressed as frequencies. The preoperative clinical evaluation, gastrointestinal videoendoscopy, triphasic abdominal CT, endoscopic ultrasound, and fine-needle aspiration cytology (FNAC) were included. The cytology results were consistent with leiomyomas in cases 2 and 3. [Table 1](#) shows the characteristics of each patient. Other isolated factors that prompted the surgical indication were the diagnostic doubt in the FNAC, which could not be repeated due to cost (case 1), and the insistence of the patients on the resection of a "tumor" lesion in a "difficult" location, given the possibility of growth, which was a decision supported by the treating gastroenterologist.

Under general anesthesia, we placed three abdominal ports and carried out exploratory laparoscopy. We endoscopically verified the location of the lesions, fixed the stomach to the abdominal wall with suture threads, and under endoscopic control, through transillumination, we introduced the transgastric trocars, avoiding the vessels of the stomach wall. Using diathermia in the dissection, we extracted the lesions through the mouth and sutured the mucosa with syn-

thetic absorbable suture. Upon finishing, we performed a pneumatic test and endoscopically and laparoscopically verified the closure of the gastric ports. All the lesions had endophytic growth and the immunohistochemistry result was consistent with leiomyomas (positive Caldesmon antibodies and actin) ([Fig. 1](#)). Surgery duration was a mean 131.6 minutes, with blood loss of 16.6 cc. One case presented with an adverse event ([Table 1](#)). The postoperative esophagrams ruled out leaks, oral diet was then begun, and the patients were released from the hospital. There were no early or late postoperative complications and the mean follow-up period was 57 months.

Minimal access surgical approaches have been adapted to the location and characteristics of each organ and particular type of lesion. Different groups have employed FVE and TGIL, offering additional benefits to those of surgical or totally endoscopic resections,⁵ especially in large lesions, those located in the cardia, lesser curvature, or antrum, or those in the deep layers of the stomach wall.⁶ The technique is also a therapeutic alternative in centers, such as ours, with little experience in third space endoscopy. The combination of the two approaches aids in increasing the surgeon's perspective, by having a simultaneous internal and external view of the organ. Triangulation of the laparoscopic instruments inside the gastric lumen enables the dissection and resection maneuvers to be controlled, providing safety during the suturing of the defects, with vessel sealing or closure with clips, sutures, or autosutures carried out in the same manner. Possible perforation or bleeding can also be treated through laparoscopy or endoscopy.

According to Ntourakis and Mavrogenis,⁵ the cooperative use of endoscopy and laparoscopy is grouped into three categories, depending on their roles: a) laparoscopic-assisted endoscopic resection, b) endoscopic-assisted laparoscopic resection, and c) combined laparoscopic-endoscopic resection. The procedure performed on our patients falls under the second category. Said technique was first described by Ohashi,⁷ in which the number of transgastric laparoscopic ports can vary, employing a single port, or combining FVE with the use of a robot, thus achieving additional benefits to those of robotic surgery. In our patients, the combination of FVE and TGIL was an efficacious and safe strategy for the resection of SLs in the cardia. The combined use of the two procedures potentiated the advantages of their individual use.

Ethical considerations




The surgical procedure was explained to each of the patients. We obtained informed consent for both the surgical act and the publication of images (those documents are in the possession of the corresponding author), following the protocols of our work center on the publication of patient data, preserving their anonymity. We declare that no experiments on humans were conducted.

Financial disclosure

No financial support was received in relation to this article.

[☆] Please cite this article as: Pereira Graterol F, Salazar Marcano F, Venales Barrios Y, Caceres Cauro A. Resección laparoscópica-endoscópica transgástrica (intraluminal) de lesiones subepiteliales cardiales. Serie de casos. *Revista de Gastroenterología de México*. 2021;86:202-205.

Table 1 Case series of patients with laparoscopic-endoscopic resection of subepithelial lesions in the cardia. Clinical characteristics, extension study findings, and postoperative results.

Patient	Sex/age	BMI (kg/m ²)	Endoscopic ultrasound	Surgical indication	Additional procedures	Diagram of lesion location	Surgery duration	Blood loss	Intraoperative adverse events	Follow-up (months)
1	Male	31	Subepithelial lesion.	Diagnostic doubt in FNAC (no possibility of repetition)	Laparoscopic cholecystectomy	Hour 5	160 min	25 cc	No	80
	45 years		Origin: muscularis propria, 20 mm. Not affecting the submucosa or serosa		Umbilical hernioplasty	≤ 1 cm from EGJ 				
2	Female	36	Calcified mesenchymal lesion.	Double the size of the lesion (last year of follow-up)	No	Hour 9	90 min	5 cc	Hematoma in the gastric lesser curvature (self-limited)	75
	58 years		Origin: muscularis propria, 19 mm			2 cm from EGJ 				
3	Female	29	Submucosal lesion.	Dysphagia.	Endoscopic removal of pancreatic stent	Hour 3	145 min	20 cc	No	16
	53 years		Origin: Muscularis propria, with area of necrosis in its interior, 40 × 20 mm Extension: up to the serosa (without infiltrating it)	Size of the lesion		On the EGJ 				

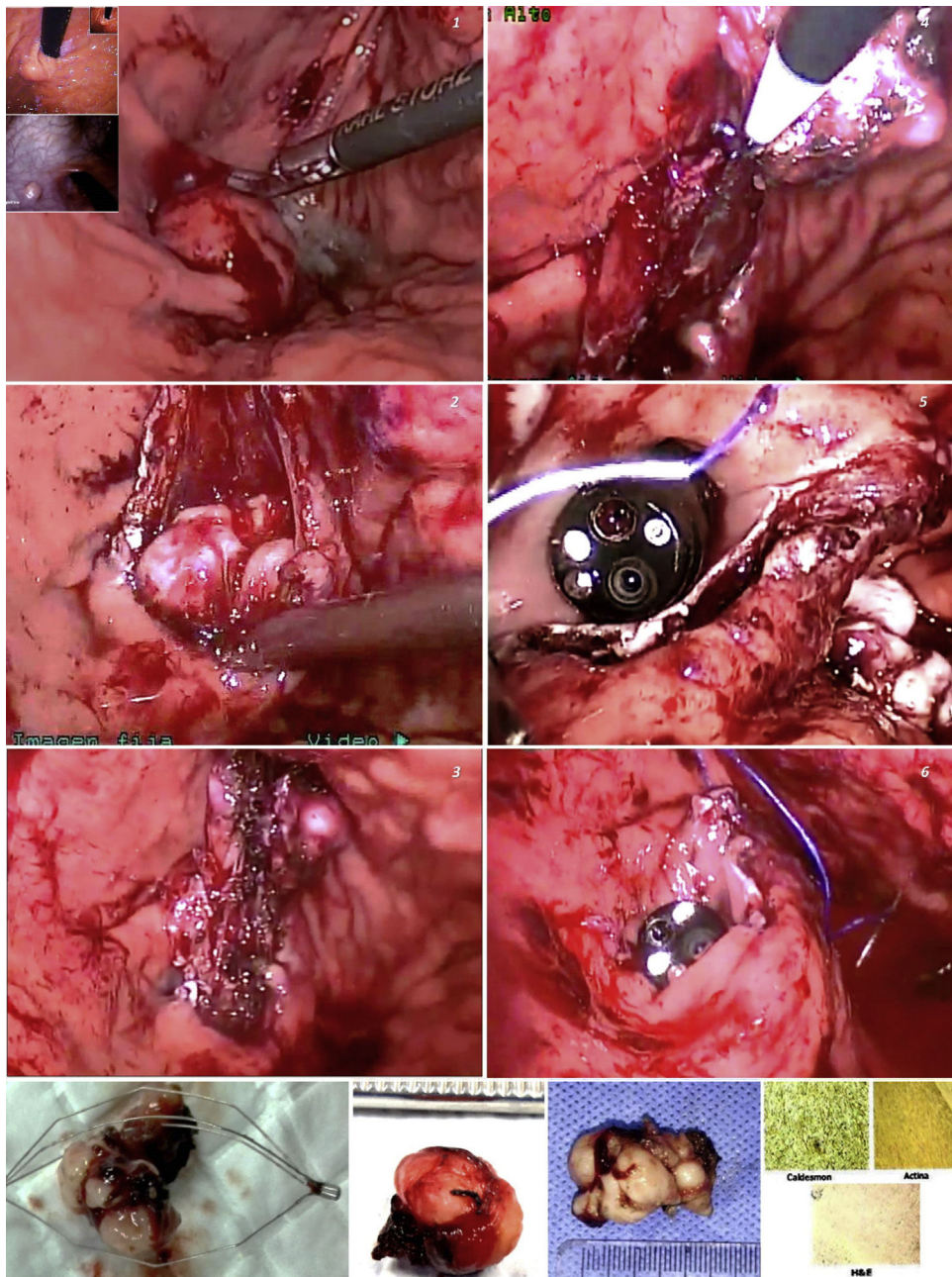


Figure 1 A) Resection of subepithelial lesions of the cardia employing laparoscopic-endoscopic transgastric intraluminal surgery (1-6). B) Extracted lesions and immunohistochemistry.

Conflict of interest

The authors declare that there is no conflict of interest.?

References

1. Barajas-Gamboa JS, Acosta G, Savides TJ, et al. Laparo-endoscopic transgastric resection of gastric submucosal tumors. *Surg Endosc*. 2015;29:2149–57, <http://dx.doi.org/10.1007/s00464-014-3910-2>.
2. Peng W, Tan S, Huang S, et al. Efficacy and safety of submucosal tunneling endoscopic resection for upper gastrointestinal submucosal tumors with more than 1-year follow-up: a systematic review and meta-analysis. *Scand J Gastroenterol*. 2019;54:397–406, <http://dx.doi.org/10.1080/00365521.2019.1591500>.
3. Dellatore P, Bhagat V, Kahaleh M. Endoscopic full thickness resection versus submucosal tunneling endoscopic resection for removal of submucosal tumors: a review article. *Transl Gastroenterol Hepatol*. 2019;4:45.
4. ASGE Technology Committee, Aslanian HR, Sethi A, et al. ASGE guideline for endoscopic full-thickness resection and submucosal tunnel endoscopic resection. *VideoGIE*. 2019;4:343–50, <http://dx.doi.org/10.1016/j.vgje.2019.03.010>.

5. Ntourakis D, Mavrogenis G. Cooperative laparoscopic endoscopic and hybrid laparoscopic surgery for upper gastrointestinal tumors: current status. *World J Gastroenterol.* 2015;21:12482–97, <http://dx.doi.org/10.3748/wjg.v21.i43.12482>.
6. Balde AI, Chen T, Hu Y, et al. Safety analysis of laparoscopic endoscopic cooperative surgery versus endoscopic submucosal dissection for selected gastric gastrointestinal stromal tumors: a propensity score-matched study. *Surg Endosc.* 2017;31:843–51, <http://dx.doi.org/10.1007/s00464-016-5042-3>.
7. Ohashi S. Laparoscopic intraluminal (intra-gastric) surgery for early gastric cancer. A new concept in laparoscopic surgery. *Surg Endosc.* 1995;9:169–71, <http://dx.doi.org/10.1007/BF00191960>.

F. Pereira Graterol^{a,*}, F. Salazar Marcano^a,
Y. Venales Barrios^a, A. Caceres Cauro^b

^a *Unidad de Cirugía de Mínimo Acceso y Servicio de Cirugía General, Hospital Universitario Dr. Luis Razetti, Barcelona, Venezuela*

^b *Centro de Investigaciones en Ciencias de la Salud (CICS), Núcleo de Anzoátegui, Universidad de Oriente, Barcelona, Venezuela*

* Corresponding author. Day Hospital # 5. Av. Principal de Lechería, Edo. Anzoátegui CP: 6016, Venezuela. Tel.: +58 4166138797.

E-mail address: freddypereiragraterol@gmail.com
(F. Pereira Graterol()).

2255-534X/ © 2020 Asociación Mexicana de Gastroenterología. Published by Masson Doyma México S.A. This is an open access article under the CC BY-NC-ND license (<http://creativecommons.org/licenses/by-nc-nd/4.0/>).

Rumination syndrome and gastroparesis: Linked entities?☆



Síndrome de rumiación y gastroparesia: ¿entidades ligadas?

Rumination syndrome (RS) is a functional gastrointestinal disorder characterized by effortless and repetitive regurgitation of ingested food from the stomach to the oral cavity, followed by either re-swallowing or spitting.¹ It is produced by an increase in the intragastric pressure that is generated by a voluntary, unintentional contraction of the abdominal wall.¹ RS appears to be underdiagnosed due to a lack of awareness among physicians, and it may be more common in females.² It was first described in association with impaired mental development, more in children than in adults,³ but is now recognized as a distinct clinical entity unrelated to mental status or age. Most patients have symptoms within 10 min of finishing a meal.² Regurgitation is the most common symptom, which is why gastroesophageal reflux disease (GERD) is the main differential diagnosis. Reflux is often described as tasting like the recently ingested food. Overt pain is not often described, but postprandial symptoms, such as dyspepsia, have been reported in up to 50% of patients.² Weight loss has been observed in approximately 40% of patients, but complications such as electrolyte disturbances and malnutrition are much less common.² Patients are often discouraged by prolonged symptoms with no improvement after GERD therapy. The diagnosis of RS in adults is based on the ROME IV criteria. Although clinical suspicion is important, postprandial esophageal high-resolution impedance manometry (HRIM) supports the diagnosis. It shows gastric pressurizations exceeding 30 mmHg that are associated with simultaneous upper and lower esophageal relaxation that is apparently closely related to the return of the

ingested material into the esophagus and mouth, as well as to patient symptoms.¹ Variants of rumination have been identified and can be differentiated by specific patterns.⁴ Increase in intragastric pressure followed by regurgitation is the most important characteristic distinguishing rumination from other disorders, such as gastroesophageal reflux. Treatment should be interdisciplinary and based on 3 points: an explanation of the condition and its underlying mechanism, diaphragmatic breathing, and visual feedback on the electromyogram (EMG) activity of the relevant muscles. Regarding the pharmacologic approach, drugs that affect the lower esophageal sphincter (LES) resting tone and suppress transient LES relaxations, such as baclofen and a GABA-B agonist, could potentially have a therapeutic role. Finally, fundoplication has been suggested for refractory cases.⁵

Gastroparesis is characterized by delayed gastric emptying in the absence of mechanical obstruction. Nausea and vomiting are the classic symptoms.⁶ The pathogenesis may result from autonomic neuropathy, affecting excitatory and inhibitory intrinsic nerves or the interstitial cells of Cajal, or from myopathic diseases. The most common causes are neuropathic disorders such as diabetes, post-vagotomy surgery, and connective tissue diseases like scleroderma.⁷ When the pathology is not justified by a systemic disease, it is called “idiopathic gastroparesis”. The mainstays of treatment are restoration of hydration, electrolytes, and nutrition, and pharmacologic treatment with prokinetics and antiemetics. In more severe cases, enteral feeding, percutaneous gastrostomy for draining the stomach, or gastric electrical stimulation may be considered. More recently, gastric peroral endoscopic pyloromyotomy has emerged as a novel endoscopic technique to treat refractory gastroparesis.⁸

We present herein a 31-year-old female patient with long-term postprandial regurgitation and early satiety for more than 2 years. She had several previous hospitalizations with enteral feeding requirements due to malnutrition. The patient had no history of eating disorders, but her family environment was conflictive. Complementary studies (brain CT and MRI, esophageal barium swallow, intesti-

☆ Please cite this article as: Argüero J, Cano-Busnelli V, Cavadas D, Marcolongo M. Síndrome de rumiación y gastroparesia: ¿entidades ligadas? *Revista de Gastroenterología de México.* 2021;86:205–207.