



## SCIENTIFIC LETTER

### Tri-luminal septate appendix: A morphologic variant of septa with *muscularis propria*<sup>☆</sup>



#### Apéndice triluminal septado: una variante morfológica de septo con *muscularis propria*

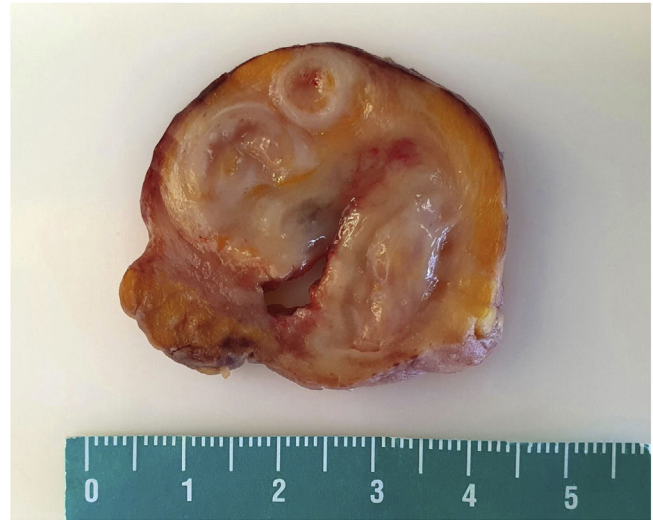
Appendiceal malformations are extremely rare and they are usually an incidental finding.<sup>1</sup> Septate appendices have only been described in one case series that reported on 25 cases of appendices with submucosal septa, with no *muscularis propria*.<sup>2</sup> We present herein the first case of septate appendix, with each lumina separated by *muscularis propria*.

A 15-year-old male, with no significant past medical history, arrived at the emergency room with chest and abdominal pain of 12-h progression that migrated to the right lower quadrant, fever, tachycardia, and positive appendiceal signs. Laboratory tests revealed leukocytosis and computed tomography (CT) identified an appendix measuring 31 mm in diameter, with a fecalith, for which he underwent laparoscopic appendectomy. A solid appendiceal-dependent tumor-like mass surrounded by fatty tissue was completely removed with no surgical complications and sent for pathologic analysis.

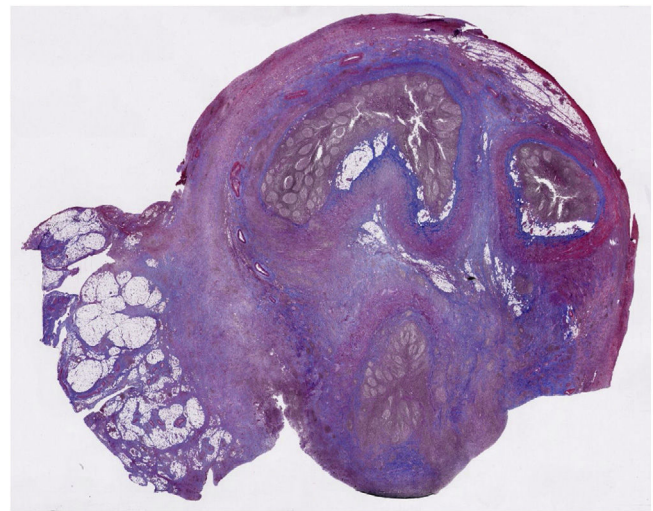
Upon gross examination, the mass measured 6 cm in length and 4 cm in diameter, with an irregular nodular surface. Longitudinal sections revealed a heterogeneous appearance with multiple lumina, the widest measuring 1.1 cm in diameter, with a thickened whitish-yellow wall between them (Fig. 1). The entire specimen was submitted for histologic evaluation.

Upon microscopic examination, the “tumor” was recognized to be a tri-luminal appendix. Each lumen was surrounded by normal appendiceal mucosa and separated from each other by septa composed of submucosa and *muscularis propria* layers (Fig. 2). There was marked acute appendicitis and periappendicitis.

The patient had no complications at the one-month follow-up.



**Figure 1** Gross appearance of the mass with multiple lumina.



**Figure 2** Tri-luminal appendix with complete septa of the submucosa and *muscularis propria*. Smooth muscle is highlighted in red. (Masson's trichrome stain,  $\times 0.5$ ).

<sup>☆</sup> Please cite this article as: Sánchez NG, Estrada-Ortiz FA, Peñarrieta-Daheer AA, Padilla-Rodríguez AL. Apéndice triluminal septado: una variante morfológica de septo con *muscularis propria*. Rev Gastroenterol Méx. 2023;88:289–290.

Appendiceal developmental anomalies are extremely rare and most are diagnosed incidentally during surgery for acute appendicitis or upon post-mortem examination. Their presence can affect the preoperative diagnosis and surgical treatment.<sup>3</sup>

Appendiceal malformations in descending frequency include appendicular diverticulosis (0.8%),<sup>4</sup> duplication of the appendix (0.004%),<sup>5</sup> bifid appendix (fewer than 80 reported cases),<sup>6</sup> appendicular atresia (one in 100,000 cases),<sup>3,7</sup> and other rare abnormalities, such as horseshoe appendix<sup>8</sup> and triplication of the appendix,<sup>9</sup> with a rare variant described by its authors as a triple-barreled appendix showing three lumina arising from a common base.<sup>10</sup>

Appendiceal septa are single or multiple perpendicular submucosal prolongations that can completely or incompletely divide the lumina. De la Fuente et al.<sup>2</sup> are the authors of the only report on the theme, describing 25 cases. In their case series, all the septa presented in patients under 30 years of age, with strong male predominance (male:female ratio of 3:1), and were incidental findings after appendectomy performed for acute appendicitis.

Our patient presented with symptoms suggestive of acute appendicitis. The intraoperative diagnosis was appendiceal tumor due to its large size and firm consistency, and it was sent for histopathologic examination as such. Upon gross examination, the mass did not appear to be neoplastic, but its tri-luminal appearance was striking, suggesting an unexpected appendiceal malformation. Upon microscopic examination, the three lumina were lined by appendicular mucosa, separated from each other by complete septa of the submucosa and *muscularis propria*, all surrounded by a common serosa.

Unlike conventional appendiceal septa,<sup>2</sup> our case contained true smooth muscle, in addition to the submucosal component of the septa. This previously undescribed condition caused the division of the appendix into multiple lumina, resulting in chronic obstruction that finally led to acute inflammation. Its clinical presentation was that of classic acute appendicitis, resembling a neoplastic process.

Appendiceal septa are mainly made up of submucosa, but they can also consist of *muscularis propria* as a variant of appendicular malformations. Because treatment is appendectomy and the clinical presentation is that of acute appendicitis, many cases can be overlooked. Given the potential diagnostic pitfalls and treatment errors, it is very important for surgeons and pathologists to recognize rare morphologic variants, such as the one presented herein.

## Ethical considerations

The authors declare that this article contains no personal information that enables patient identification, fully preserving patient anonymity. Informed consent was obtained from the patient's parents.

## Financial disclosure

No financial support was received in relation to this article.

## Conflict of interest

The authors declare that there is no conflict of interest.

## References

1. Noffsinger AE. Fenoglio-Preiser's Gastrointestinal Pathology. 4th ed. Wolters Kluwer; 2017. p. 1264.
2. de la Fuente AA. Septa in the appendix: a previously undescribed condition. *Histopathology*. 1985;9:1329–37, <http://dx.doi.org/10.1111/j.1365-2559.1985.tb02814.x>.
3. Masood I, Majid Z, Rafiq A, et al. Appendicitis with appendicular atresia: a rare presentation. *Pan Afr Med J*. 2015;20:57, <http://dx.doi.org/10.11604/pamj.2015.20.57.4500>.
4. Käser SA, Willi N, Maurer CA. Prevalence and clinical implications of diverticulosis of the vermiform appendix. *J Int Med Res*. 2013;41:1350–6, <http://dx.doi.org/10.1177/0300060513487651>.
5. Collins DC. A study of 50,000 specimens of the human vermiform appendix. *Surg Gynecol Obstet*. 1995;101:437–45.
6. Griffiths EA, Jagadeesan J, Fasih T, et al. Bifid vermiform appendix: a case report. *Curr Surg*. 2006;63:176–8, <http://dx.doi.org/10.1016/j.cursur.2006.02.001>.
7. Collins DC. Agenesis of the vermiform appendix. *Am J Surg*. 1951;82:689–96, [http://dx.doi.org/10.1016/0002-9610\(51\)90391-1](http://dx.doi.org/10.1016/0002-9610(51)90391-1).
8. Serter I, Eroglu E, Akbal E, et al. Horseshoe appendix is an extremely rare cause of acute appendicitis. *Am Surg*. 2018;84:490–1.
9. Tolatti J, Pereira-Graterol F, Salazar F, et al. TriPLICATION of the Vermiform Appendix: a Variation of the Cave–Wallbridge Classification? *Cir Esp (Engl Ed)*. 2020;98:159, <http://dx.doi.org/10.1016/j.ciresp.2019.04.011>.
10. UrieV L, Maslovsky I, Mnouskin Y, et al. Triple-barreled type of appendiceal triplication. *Ann Diagn Pathol*. 2006;10:160–1, <http://dx.doi.org/10.1016/j.anndiagpath.2005.09.016>.

N.G. Sánchez<sup>a</sup>, F.A. Estrada-Ortiz<sup>b</sup>,  
A.A. Peñarrieta-Daher<sup>c</sup>, A.L. Padilla-Rodríguez<sup>d,\*</sup>

<sup>a</sup> DIGIPATH: Digital Pathology Laboratory, Instituto Tecnológico y de Estudios Superiores de Monterrey Campus Ciudad de México, Mexico City, Mexico

<sup>b</sup> Instituto Tecnológico y de Estudios Superiores de Monterrey Campus Ciudad de México, Mexico City, Mexico

<sup>c</sup> Hospital Infantil de México Federico Gómez, Star Médica Hospital Infantil Privado, Mexico City, Mexico

<sup>d</sup> DIGIPATH: Digital Pathology Laboratory, Escuela de Medicina Universidad Panamericana Campus Ciudad de México, Escuela de Medicina Instituto Tecnológico y de Estudios Superiores de Monterrey Campus Ciudad de México, Mexico City, Mexico

\* Corresponding author at. Tepic 139, Col. Roma Sur, C.P. 06760, CDMX, Mexico. Tel.: 5559415457.

E-mail address: [apadilla@digipath.mx](mailto:apadilla@digipath.mx)  
(A.L. Padilla-Rodríguez).

2255-534X/ © 2023 Asociación Mexicana de Gastroenterología. Published by Masson Doyma México S.A. This is an open access article under the CC BY-NC-ND license (<http://creativecommons.org/licenses/by-nc-nd/4.0/>).