



Identified factors for developing recurrent acute pancreatitis and chronic pancreatitis: Genetic etiology should be considered. Report on cases in Mexican children[☆]

Factores identificados para desarrollar pancreatitis aguda recurrente y pancreatitis crónica: debemos considerar la etiología genética. Reporte de casos en niños mexicanos

Cases of recurrent acute pancreatitis (RAP) and chronic pancreatitis (CP) in children have increased in recent years. RAP is characterized by two or more documented events of acute pancreatitis (AP) and occurs in 10-30% of cases of AP. CP is the end stage of progressive inflammation that manifests as fibrosis of the pancreatic parenchyma that eventually leads to exocrine and/or endocrine dysfunction.^{1,2}

In children, there is usually more than one identified factor that contributes to its development and they are related to a broad range of etiologies (genetic, anatomic, obstructive, pharmacotoxic, traumatic, metabolic [inborn errors of metabolism], systemic, infectious, autoimmune, and idiopathic).³ Said conditions are related to morbidities, emergency room admissions, and hospitalizations.⁴

We describe herein 6 patients with RAP and 5 with CP, in whom the identified risk factors in the development of RAP and CP, proposed by the INSPPIRE group,^{5,6} were studied. Massive sequencing was carried out using the Illumina®

platform. The characteristics of the RAP and CP cases are described in Tables 1 and 2, respectively. The risk factors for developing both RAP and CP are similar and genetic causes have been identified in > 50% of the cases of RAP and in ~75% of the cases of CP, with 17% of cases having more than one pathogenic variant, according to the INSPPIRE report.^{3,5}

The median age at the time of diagnosis was 8 years (interquartile range [IQR] 5-12), the median number of emergency room visits prior to diagnosis was 3 (IQR 2-5), and the median number of hospitalizations in the past year was 2 (IQR 0-2).

In a recent study on 479 children, demographic variables, risk factors, and treatment in RAP and CP were evaluated, and genetic variants were identified as the dominant risk factor.⁷ In our report, we documented a genetic variant in 45.4% of cases, a higher percentage than that reported by Saito et al. (39.1%).⁸ In the study by Vue et al., in which 33% (n = 30/91) of the patients were Hispanic, 36% of the 91 cases had at least one mutation.¹

In a case series on 115 children that included 20 with RAP (17%), 16 of them underwent genetic testing. In 6 of those patients, one pathogenic variant was found in one of the 4 gene panels (*PRSS1* [cationic trypsinogen], *SPINK1* [serine protease inhibitor Kazal type 1], *CFTR* [cystic fibrosis transmembrane conductance regulator], and *CTRC* [chymotrypsin C]); *CFTR* was the most frequently found genetic variant, followed by *PRSS1* and *SPINK1*.⁹ The difference from our findings was likely due to our small sample size and the higher prevalence of the *CFTR* mutation that is found in the White population. In the Mexican population, in a total of 55 patients (65.5% with AP; 34.5% with RAP), Sánchez-Ramírez et al. identified a frequency of 1.8% for the pathogenic vari-

Table 1 Clinical characteristics, identified factors, and radiologic findings in the recurrent acute pancreatitis group.

Patient	BMI	Identified factor	Age (years) at onset of symptoms	Age (years) at diagnosis	Family history
1, M	97	Genetic (<i>PRSS1</i> pathogenic variant)	3	3	Pancreatitis (brother)
2, F	35	Obstructive (cholelithiasis)	6	6	-
3, F	52	Metabolic (hypertriglyceridemia)	8	8	-
4, M	26	Idiopathic	9	12	-
5, F	92	Obstructive (microlithiasis)	4	5	-
6, M	40	Metabolic (hypercalcemia/primary hyperparathyroidism)	13	13	Pancreatitis (maternal aunt and grandmother)

BMI: body mass index expressed in percentiles by the Centers for Disease Control and Prevention; F: female; M: male; *PRSS1*: cationic trypsinogen.

[☆] Please cite this article as: Macías-Flores JA, Rivera-Suazo Y, Mejía-Marin LJ. Factores identificados para desarrollar pancreatitis aguda recurrente y pancreatitis crónica: debemos considerar la etiología genética. Reporte de casos en niños mexicanos. Rev Gastroenterol Méx. 2023;88:296-299.

Table 2 Clinical characteristics, identified factors, and radiologic findings in the chronic pancreatitis group.

Patient	BMI	Identified factor	Age (years), at symptom onset	Age (years) at diagnosis	Family history	Imaging findings	EPIx	EPI _n
1, M	8	Genetic (<i>PRSS1</i> pathogenic variant)	12	12	RAP (brother)	Calcification	-	+
2, M	4	Genetic (<i>CFTR</i> + <i>PRSS1</i> pathogenic variants)	6	7	Type I diabetes mellitus (father and maternal grand-mother)	Main pancreatic duct dilation	+	-
3, F	10	Genetic (<i>PRSS1</i> pathogenic variant)	10	11	-	Calcification and fibrosis in biopsy	+	-
4, F	7	Genetic (<i>PRSS1</i> pathogenic variant)	5	5	-	Calcification	+	-
5, M	94	Idiopathic	12	13	-	Calcification	+	-

BMI: body mass index expressed in percentiles of Centers for Disease Control and Prevention; *CFTR*: cystic fibrosis transmembrane conductance regulator; EPI_n: endocrine pancreatic insufficiency; EPI_x: exocrine pancreatic insufficiency; F: female; M: male; *PRSS1*: cationic trypsinogen; RAP: recurrent acute pancreatitis.

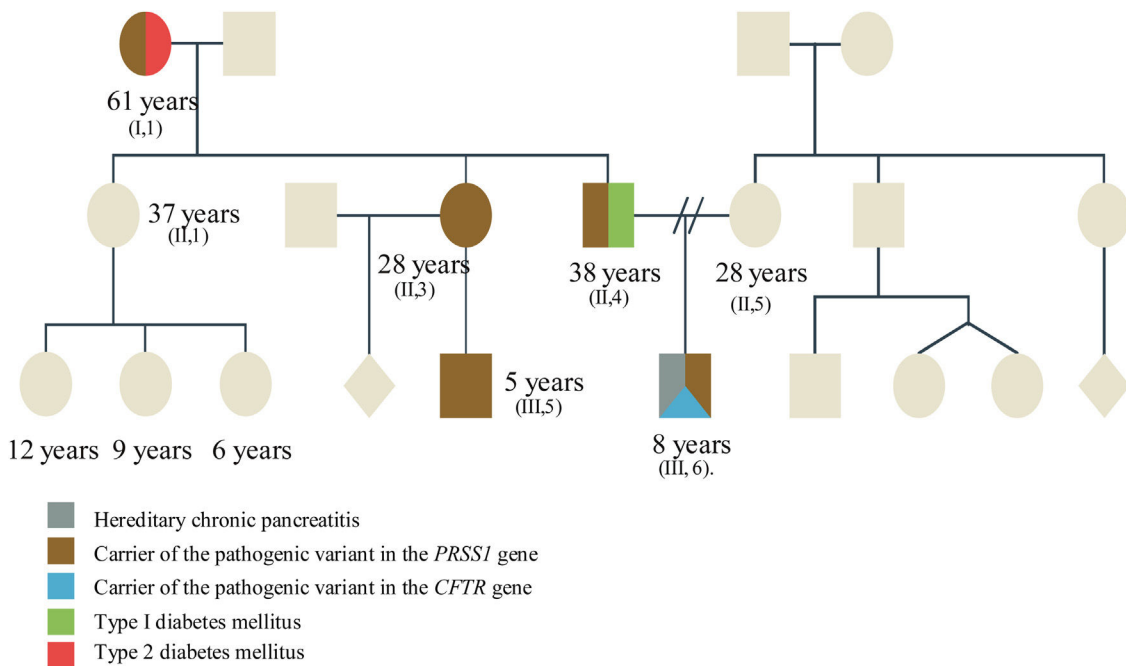


Figure 1 The relatives with manifestations of type I diabetes mellitus and pancreatitis are described, as well as asymptomatic relatives. The patient presents with torpid progression by being a carrier, not only of the duplication in the *PRSS1* gene, but also of a heterozygous variant in the *CFTR* gene, thus a torpid expression and progression is expected.

ant in the *CFTR* gene, corresponding to one patient in the RAP subgroup. However, none of the children were studied for variants in the *PRSS1* or *SPINK1* genes, and no cases of CP were included.¹⁰

Four of our 5 patients with CP presented with heterozygous pathogenic variants in the *PRSS1* gene (complete duplication of the coding region) and one patient pre-

sented with 2 heterozygous pathogenic variants (*CFTR* [p.Phe508del] and *PRSS1* [complete duplication of the coding region]). In that sense, the presence of certain pathogenic variants in the *PRSS1* gene (p.N29I or R122H) has been related to a greater probability of a progressive disease that evolves into CP, and later, even into pancreatic cancer.¹¹ Fig. 1 illustrates how a variant can be inherited in

a family and expressed in distinct forms. Strikingly, all the patients analyzed presented with the same pathogenic variant in the *PRSS1* gene, leading us to suspect they could have had a common ancestor.

A positive family history for pancreatitis has been described to be more frequent in patients with pathogenic variants and 30% of patients with RAP or CP have a family history of pancreatitis, similar to our finding of 27.2%.^{1,7}

We found 2 patients (RAP subgroup) with an obstructive factor. In a study on adult patients with RAP, Saraswat et al. reported that 75% of the microscopic studies of the gallbladder revealed cholesterol crystals and calcium bilirubinate granules associated with microlithiasis. Thirty months after microlithiasis treatment (ursodeoxycholic acid, sphincterotomy, or cholecystectomy), the patients were asymptomatic.¹²

In pediatrics, the metabolic risk factors for RAP and CP are related to diabetic ketoacidosis, hypertriglyceridemia, hypercalcemia associated with hyperparathyroidism, and less frequently, to inborn errors of metabolism.¹³ We found that 2 patients with RAP presented with a metabolic factor: one patient had hypertriglyceridemia (levels > 1,000 mg/dl). Serum levels > 1,000 mg/dl are an absolute risk factor for the development of AP. One of our patients presented with parathyroid adenoma, which is the most common cause of hypercalcemia (> 10.7 mg/dl).¹⁴

Patients with a metabolic factor had a later mean age at presentation than the patients with RAP and no metabolic factor (10.5 vs. 7.16 years), a finding similar to that reported by Husain et al.¹⁴

Pediatric patients with symptoms of pancreatitis do not always undergo an extensive diagnostic evaluation. Therefore, we must promote a proactive position from the time of RAP diagnosis, emphasizing and prioritizing genetic testing.

We recommend that pediatric patients with no identifiable etiology of pancreatitis undergo genetic counseling, given that early typing of the risk factors could improve the therapeutic focus.^{9,13}

Ethical considerations

The authors declare they reviewed the clinical records to collect the data and that they were handled confidentially so that no patient could be individually identified. Neither authorization by the Ethics Committee nor signed statements of informed consent were required.

Financial disclosure

No specific grants were received from public sector agencies, the business sector, or non-profit organizations in relation to this article.

Conflict of interest

The authors declare that there is no conflict of interest.

References

1. Vue PM, McFann K, Narkewicz MR. Genetic mutations in pediatric pancreatitis. *Pancreas*. 2016;45:992–6, <http://dx.doi.org/10.1097/MPA.0000000000000589>.
2. Ellery KM, Uc A. Recurrent pancreatitis in children: past, present, and future. *J Pediatr Gastroenterol Nutr*. 2020;70:413–6, <http://dx.doi.org/10.1097/MPG.0000000000002619>.
3. Uc A, Husain SZ. Pancreatitis in children. *Gastroenterology*. 2019;156:1969–78, <http://dx.doi.org/10.1053/j.gastro.2018.12.043>.
4. Sellers ZM, Maclsaac D, Yu H, et al. Nationwide trends in acute and chronic pancreatitis among privately insured children and non-elderly adults in the United States, 2007-2014. *Gastroenterology*. 2018;155:469–78, <http://dx.doi.org/10.1053/j.gastro.2018.04.013>.
5. Kumar S, Ooi CY, Werlin S, et al. Risk factors associated with pediatric acute recurrent and chronic pancreatitis: lessons from INSPPIRE. *JAMA Pediatr*. 2016;170:562–9, <http://dx.doi.org/10.1001/jamapediatrics.2015.4955>.
6. Liu QY, Abu-El-Haija M, Husain SZ, et al. Risk factors for rapid progression from acute recurrent to chronic pancreatitis in children: report from INSPPIRE. *J Pediatr Gastroenterol Nutr*. 2019;69:206–11, <http://dx.doi.org/10.1097/MPG.0000000000002405>.
7. Dike CR, Zimmerman B, Zheng Y, et al. Clinical and practice variations in pediatric acute recurrent or chronic pancreatitis: report from the INSPPIRE study. *J Pediatr Gastroenterol Nutr*. 2020;71:112–8, <http://dx.doi.org/10.1097/MPG.0000000000002661>.
8. Saito N, Suzuki M, Sakurai Y, et al. Genetic analysis of Japanese children with acute recurrent and chronic pancreatitis. *J Pediatr Gastroenterol Nutr*. 2016;63:431–6, <http://dx.doi.org/10.1097/MPG.0000000000001320>.
9. Sweeny KF, Lin TK, Nathan JD, et al. Rapid progression of acute pancreatitis to acute recurrent pancreatitis in children. *J Pediatr Gastroenterol Nutr*. 2019;68:104–9, <http://dx.doi.org/10.1097/MPG.0000000000002145>.
10. Sánchez-Ramírez CA, Larrosa-Haro A, Flores-Martínez S, et al. Acute and recurrent pancreatitis in children: etiological factors. *Acta Paediatr*. 2007;96:534–7, <http://dx.doi.org/10.1111/j.1651-2227.2007.00225.x>.
11. Giefer MJ, Lowe ME, Werlin SL, et al. Early-onset acute recurrent and chronic pancreatitis is associated with *PRSS1* or *CTRC* gene mutations. *J Pediatr*. 2017;186:95–100, <http://dx.doi.org/10.1016/j.jpeds.2017.03.063>.
12. Saraswat VA, Sharma BC, Agarwal DK, et al. Biliary microlithiasis in patients with idiopathic acute pancreatitis and unexplained biliary pain: response to therapy. *J Gastroenterol Hepatol*. 2004;19:1206–11, <http://dx.doi.org/10.1111/j.1440-1746.2004.03462.x>.
13. Garipey CE, Heyman MB, Lowe ME, et al. Causal evaluation of acute recurrent and chronic pancreatitis in children: consensus from the INSPPIRE group. *J Pediatr Gastroenterol Nutr*. 2017;64:95–103, <http://dx.doi.org/10.1097/MPG.0000000000001446>.
14. Husain SZ, Morinville V, Pohl J, et al. Toxic-metabolic risk factors in pediatric pancreatitis: recommendations for diagnosis, management, and future research. *J Pediatr Gastroenterol Nutr*. 2016;62:609–17, <http://dx.doi.org/10.1097/MPG.0000000000001035>.

J.A. Macias-Flores^{a,*}, Y. Rivera-Suazo^b, L.J. Mejía-Marin^c

^a *División de Gastroenterología, Hospital Infantil de Especialidades de Chihuahua, Chihuahua, Mexico*

^b *División de Gastroenterología y Nutrición Pediátrica, Star Médica Hospital Infantil Privado, Mexico City, Mexico*
^c *División de Genética Humana, Centro Estatal de Cancerología, Chihuahua, Mexico*

*Corresponding author. Hospital Infantil de Especialidades de Chihuahua, Av. Carlos Pacheco, s/n, Chihuahua, Mexico. Tel.: 4332900; Ext.: 22941.
 E-mail address: dr.maciasflores@hotmail.com (J.A. Macias-Flores).

2255-534X/ © 2023 Published by Masson Doyma México S.A. on behalf of Asociación Mexicana de Gastroenterología. This is an open access article under the CC BY-NC-ND license (<http://creativecommons.org/licenses/by-nc-nd/4.0/>).

Atypical presentation in adolescence of a gastroesophageal junction adenocarcinoma[☆]



Presentación atípica en la adolescencia de un adenocarcinoma de la unión esofagogástrica

Gastroesophageal junction adenocarcinoma (GEJA) accounts for 0.05% of pediatric malignant gastrointestinal tumors.¹ The common age at presentation is above 50 years, and so its appearance in children and adolescents is extremely rare.²

There are very few case reports in pediatric patients,¹ and they are listed in Table 1. Staging and treatment in that population is based on those established for adults. Prognosis is usually poor, given that those tumors in children are often poorly differentiated, and because the disease is largely unsuspected, it is diagnosed in advanced stages with metastasis, resulting in a mortality rate close to 100%. Thus, cases of dysphagia in children should potentially be studied.^{1,3}

Due to the low presentation frequency of the tumor, its causes are not yet well defined.⁴ They have been related to certain risk factors in adults, such as smoking, alcohol use, fatty food and red meat consumption, A blood type, as well as Epstein-Barr virus infection and *Helicobacter pylori* infection, with the *vacAs1-*, *vacAm1-*, *cagA*-positive genotypes; those infections are potentiated in patients that are carriers of the cytokine gene polymorphisms, such as IL-1B-511**T*/**T* or IL-1B-511**T*/**C*. Cases are most likely *de novo* in children but germline mutations in E-cadherin, with an autosomal dominant inheritance pattern, must not be ruled out, which if present, can be a treatment target.²

Dysphagia is the most prevalent symptom, followed by weight loss, anemia, dehydration, nausea, epigastric or retrosternal pain, regurgitation, and hematemesis.⁴

In 1996, Siewert et al. proposed a classification based on the definition of GEJA, which is a neof ormation that grows within 5 cm of the cardia, in a distal or proximal direction, and that is divided into 3 subtypes:

- Type I: adenocarcinoma of the distal esophagus, extending 1 to 5 cm above the junction.
- Type II: adenocarcinoma of the cardia; “junctional carcinoma”, extending 1 cm above and 2 cm below the junction.
- Type III: subcardial gastric carcinoma, extending 2 to 5 cm below the junction.⁵

In the past, standard treatment was open surgical resection with negative margins. Currently, tumors that only affect the mucosa (T1a) can be treated through endoscopic resection.⁶ In patients with locally advanced disease (T3 or T4), perioperative chemotherapy and radiotherapy significantly improve survival.⁷ Treatment with epirubicin, cisplatin, and 5-fluorouracil have increased survival by 36%, compared with the 23% in patients treated only through surgery.⁸

A 15-year-old boy was seen at the outpatient service of the *Hospital Central del Estado de Chihuahua*. He had a medical history of 4 months of progressive dysphagia, anemia syndrome, and weight loss. He was hospitalized, with Hb of 5.5 g/dl, MCV of 74 fl, MCH of 24 pg, and platelets of 500 × 10³/ul. He underwent transfusion with two units of red blood cells and then had an upper endoscopic examination. Retroflexion during the upper endoscopy revealed a tumor in the cardia, 6 cm from the mucosa. Its aspect was adenomatous and friable, and it bled during the insufflation. The tumor extended into the lesser curvature and the inferior third of the esophagus, partially obstructing the lumen (Fig. 1), and corresponded to a type II GEJA, according to Siewert. A tomography scan of the chest and abdomen identified a 5.7 × 2.6 cm infiltrative gastric tumor, with perigastric lymph node invasion, that had clinical staging (cTNM) of T3, N2, M0 (Fig. 2). The histopathologic findings through immunohistochemistry were a moderately differentiated adenocarcinoma, with invasion of the stroma, no microsatellite instability, integral DNA repair protein expression, and null p53 expression. The patient underwent preoperative chemotherapy administra-

Table 1 Cases of GEJA reported in children and adolescents

Author	Year	Number of cases reported	Age
Elliott MJ ³	1983	1 male	14 years
Sasaki H ¹	1999	1 female	11 years
Subbiah V ²	2011	1 male	17 years

[☆] Please cite this article as: Amaya Villagrán G, Loya Lazcano KM, Baeza Zapata AA. Presentación atípica en la adolescencia de un adenocarcinoma de la unión esofagogástrica. *Rev Gastroenterol Méx.* 2023;88:299–301.