



REVISTA DE GASTROENTEROLOGÍA DE MÉXICO

www.elsevier.es/rgmx



CLINICAL IMAGE IN GASTROENTEROLOGY

Senile amyloidosis. Endoscopic findings as a starting point for diagnosis[☆]

Amiloidosis senil. Hallazgos endoscópicos como punto de partida para el diagnóstico

A. Gonçalves*, M. Azevedo-Silva, H. Vasconcelos

Departamento de Gastroenterología, Centro Hospitalar de Leiria, Leiria, Portugal

An 86-year-old man was referred to our department for endoscopic study due to a 3-month history of non-bloody fatty diarrhea, anorexia, and 15 kg weight loss. He had a year long history of heart failure, with reduced

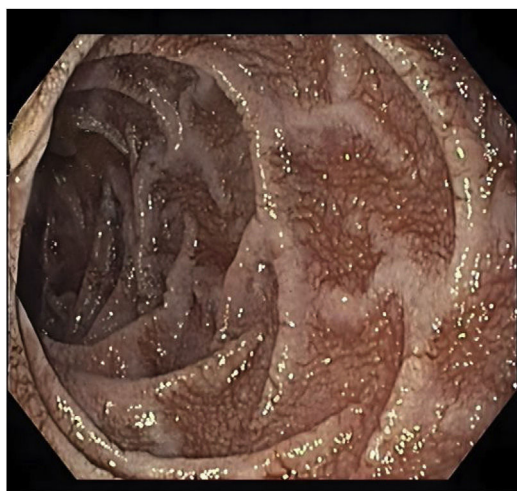


Figure 1 Esophagogastroduodenoscopy showed friable mucosa with granular elevations and thickened and very prominent duodenal folds in the second part of the duodenum.

[☆] Please cite this article as: Gonçalves A, Azevedo-Silva M, Vasconcelos H. Amiloidosis senil. Hallazgos endoscópicos como punto de partida para el diagnóstico. *Rev Gastroenterol Méx.* 2023;88:287–288.

* Corresponding author at: Departamento de Gastroenterología, Centro Hospitalar de Leiria, Rua das Olhalvas, 2410-197 Leiria, Portugal. Tel.: +00351914546507.

E-mail address: andre.ruge005@gmail.com (A. Gonçalves).

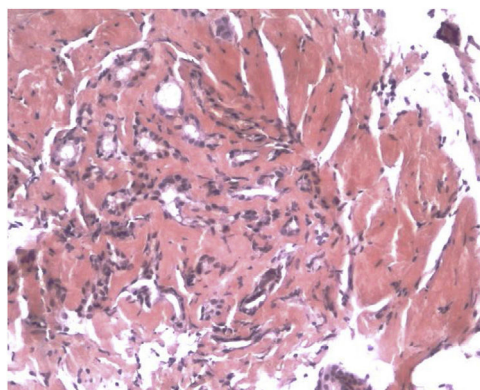


Figure 2 Biopsy specimens showed Congo red-stained amyloid deposits, with apple-green birefringence, under polarized light.

ejection fraction, and dementia syndrome. Iron-deficiency anemia, hypomagnesemia, and severe hypoalbuminemia were apparent in the laboratory work-up, with no other abnormalities. Esophagogastroduodenoscopy showed friable mucosa with granular elevations and thickened and very prominent duodenal folds in the second part of the duodenum (Fig. 1). Biopsy specimens showed Congo red-stained amyloid deposits, with apple-green birefringence, under polarized light (Figs. 2 and 3). Cardiac scintigraphy with ^{99m}Tc-DPD showed clearly evident myocardial uptake, suggesting wild-type senile transthyretin amyloid deposits. The rest of the etiologic studies yielded negative results. Gastrointestinal senile systemic amyloidosis was diagnosed. Only symptomatic treatment was given due to the patient's




Figure 3 Cardiac scintigraphy with ^{99m}Tc -DPD showed clearly evident myocardial uptake suggesting wild-type senile transthyretin amyloid deposits.

age and lack of evidence-based therapies in arresting or slowing this condition. The patient died 3 months after diagnosis.

Ethical considerations

Because no personal data that could identify the patient were published, approval by an ethics committee was not required, nor was informed consent needed.

Financial disclosure

No specific grants were received from public sector agencies, the business sector, or non-profit organizations in relation to this article.

Authorship

AG reviewed the literature and wrote the manuscript; MAS reviewed the literature; HV reviewed and approved the final manuscript.

Conflict of interest

The authors declare that there is no conflict of interest.