




REVISTA DE
GASTROENTEROLOGÍA
DE MÉXICO

www.elsevier.es/rgmx



CLINICAL IMAGE IN GASTROENTEROLOGY

Eosinophilic colitis: An unusual case[☆]



Colitis eosinofílica: un caso inusual

J.M. Remes-Troche^a, A. Meixuiero-Daza^b, G.R. Guevara-Morales^{b,*}

^a Laboratorio de Fisiología Digestiva y Motilidad Gastrointestinal, Instituto de Investigaciones Médico-Biológicas, Universidad Veracruzana, Veracruz, Veracruz, Mexico

^b Unidad de Endoscopia, Instituto de Investigaciones Médico-Biológicas, Universidad Veracruzana, Veracruz, Veracruz, Mexico

Eosinophilic colitis is a disease characterized by a state of chronic intestinal inflammation. Its etiology is unknown and the pathology is little known and not often seen.¹ Its mean presentation is in patients in the fourth decade of life, but it can manifest in patients up to the eighth decade of life. There are case reports in both children and persons of advanced age and on occasion the disease is associated with the presence of eosinophilic esophagitis or eosinophilic gastritis. Its clinical presentation is abdominal pain,

diarrhea with or without blood, and weight loss. The habitual endoscopic findings can range from edema of the mucosa to aphthous ulcers. The case presented herein had atypical endoscopic images manifested by pseudopolypoid formations. Indicated treatment includes the use of 5-ASA, even steroids, azathioprine, or biologic therapy targeted at IL-5 and IgE.² The histologic image indicated the presence of abundant eosinophils, confirming the diagnosis (fig. 1).

[☆] Please cite this article as: Remes-Troche JM, Meixuiero-Daza A, Guevara-Morales GR. Colitis eosinofílica: un caso inusual. Revista de Gastroenterología de México. 2015;80:161–162.

* Corresponding author. Iturbide S/N, Colonia Flores Magón, Veracruz, Ver. CP 91400. Tel.: +229 9279229.

E-mail address: grobotoguevara@gmail.com (G.R. Guevara-Morales).

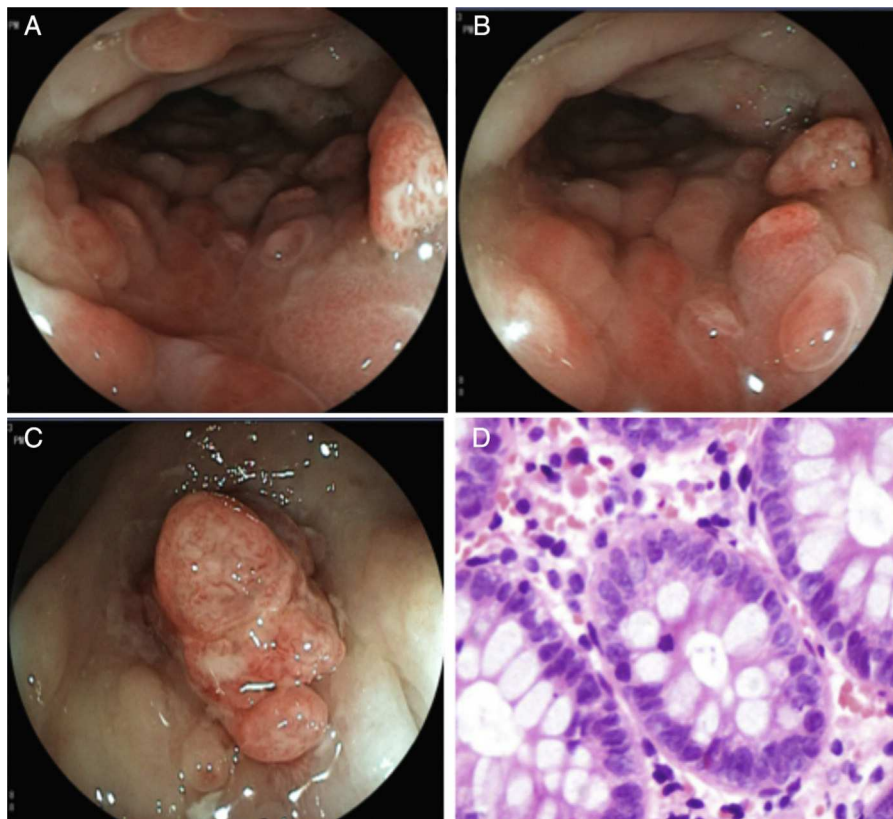


Figure 1 A and B) the descending colon showing the inflammatory changes, edema of the mucosa, patchy erythema, pseudopolypoid formations, and vascular pattern loss. C) Lesion with a polypoid aspect in the sigmoid colon with loss of mucosal continuity, edema, and vasculature alteration. D) Photomicrography shows abundant eosinophils in the lamina propria, up to 70 per field at a high magnification.

Ethical responsibilities

Protection of persons and animals. The authors declare that the procedures followed conformed to the ethical standards of the responsible committee on human experimentation and were in accordance with the World Medical Association and the Declaration of Helsinki.

Data confidentiality. The authors declare that they have followed the protocols of their work center in relation to the publication of patient data.

Right to privacy and informed consent. The authors have obtained the informed consent of the patients and/or subjects referred to in the article. This document is in the possession of the corresponding author.

Financial disclosure

No financial support was received in relation to this study/article.

Conflict of interest

José María Remes Troche is a member of the Advisory Counsel of Takeda Pharmaceuticals, Alfa-Wassermann, Almirall, and Janssen. He is also a Speaker for Nycomed-Takeda, Advance Medical, Endomedica, Astra-Zeneca, and Bristol-Myers-Squibb. Sanofi-Pasteur, Menarini, Asofarma, and Astra Zeneca provide Research support.

References

1. Wolfgang B, MacDonald J, Kwaan M, et al. Eosinophilic colitis: University of Minnesota experience and literature review. *Gastroenterol Res Pract.* 2011;2011:1–6.
2. Alfadda AA, Storr MA, Shaffer EA. Shaffer eosinophilic colitis: Epidemiology, clinical features, and current management. *Therap Adv Gastroenterol.* 2010;10:1.