Revista de Gastroenterología de México 90 (2025) 479–480

REVISTA DE GASTROENTEROLOGÍA DE MÉXICO
www.elsevier.es/rgmx

CLINICAL IMAGE IN GASTROENTEROLOGY

Unanticipated encounter with *Ascaris lumbricoides* during endoscopic bile duct stone removal: A case report

Encuentro inesperado con *Ascaris lumbricoides* durante extracción endoscópica de cálculos del conducto biliar: un reporte de caso

S. Gómez-Jordan[a,*], A. Sepúlveda[b], A. Montes[b], N. Forti-Sosa[c]

[a] *Departamento de Medicina Interna, Universidad Del Norte, Barranquilla, Colombia*
[b] *Departamento de Gastroenterología, Clínica Portoazul, Puerto Colombia, Colombia*
[c] *Departamento de Cirugía Endoscópica, Clínica Portoazul, Puerto Colombia, Colombia*

Ascaris lumbricoides is a soil-based helminth parasite. It is distributed worldwide, with a high incidence in tropical regions, including those of Colombia and Mexico. Infection with the parasite is considered a neglected tropical disease. Diagnosis is made through microscopic observation of the parasite's eggs or macroscopic identification of the parasitic worm, such as during endoscopy. A 56-year-old woman, with a past history of cholecystectomy, arrived at the emergency department with diffuse colicky abdominal pain, located in the right hypochondrium, and choluria, for the past 24 h. She also presented with generalized jaundice, leukocytosis, direct hyperbilirubinemia, and elevated transaminase and alkaline phosphatase levels. Magnetic resonance cholangiopancreatography (MRCP) showed the absence of the gallbladder, a metallic clip in the cystic duct, choledocholithiasis, and dilatations of the intrahepatic and extrahepatic bile ducts of 15 and 13 mm, respectively (Fig. 1). Cholangitis was initially considered, and ampicillin-sulbactam was started. A scheduled endoscopic retrograde cholangiopancreatography (ERCP) revealed extrahepatic dilatation and a 12 × 15 mm stone in the common bile duct. Lithotripsy was performed, and an

Figure 1 Magnetic resonance cholangiopancreatography (MRCP). The gallbladder is not visualized. There is evidence of choledocholithiasis, with a 13 mm dilatation of the common bile duct and a 15 mm dilatation of the common hepatic duct.

* Corresponding autor at: Calle 104 # 53-49, 081001 Barranquilla, Colombia. Tel.: +57 3184706952.
E-mail address: santiagogomezjordan@me.com (S. Gómez-Jordan).

2255-534X/© 2025 Published by Masson Doyma México S.A. on behalf of Asociación Mexicana de Gastroenterología. This is an open access article under the CC BY-NC-ND license (http://creativecommons.org/licenses/by-nc-nd/4.0/).

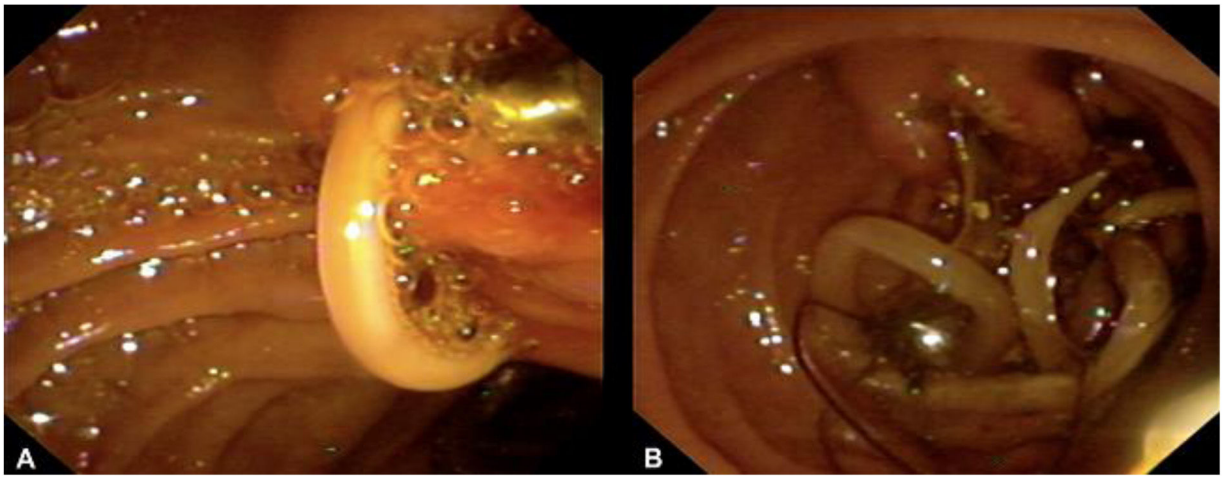

Figure 2 Endoscopic retrograde cholangiopancreatography (ERCP) images. A) *Ascaris lumbricoides* is seen protruding from inside the bile duct. B) The worm is shown outside of the bile duct, located in the duodenum, post-extraction.

adult *Ascaris lumbricoides* was discovered and extracted (Video 1 and Fig. 2A and B). Treatment with a single dose of 400 mg of albendazole was indicated. After clinical improvement, the patient was discharged to her home. She had no recurrence during follow-up. Treatment options include albendazole, ivermectin, and nitazoxanide, and in some cases, endoscopic extraction.

CRediT authorship contribution statement

All authors discussed the results and contributed to the final manuscript, approved the final version of the manuscript, and are accountable for all aspects of the work.

NF performed the surgical procedure; SGJ wrote the manuscript and edited the video. AS and AM contributed to the editing of the manuscript.

Ethical considerations

The authors declare that the procedures were carried out, according to the Declaration of Helsinki of the World Medical Association, updated in 2013.

We confirm that this manuscript does not contain any personal information that could identify the patient, and so patient informed consent was not required.

Financial disclosure

No financial support was received in relation to this article.

Declaration of competing interest

The authors declare that there is no conflict of interest.

Appendix A. Supplementary data

Supplementary material related to this article can be found, in the online version, at doi:https://doi.org/10.1016/j.rgmxen.2025.09.012.