



REVISTA DE  
GASTROENTEROLOGÍA  
DE MÉXICO

[www.elsevier.es/rgmx](http://www.elsevier.es/rgmx)



## CLINICAL IMAGE IN GASTROENTEROLOGY

# A giant staghorn calculus in the biliary tract<sup>☆</sup>



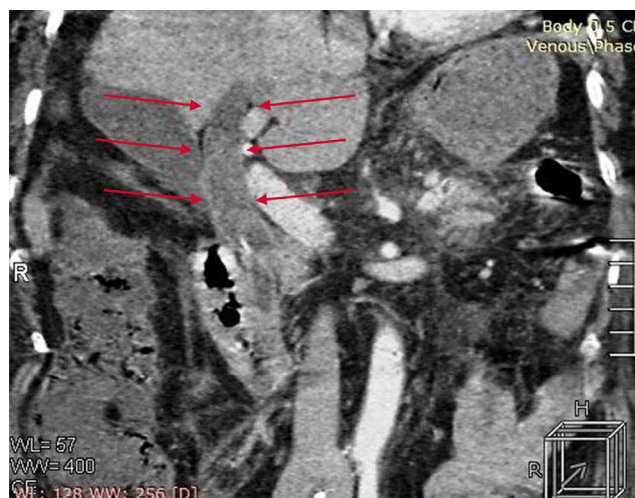## Litiasis coraliforme gigante en la vía biliar

G. Martinez-Mier\*, O. Avila-Mercado, S. Irisson-Mora

Departamento de Cirugía General, Unidad Médica de Alta Especialidad 189 Adolfo Ruiz Cortines, Instituto Mexicano del Seguro Social, Veracruz, México

Received 7 February 2014; accepted 19 February 2014

The clinical importance of biliary tract calculi is in their association with cholangitis and acute pancreatitis. Endoscopic retrograde cholangiopancreatography (ERCP) is regarded as the safest and most successful therapeutic method for extracting stones from the common bile duct. Nevertheless, large or impacted calculi that take up the entire bile duct are a therapeutic challenge. A bile duct calculus is defined as large when it is bigger than 10–15 mm. There are very few reports describing a single giant calculus (> 5 cm) in the common bile duct. We describe herein a 58-year-old woman that presented with severe acute pancreatitis. Tomography findings included a stone impacted in the bile duct, dilation of the bile ducts, and cholelithiasis (fig. 1). ERCP revealed a giant stone in the common bile duct that occupied the space up to the confluence of the hepatic ducts (fig. 2). The patient underwent a conventional cholescystectomy with bile duct exploration and a Roux-



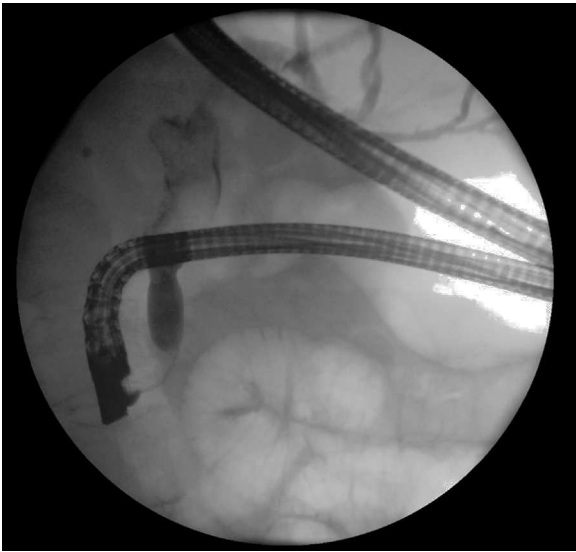
**Figure 1** Abdominal CAT scan showing bile duct dilation and a calculus in its interior.

<sup>☆</sup> Please cite this article as: Martinez-Mier G, Avila-Mercado O, Irisson-Mora S. Litiasis coraliforme gigante en la vía biliar. Revista de Gastroenterología de México. 2014;79:200–201.

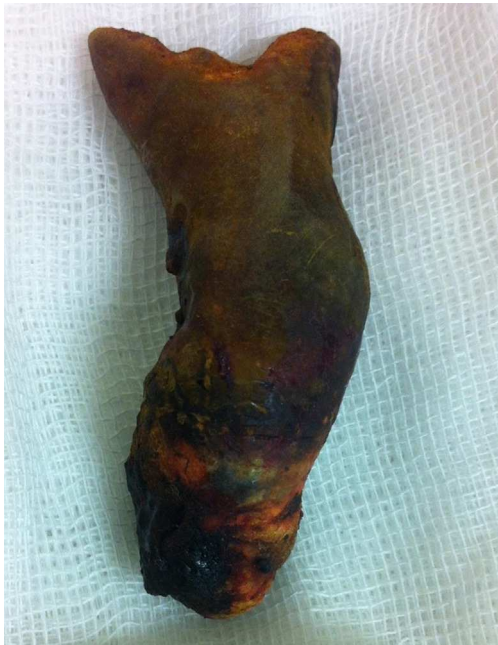\* Corresponding author: Corporativo San Gabriel, Alacio Pérez, 928, consultorios 313 y 314, entre Carmen Serdán y 20 de Noviembre. Fraccionamiento Zaragoza. Veracruz, CP 91910. Teléfono: +52(229)9327782; fax: +52(229)9232990.

E-mail addresses: [martinez.gustavo@transplantver.com](mailto:martinez.gustavo@transplantver.com), [gmtzmier@hotmail.com](mailto:gmtzmier@hotmail.com) (G. Martinez-Mier).

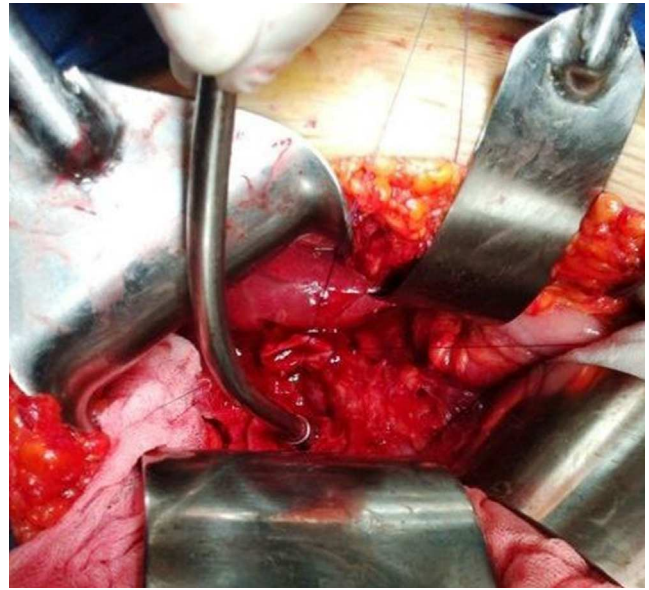
en-Y hepaticojejunal anastomosis, extracting a 7 x 2 cm staghorn calculus (figs. 3 and 4). The patient was released from the hospital with no complications. She is asymptomatic 6 months after surgery and her liver function tests are normal.



**Figure 2** ERCP showing a 7 cm impacted calculus.



**Figure 3** Staghorn calculus extracted from the bile duct.



**Figure 4** The dilated hepatic duct sectioned (2 cm) and used as a reference point for the hepaticojejunal anastomosis.

#### **Financial disclosure**

No financial support was received in relation to this article.

#### **Conflict of interest**

The authors declare that there is no conflict of interest.