



REVISTA DE GASTROENTEROLOGÍA DE MÉXICO

www.elsevier.es/rgmx



CLINICAL IMAGE IN GASTROENTEROLOGY

An unusual finding after endovascular treatment of gastrointestinal bleeding: An endoscopic view of an endovascular spiral

Hallazgo inusual posterior al tratamiento endovascular de la hemorragia de tubo digestivo: visión endoscópica de una espiral endovascular

J.E. Aquino-Matus^a, M. Figueroa-Palafox^a, J. Guerrero-Ixtlahuac^b,
L.R. Valdovinos-García^{c,d,*}

^a Hospital Médica Sur, Unidad de Enfermedades Digestivas y Obesidad, Mexico City, Mexico

^b Hospital Médica Sur, Servicio de Imagenología, Mexico City, Mexico

^c Instituto Nacional de Ciencias Médicas y Nutrición Salvador Zubirán, Cirugía Experimental, Mexico City, Mexico

^d Instituto Politécnico Nacional, Escuela Superior de Medicina, Mexico City, Mexico

An 80-year-old woman had a history of having undergone a Graham patch repair due to a perforated duodenal ulcer 8 years prior to the present event, as well as the use of sertraline for major depression and acetylsalicylic acid for primary cardiovascular prevention. She came to the emergency room because of nausea, epigastric pain, hematemesis, melena, and lipothymia of 4-hour progression. She received advanced airway management and resuscitation with crystalloids, blood products, and vasopressors. Upper endoscopy was performed within the first 24 hours, documenting a Forrest Ia duodenal ulcer in which endoscopic hemostatic treatment with adrenaline and endoscopic clips had failed (Fig. 1). Emergency hemostatic treatment was performed through angiography with embolization of endovascular hemostatic spirals, successfully controlling the bleeding (Fig. 2A and B). The patient's clinical progression was satisfactory. She presented with a decrease in hemoglobin value (2 g/dl) on

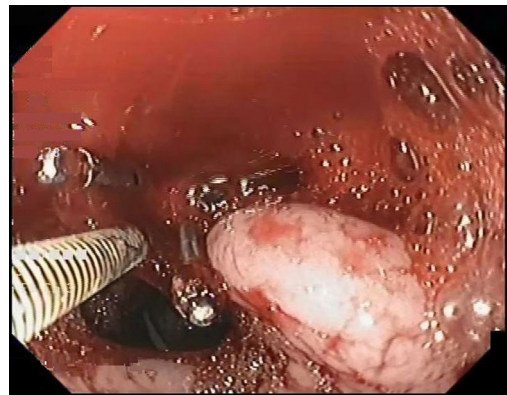


Figure 1 Forrest Ia duodenal ulcer with active bleeding in the layer after failed endoscopic hemostatic double therapy with hemoclips and adrenaline.

* Corresponding author. Calle Puente de Piedra 150 Torre 2 – 618, Colonia Toriello Guerra, C.P. 14050, Tlalpan, Mexico City, Mexico.
E-mail address: drprapul@gmail.com (L.R. Valdovinos-García).

day 4 and an upper endoscopy was carried out, in which an endovascular spiral protruding from the visible vessel was found (Fig. 3). At 3 months, the peptic ulcer had healed (Fig. 4). The visualization of endovascular spirals during

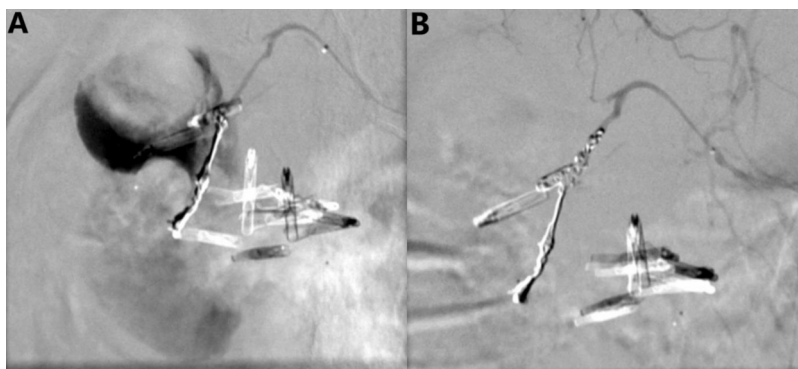


Figure 2 A) Selective angiography of the gastroduodenal artery with contrast medium leakage into the second and third part of the duodenum. B) Selective angiography showing hemostatic spirals in the gastroduodenal artery and successful control of bleeding (courtesy of Dr. Jorge Guerrero).

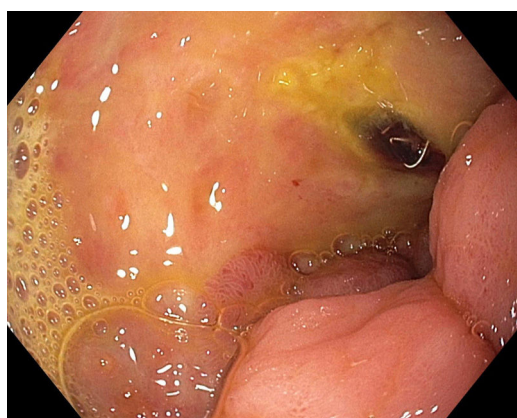

Figure 3 Endovascular spiral protruding from the mucosa at the site of the visible vessel, in the ulcer bed with fibrin.

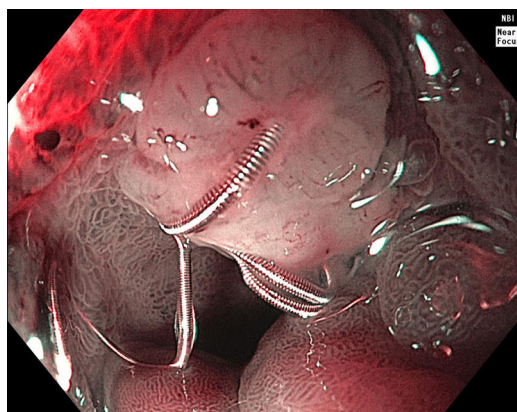


Figure 4 Endovascular spiral protruding from the duodenal mucosa at the site of the peptic ulcer 4 months after the index event (narrow band image with magnification).

endoscopy is a rare finding that is mainly described in duodenal ulcers. In the majority of cases, it is associated with the healing of the underlying gastrointestinal disease.

Ethical considerations

The authors declare that this work contains no information that could identify the patient, guaranteeing his/her privacy and anonymity. No experiments were conducted on animals or humans.

Financial disclosure

No financial support was received in relation to this article.

Conflict of interest

The authors declare that there is no conflict of interest.