



SCIENTIFIC LETTERS

Bouveret's syndrome: An unusual cause of duodenal obstruction[☆]



Síndrome de Bouveret, una causa infrecuente de obstrucción duodenal

Bouveret's syndrome is a rare type of gallstone ileus that consists of duodenal obstruction secondary to the passage of a stone through a cholecystoduodenal fistula and presents in elderly patients. A clinical case is described.

An 86-year-old man sought medical attention for epigastric pain and vomiting with food remains for several days associated with general malaise and dehydration. Physical examination revealed mild epigastric pain with tympanism.

Laboratory work-up reported hemoglobin 16.3 g/dL, urea 133 mg/dl, creatinine 3.20 mg/dl, lactate 2.14 mmol/L, and CRP 189.6 mg/L. A plain abdominal x-ray showed gastric dilation. Upper endoscopy revealed a dilated stomach with abundant fluid. A large stone was found over the pylorus and duodenum that impeded the passage of the endoscope. An attempt to fragment the stone was unsuccessful. A CT scan also identified the presence of a stone, along with gas in the gallbladder. A pyloroduodenotomy with stone extraction and transverse duodenorrhaphy with the Heineke-Mikulicz technique were performed, but not a cholecystectomy. There were no postoperative complications and the patient was released from the hospital (fig. 1).

Bilioenteric fistula is present in 2-3% of the cases of cholelithiasis.¹ This communication allows the stone to enter the intestine causing a bowel obstruction known as

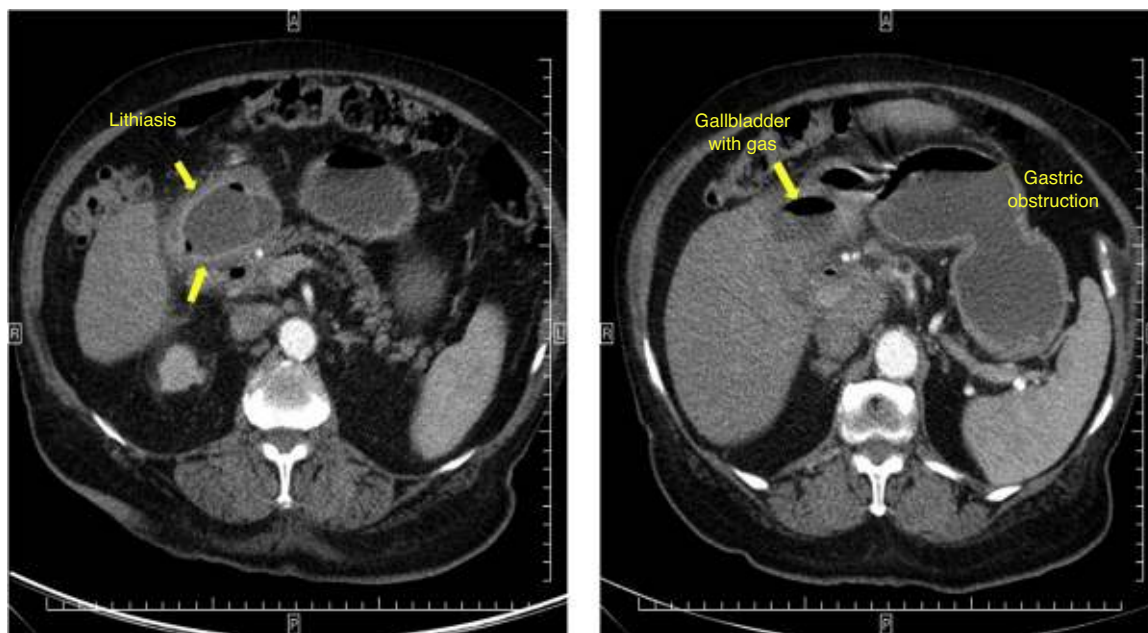


Figure 1 Abdominal CT scan showing impacted lithiasis at the pyloroduodenal level and the gastric obstruction.

[☆] Please cite this article as: Ruiz de la Hermosa A, Ortega-Domene P, Zarzosa-Hernández G, Seoane-González JB. Síndrome de Bouveret, una causa infrecuente de obstrucción duodenal. Revista de Gastroenterología de México. 2016;81:55–56.

gallstone ileus. The majority of the fistulas are cholecystoduodenal, followed by cholecystocolic and cholecystogastric fistulas. Nevertheless, the stones are small and eliminated without causing obstruction. Only 6% of fistula-associated stones cause obstruction. The most frequent occlusion site is the small bowel. When the stone is lodged at the level of the duodenum, obstructing the gastric outlet, it is called Bouveret's syndrome, and it represents only 1-3% of the cases of gallstone ileus.^{2,3} The syndrome was named after the French physician, Leon Bouveret, who published 2 cases of the pathology in 1896.⁴

Bouveret's syndrome is more frequent in elderly women and it presents with nausea, vomiting, and epigastric pain. There can be gastrointestinal bleeding in severe cases. The most frequent complication is hydroelectrolytic imbalance.^{1,5} Diagnosis is delayed, given that patients do not have a history of cholelithiasis and the symptoms are non-specific. It can be confused with other causes of gastroduodenal obstruction, and so differential diagnosis must be made with bezoar, foreign body impaction, gastric volvulus, tumor, peptic stricture, superior mesenteric artery syndrome, etc. Plain abdominal x-ray can sometimes identify the Rigler triad (intestinal obstruction or gastric dilation, pneumobilia, and ectopic stone visualization).^{1,3} Endoscopy is diagnostic in 70% of the cases.⁴ Endoscopic stone extraction can be attempted, but it may not be possible if the stone is larger than 2.5 cm. Surgery is the treatment of choice. There are 2 alternatives: one-stage surgery (with enterotomy, stone extraction, and cholecystectomy with fistula repair) or simple enterotomy and stone extraction. The combined surgery has been associated with higher postoperative mortality rates (20-30%), compared with cases of duodenotomy alone (6-12%).⁴ Gallstone ileus recurrence (less than 5%) or biliary symptom persistence (10%) are low.^{1,3}

In conclusion, Bouveret's syndrome is rare and therefore diagnosis is by exclusion. The ideal treatment is endoscopic, but if that fails, then surgery is necessary.

Financial disclosure

No financial support was received in relation to this study/article.

Conflict of interest

The authors declare that there is no conflict of interest.

References

1. Álvarez Chica LF, Bejarano Cuéllar W, Rojas Cardozo OL. Íleo biliar y síndrome de Bouveret. Lo mismo pero distinto: Descripción de dos casos y revisión de la literatura. *Rev Col Gastroenterol.* 2010;25:86-93.
2. Rivera Irigoín R, Ubiña Aznar E, García Fernández G, et al. Síndrome de Bouveret resuelto mediante litotricia mecánica endoscópica. *Rev Esp Enferm Dig.* 2006;98:790-2.
3. Báez-García JJ, Martínez-Hernández-Magro P, Iriarte-Gállego G. Bouveret's syndrome; a case report [Article in Spanish]. *Rev Gastroenterol Mex.* 2009;74:118-21.
4. Doycheva I, Limaye A, Suman A, et al. Bouveret's syndrome: Case report and review of the literature. *Gastroenterol Res Pract.* 2009;2009:914951.
5. López-Martínez JA, Delgado-Carlo MM, Palacio-Vélez F, et al. Bouveret's syndrome. Case report [Article in Spanish]. *Cir Cir.* 2004;72:317-22.

A. Ruiz de la Hermosa*, P. Ortega-Domene,
G. Zarzosa-Hernández, J.B. Seoane-González

General and Gastrointestinal Tract Surgery, Hospital Universitario Infanta Leonor, Madrid, Spain

* Corresponding author. Hospital Universitario Infanta Leonor, Servicio de Cirugía General y del Aparato Digestivo, Calle Gran Vía del Este 80, 28031 Madrid.

Tel.: +34 91 191 80 00.

E-mail address: aliciaruiz9@hotmail.com

(A. Ruiz de la Hermosa).

Resolution of complex choledocholithiasis with removable metal stent. A case report[☆]



Resolución de coledocolitiasis compleja con stent metálico removible. Reporte de un caso

Extraction can turn out to be complex in 15-20% of choledochal stones due to size (> 15 mm), number (≥ 3), or the container-content dissociations determining impactions.^{1,2} Under these adverse circumstances, other endoscopic tech-

niques should be applied: large-volume balloon dilation or mechanical, laser, or electrohydraulic lithotripsy.³⁻⁵ If therapeutic success is not achieved, the placement of plastic biliary stents is employed as a bridge until definitive intervention. Over the last decade, the use of self-expanding metal stents in the context of benign biliary pathology has increased, but their role in treating biliary stones has not been described.⁶⁻⁸ We present herein the case of complex bile duct stones resolved through the placement of a removable metallic biliary stent.

A 59-year-old woman had a past medical history of cholecystectomy and severe aortic stenosis. She sought medical attention for intense epigastric pain irradiating to the upper right quadrant and back, accompanied with jaundice and choloria of 15-day progression. A liver function test showed cholestasis and abdominal ultrasound revealed dilated intrahepatic and extrahepatic bile ducts with a 20 mm stone in the retropancreatic part of the bile duct.

[☆] Please cite this article as: Curvale C, Guidi M, Hwang H, De Maria J, Matanó R. Resolución de coledocolitiasis compleja con stent metálico removible. Reporte de un caso. *Revista de Gastroenterología de México.* 2016;81:56-58.