

sarcoidosis, 85% of the patients were spontaneously cured and 10% of the cases became chronic, utilizing corticoids in the most severe cases.² Other treatments that have been used are hydroxychloroquine¹⁰ and infliximab.¹¹ The administration of corticoids can increase the viral burden and hepatitis C virus itself induces interferon alpha expression.¹²

It is relatively common in medical consultations to find patients with hepatitis C virus, therefore if there are symptoms that lead to suspicion of sarcoidosis, the physician must take into account the association of this entity with interferon alpha use.

Funding

No financial support was received in relation to this study/article.

Conflict of interest

The authors declare that there is no conflict of interest.

References

- Doyle MK, Berggren R, Magnus JH. Interferon-induced sarcoidosis. *J Clin Rheumatol*. 2006;12:241–8.
- Ramos-Casals M, Mañá J, Nardi N, et al. HISPAMEC Study Group. Sarcoidosis in patients with chronic hepatitis c virus infection. Analysis of 68 cases. *Medicine (Baltimore)*. 2005;84:69–80.
- Hirano A, Kataoka M, Nakata Y, et al. Sarcoidosis occurring after interferon alpha therapy for chronic hepatitis C: Report of two cases. *Respirology*. 2005;10:529–34.
- Fantini F, Padalino C, Gualdi G, et al. Cutaneous lesions as initial signs of interferon alpha-induced sarcoidosis. Report of three new cases and review of the literature. *Dermatol Ther*. 2009;22 Suppl 1:S1–7.
- Trien R, et al. Interferon-alpha-induced sarcoidosis in a patient being treated for hepatitis C. *Am J Case Rep*. 2014;15:235–8.
- Gayet AR, Plaisance P, Bergmann JF, et al. Development of sarcoidosis following completion of treatment for hepatitis c with pegylated interferon alpha and ribavirin. A case report and literature review. *Clin Med Res*. 2010;8:163–7.
- Cardoso C, Freire R, Alves A, Oliveira A. Interferon-induced sarcoidosis. *BMJ Case Rep*. 2011;2011, bcr0320113929.
- Rodríguez-Lojo R, Almagro M, Barja JM, et al. Subcutaneous sarcoidosis during Pegylated interferon alfa and ribavirin treatment for chronic hepatitis C. *Dermatol Res Pract*. 2010;2010:230417.
- Hurst EA, Mauro T. Sarcoidosis associated with pegylated interferon alfa and ribavirin treatment for chronic hepatitis. A case report. *Arch Dermatology*. 2005;141:865–8.
- Jones E, Callen JP. Hydroxychloroquine is effective therapy for control of cutaneous sarcoid granulomas. *J Am Acad Dermatol*. 1990;23:487–9.
- Menon Y, Cucurull E, Reisin E, et al. Interferon-alpha-associated sarcoidosis responsive to infliximab therapy in: *Am J. Med Sci*. 1004, 328: 173-175.
- Buss G, Cattin V, Spring P, et al. Two cases of interferon-alpha-induced sarcoidosis Koebnerized along venous drainage lines: New pathogenic insights and review of the literature of interferon-induced sarcoidosis. *Dermatology*. 2013;226:289–97.

B.J. Flores-Robles^{a,*}, C.P. Sangüesa-Gómez^a,
C. Barbadillo Mateos^a, L.G. Roustán-Gullón^b, I. Kovtun^c

^a Rheumatology Service, Hospital Universitario Puerta de Hierro-Majadahonda, Majadahonda, Madrid, Spain

^b Dermatology Service, Hospital Universitario Puerta de Hierro-Majadahonda, Majadahonda, Madrid, Spain

^c Pathologic Anatomy Service, Hospital Universitario Puerta de Hierro-Majadahonda, Majadahonda, Madrid, Spain

* Corresponding author. Servicio de Reumatología, Hospital Universitario Puerta de Hierro-Majadahonda, Manuel de Falla no 1, Majadahonda, Madrid, Spain. Tel.: +695521497. E-mail address: aldolasa@hotmail.com (B.J. Flores-Robles). 2255-534X/

© 2016 Asociación Mexicana de Gastroenterología. Published by Masson Doyma México S.A. This is an open access article under the CC BY-NC-ND license (<http://creativecommons.org/licenses/by-nc-nd/4.0/>).

Severe complications of acute appendicitis with the laparoscopic approach[☆]



Complicaciones graves de apendicitis aguda con abordaje laparoscópico

Acute appendicitis is one of the surgically resolved abdominal pathologies with the highest incidence, occurring in 7%

of the general population.¹ Fortunately it has a low mortality rate under 0.1%.²⁻⁴

A 44-year-old man, who came to us from another hospital, had a relevant personal history of long progression type 2 diabetes mellitus that was apparently well controlled, and he had undergone a laparoscopic appendectomy on April 12, 2015 (38 days before we saw him). Phase III acute appendicitis was reported. It was defined as a venous infarction, total wall necrosis, and perforation, with the later formation of a localized abscess. Unfortunately, we had no detailed clinical report on the intraoperative findings or the surgical technique performed (use of antibiotic-impregnated sutures and/or preoperative asepsis and antisepsis measures). However, upon the patient's admission to our hospital, we observed a 3-port approach. One was a transumbilical port, another was at the level of the left flank, and the other was suprapubic. The first 2 had cicatrized, but abundant

[☆] Please cite this article as: Bahena-Aponte JA, González-Contreras Q, Tepeyac A. Complicaciones graves de apendicitis aguda con abordaje laparoscópico. *Revista de Gastroenterología de México*. 2017;82:186–189.

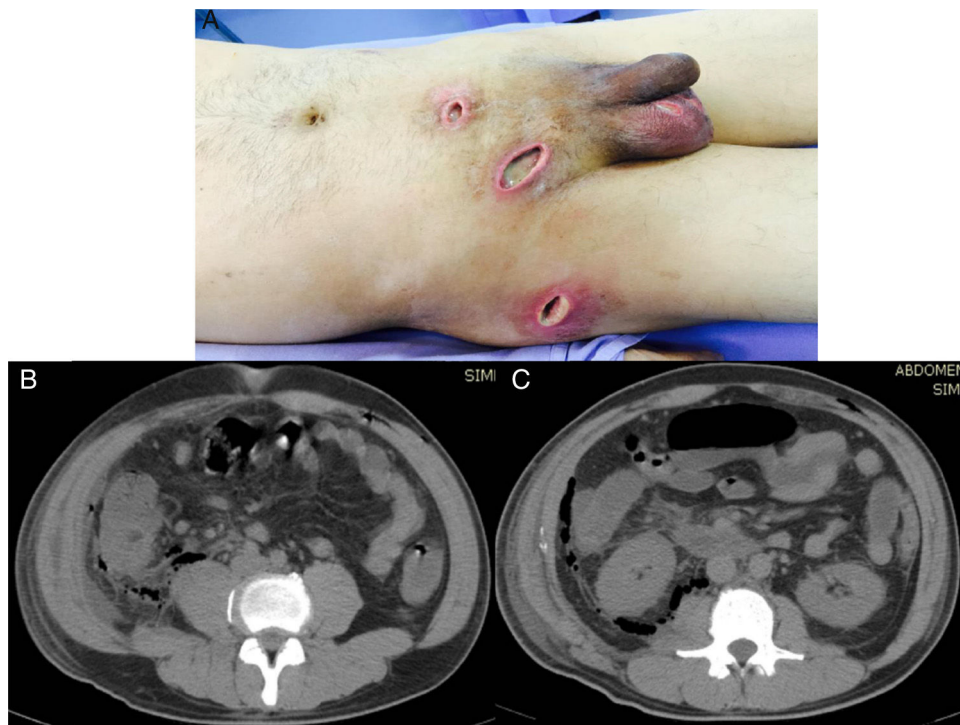


Figure 1 A) Important soft tissue infection is shown that extends from the suprapubic incision to the right inguinal region, and to the right scrotal region and flank, all with significant purulent matter. B) Tomographic image showing the retroperitoneal abscess extending proximally until reaching the costal ridge, with the presence of gas in its entire extension. C) Image showing the retroperitoneal abscess at the level of the cecum that extended through Toldt's fascia, with the presence of gas at this level.

purulent matter was exuding from the suprapubic port wound. Likewise, we observed 3 other incisions, one at the level of the right inguinal region, another at the ipsilateral scrotal level, and another at the level of the right pelvic limb on the lateral surface of its proximal third, all of which contained abundant purulent matter and had an apparent internal connection (fig. 1A).

The patient stated that on his 4th postoperative day, while he was still hospitalized, he presented with fever, pain at the surgical site, and a purulent discharge from the suprapubic port. His attending physician decided to remove the sutures from that port to favor its adequate drainage. However, despite antibiotic management (we do not know which regimens were established), progression was not satisfactory. To the contrary, there were signs of increased systemic inflammatory response, as well as soft tissue infection that extended to the inguinal region, the right scrotum, and the level of the right paracolic gutter. The 3 incisions mentioned above were made, all of which contained abundant purulent matter. Due to this poor progression, the patient was released 28 days later, still with wounds draining purulent matter, for which he came to the emergency department of our hospital on the 20th of May for medical attention.

Upon admission, the patient was conscious, with a facial expression of pain, and not very cooperative. His oral mucosa was dehydrated and he stated he had a weight loss of 8 kg in the past 3 weeks. The patient had right pleural effusion and tachycardia, as well as a distended abdomen

with muscular resistance that was depressible and painful upon mid and deep palpation. There was important pain at the level of the abdominal wall along the right paracolic gutter extending to the costal ridge and abundant purulent matter exuded from the abovementioned incisions. The patient had marked signs of peritoneal irritation, positive rebound tenderness, and reduced peristalsis. Laboratory tests upon admission reported conspicuous leukocytosis (22,000 cell/mm³) and an elevated procalcitonin level of 125 ng/ml.

Abdominal tomography scan identified a retroperitoneal collection at the level of the right fossa and paracolic gutter that extended into the soft tissues (figs. 1B and C). Exploratory laparotomy revealed an abscess of approximately 80 cc at the level of the retroperitoneum. A sample was taken from it for culturing and it developed *Escherichia coli*. The abscess was drained, and a closed drain was later placed at that level. The cavity was closed and lavage and soft tissue debridement was carried out, communicating the suprapubic wound and the proximal third of the leg. Access to the entire right paracolic gutter was thus achieved, revealing fasciitis and necrotic tissue. The latter was debrided and a Vacuum Assisted Closure (VAC) system was placed. Two surgical lavages with VAC replacement were later required. Patient progression was very satisfactory and leukocyte in blood (6.06 thousand/ μ l), procalcitonin (0.08 ng/ml), and C-reactive protein (0.71 ng/dl) values returned to normal. Given the patient's good progression, the surgical wound where the VAC was previously placed was closed

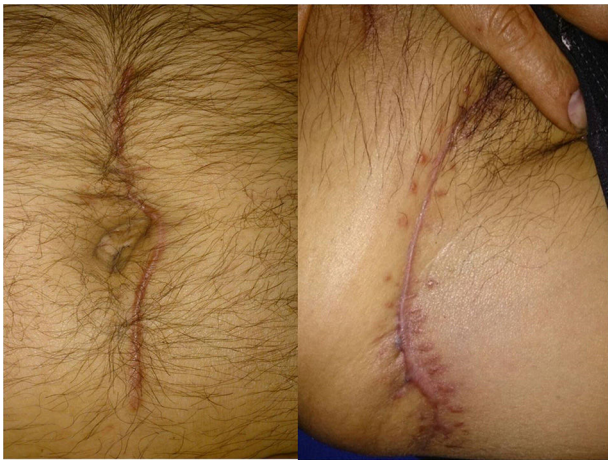

Figure 2 The final result showing the cicatrized wounds and no signs of infection.

and the abdominal drain was removed at 3 weeks, with a minimum serous output (fig. 2).

Discussion

Appendectomy, whether performed as a laparoscopic or open procedure, continues to be the cornerstone of management for this pathology, due to the important complications that can arise from late treatment. There are studies reporting conservative management that have shown it to be a safe practice, but it has not become generalized,⁵⁻⁸ because that could allow symptoms with an inherent increase in morbidity and mortality to progress in those patients.

On the other hand, there is a risk for complications, even with opportune diagnosis and treatment, including a minimally invasive approach, as was the case with our patient. We would like to take a moment to analyze what the main causes of those complications could have been:

Undoubtedly a factor was the patient's history of type 2 diabetes mellitus, even though the patient was supposedly well controlled. Previous glycemic controls and glycosylated hemoglobin were not available and the patient had values above 400 mg/dl upon hospital admission. This imbalance could have been secondary to the infectious process.

The laparoscopic approach as described by Aranda-Narváez et al.⁹ was employed. Open appendectomy entails a greater risk for infection of the parietal surgical site and the laparoscopic approach for organ/space infection. However, our patient developed both, a retroperitoneal abscess and soft tissue infection. With respect to the soft tissue infection, the process of specimen extraction would need to be evaluated and we had no record of it, but we did know that abundant purulent matter had been reported.

The previous management of the patient was surprising in regard to the soft tissue infection. It appears that even though 3 incisions at different sites were made, an attempt was made to be as noninvasive as possible. This simply resulted in poor infection control and its

propagation, possibly due to the fact that the incisions were very small and superficial, making the debridement of all the necrotic tissue through them unfeasible. In addition the incisions were made in the patient's room with local anesthesia and undoubtedly the discomfort that this caused the patient also hindered adequate drainage and debridement.

A meta-analysis by Sauerland et al. concluded that the laparoscopic approach could be generalized to include all patients, with surgical site infection being one of the most important aspects to consider.¹⁰ Despite the fact that there is a lower risk for soft tissue infection with the laparoscopic approach, one must not lose sight of the factors that can reduce this type of complication. They include removing the specimen inside an extraction bag (Endo Catch), a careful lavage of the abdominal cavity, and the placement of a closed drain, given that a localized abscess was encountered during appendectomy.

Funding

No financial support was received in relation to this study/article.

Conflict of interest

The authors declare that there is no conflict of interest.

References

1. Prytowsky JB, Pugh CM, Nagle AP. Appendicitis. *Curr Probl Surg.* 2005;42:694-742.
2. Cristopher D. Tratado de patología quirúrgica. La Habana: Editorial Científico-Técnica, 1983; t 1.1: 1033.
3. Schwartz SI. Appendix. Principles of surgery. 6th ed. St Louis: Mc Graw-Hill; 1994. p. 1307-18.
4. Parker MC, Ellis H, Moran BJ, et al. Postoperative adhesions: Ten-year follow-up of 12,584 patients undergoing lower abdominal surgery. *Dis Colon Rectum.* 2001;44:822-9.
5. Vons C. Peut-on traiter une appendicite aiguë par des antibiotiques et dans quelles conditions? *Journal de Chirurgie.* 2009;146:17-21.
6. Carr NJ. The pathology of acute appendicitis. *Ann Diagn Pathol.* 2000;4:46-58.
7. Mason RJ. Surgery for appendicitis: Is it necessary? *Surg Infect (Larchmt).* 2008;9:481-8.
8. Flum DR, Koepsell T. The clinical and economic correlates of misdiagnosed appendicitis: Nationwide analysis. *Arch Surg.* 2002;137:799-804.
9. Aranda-Narváez JM, Prieto-Puga Arjona T, Garcia-Albiach B, et al. Infección de sitio quirúrgico tras apendicectomía urgente: tasa global y tipo según la vía de abordaje (abierto/laparoscópica). *Enferm Infecc Microbiol Clin.* 2014;32:76-81.
10. Sauerland S, Lefering R, Neugebauer EAM. Laparoscopic versus open surgery for suspected appendicitis. *Cochrane Database Syst Rev.* 2004;CD001546.

J.A. Bahena-Aponte^{a,*}, Q. González-Contreras^b,
A. Tepeyac^b

^a Hospital General Ajusco Medio, SSA, Mexico City, Mexico

^b Hospital HMG Coyoacán, Mexico City, Mexico

* Corresponding author at: Hospital General Ajusco Medio, Encinos Número 41, Col. Ampliación Miguel Hidalgo 4ª Secc., Delegación Tlalpan, C.P. 14250 Mexico City, Mexico. Tel.: +5132-1200 Ext. 119. E-mail address: investigacionhgam@gmail.com (J.A. Bahena-Aponte).

2255-534X/

© 2016 Asociación Mexicana de Gastroenterología. Published by Masson Doyma México S.A. This is an open access article under the CC BY-NC-ND license (<http://creativecommons.org/licenses/by-nc-nd/4.0/>).

Laparoscopic treatment of hepatic choristoma in the gallbladder wall: A clinical case presentation and literature review[☆]



Coristoma hepático en pared vesicular tratado por laparoscopia. Presentación de un caso clínico y revisión de la literatura

A 37-year-old woman was admitted for intense, continuous pain in the epigastrium and right hypochondrium accompanied by nausea, vomiting, tachycardia, and diaphoresis after eating food with a high fat content. She stated that she had presented with similar symptoms that were managed medically on an outpatient basis. Physical examination revealed a body temperature of 36.8 °C, RR 18, HR 79, pulse 79, BP 130/78, signs of mild dehydration, no jaundice, no cardiopulmonary pathology, with abdominal pain at 8/10 palpation, positive Murphy's sign, negative costovertebral percussion, and the presence of peristalsis. The patient had no family history relevant to her present illness.

Liver and biliary tract ultrasound identified thickening of the gallbladder wall and gallstones. Complete blood count reported leukocytosis of 17.4×10^3 with neutrophilia. Acute calculous cholecystitis was diagnosed and laparoscopic cholecystectomy was performed. The gallbladder had multiple omental adhesions, pericholecystic fluid, and a $1 \times 0.5 \times 0.5$ cm mass with the appearance of liver tissue in the medial gallbladder wall (Fig. 1). The gallbladder was extirpated using the conventional laparoscopic technique leaving the mass intact in the wall. The histopathology report stated gallbladder with the presence of mature, subserosal liver tissue, consistent with heterotopic liver in the gallbladder wall (choristoma) and acute cholecystitis overlapping with chronic calculous cholecystitis.

Patient progression was satisfactory and she was released 48 h after the procedure.

The term choristoma refers to a neof ormation with histology of heterotopic normal tissue. There can be ectopias of different organs and tissues in the body. One of the better known is of the pancreas, which can be found in nearby areas such as the duodenum, stomach, and Meckel's appendix.

Choristomas of amygdala, lung tissue, mammary tissue and grey matter, among others, have been reported in different locations of the body, including the eye, vulva, and bone.¹⁻³

The native liver can have accessory lobes communicated by a stalk of normal liver tissue. However, there are cases of heterotopic liver tissue without vascular, biliary, or parenchymatous connections, corresponding to a choristoma. There are different theories as to the origin of this entity. The most accepted is aberrant migration of liver tissue during embryologic development. During the fourth week of embryologic development, the liver and biliary system arise from the hepatic diverticulum of the liver bud and migrate in the direction of the septum transversum. Migration abnormalities may be the main cause of this condition.⁴

The presence of ectopic liver has been reported in extra-abdominal sites such as the chest, or abdominal sites that include all possible locations. The gallbladder is the most frequent and it is mainly located on the serosa, but it can also be found on the muscular or subserosa layer, as in this case.⁵

It is difficult to evaluate the real incidence of ectopic liver tissue in the gallbladder. The reported incidence of ectopic hepatic tissue in other locations in the general population varies from 0.24-0.47%.⁴ The incidence of liver choristomas in the gallbladder is also variable. Eiserth⁶ found only 3 cases in 5500 autopsies (0.05%). More recently, Watanabe et al.⁵ reported 3 cases in 1060 laparoscopies (0.28%). To the best of our knowledge from our literature review there are only 61 histologically confirmed cases of ectopic liver tissue in the gallbladder.⁴

This disease can be associated with other congenital anomalies such as biliary atresia¹ or agenesis of the caudate lobe,⁷ but they have not been described when the heterotopic tissue is situated in the gallbladder.⁸

It can also appear together with other pathologies. Choristomas have been reported with fat infiltration, cirrhosis, or even hepatocellular carcinoma, coinciding with similar findings in the native liver.

Ectopic tissue has been observed to have a susceptibility toward carcinogenesis, probably due to the metabolic alterations associated with the lack of normal venous and biliary drainage, and therefore its surgical resection is recommended given the high risk for developing hepatocellular carcinoma. If the histopathology study confirms a malignant neoplasia, a second surgical intervention is recommended to widen the resection margins with regional lymphadenectomy.

Choristoma is generally asymptomatic, but on rare occasions it can cause acute symptoms.⁴ Its diagnosis is not simple, given the lack of its own clinical manifestations. In regard to liver choristoma in the gallbladder, symptoms

[☆] Please cite this article as: Weber-Alvarez P, Weber-Sánchez LA, Carbó-Romano R, Garteiz-Martínez D. Coristoma hepático en pared vesicular tratado por laparoscopia. Presentación de un caso clínico y revisión de la literatura. *Revista de Gastroenterología de México*. 2017;82:189-190.