



REVISTA DE GASTROENTEROLOGÍA DE MÉXICO

www.elsevier.es/rgmx



CLINICAL IMAGE IN GASTROENTEROLOGY

Disseminated plantar lentiginos associated with Peutz-Jeghers syndrome[☆]



Lentigo plantar diseminado asociado con el síndrome de Peutz-Jeghers

G.R. Medina-Murillo^{a,*}, U. Rodríguez-Medina^b, U. Rodríguez-Wong^c

^a Dermatology Service, Hospital Ángeles Lindavista, Mexico City, Mexico

^b Mexican School of Medicine, Universidad La Salle, Mexico City, Mexico

^c Gastroenterology and Coloproctology Surgery, Hospital Ángeles Lindavista, Mexico City, Mexico

A 10-year-old boy had a family history that included a father and brother with Peutz-Jeghers syndrome. His current illness began at 2 years of age with the presence of blackish hyperchromatic spots of approximately 3 mm in diameter on his lip area that increased in number and diameter (Fig. 1). From the age of 6 years hyperchromatic spots with similar characteristics appeared on his palms and on the soles of his feet, where they were present on the areas of the toes, the metatarsi, and the heels (Fig. 2). Imaging and endoscopic studies confirmed the presence of polyps in the colon and small bowel (Fig. 3). The histopathology study reported that they were of the hamartomatous type (Fig. 4). Peutz-Jeghers syndrome is characterized by the presence of numerous hamartomatous polyps distributed

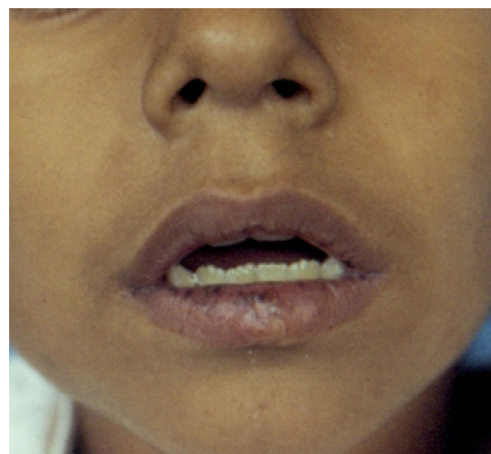

Figure 1 Hyperchromic macules on the lips.

along the entire digestive tract and a characteristic mucocutaneous hyperpigmentation that presents in 95% of the patients and is primarily located in the perioral and buccal region. Dissemination on the soles of both feet is rare.

[☆] Please cite this article as: Medina-Murillo GR, Rodríguez-Medina U, Rodríguez-Wong U. Lentigo plantar diseminado asociado con el síndrome de Peutz-Jeghers. Revista de Gastroenterología de México. 2016;82:168–169.

* Corresponding author. Hospital Ángeles Lindavista, Rio Bamba 639-330, 07760 México, D.F. Tel.: +57-54-85-04 y 57-54-84-08.

E-mail address: ruby_derma@hotmail.com
(G.R. Medina-Murillo).

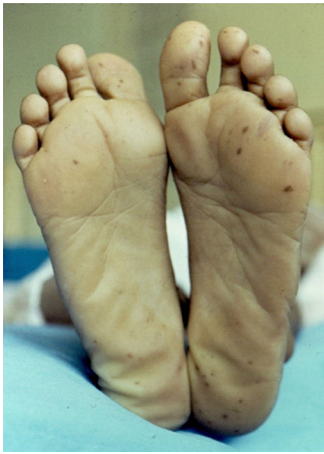

Figure 2 Disseminated plantar lentiginos associated with Peutz-Jeghers syndrome.

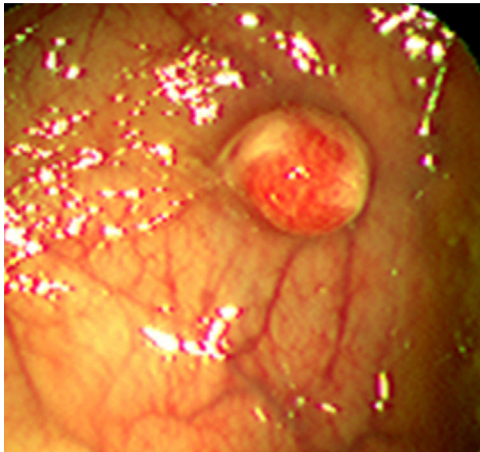


Figure 3 Endoscopic image of the hamartomatous colonic polyp in the patient.

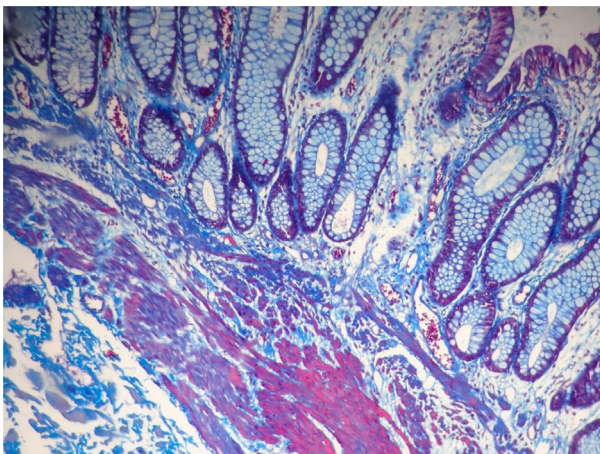


Figure 4 Medium magnification photomicrograph of the hamartomatous polyp: distorted glands separated by bands of muscle tissue of the muscularis mucosae (Masson's trichrome stain).

Ethical responsibilities

Protection of persons and animals. The authors declare that the procedures followed conformed to the ethical standards of the responsible committee on human experimentation and were in accordance with the World Medical Association and the Declaration of Helsinki.

Data confidentiality. The authors declare that they have followed the protocols of their work center in relation to the publication of patient data.

Right to privacy and informed consent. The authors have obtained the informed consent of the patients and/or subjects referred to in the article. This document is in the possession of the corresponding author.

Financial disclosure

No financial support was received in relation to this study/article.

Conflict of interest

The authors declare that there is no conflict of interest.