



SCIENTIFIC LETTERS

Sarcoidosis developing after treatment with interferon alpha in a patient with hepatitis C: An association every physician should know[☆]



Sarcoidosis posterior a tratamiento con interferón alfa en paciente con hepatitis C: una asociación que todo médico debería conocer

Sarcoidosis is a chronic granulomatous disease of unknown etiology that basically affects lung and adenopathic tissue, although it can involve any tissue.^{1–9} Its diagnosis requires the combination of clinical, radiologic, and histologic findings and treatment varies according to its severity. Interferon has been implicated in the etiology of the formation of granulomas and in 1987 the first case of sarcoidosis secondary to the use of interferon alpha was reported.³ Approximately 100 cases of sarcoidosis related to the use of interferon have been published in the literature.^{4,5} Interferon is currently a widely used therapy for the treatment of hepatitis C. We present herein the case of a 48-year-old woman that presented with pain in both knees of one-month progression. Her past history included hepatopathy from the hepatitis C virus treated with triple therapy (telaprevir + interferon + ribavirin), which ended 2 months prior to symptom onset. Physical examination revealed 2 hardened, erythematous zones above the right knee with increased local temperature and no lesions in the pretibial zone (fig. 1). The analytic parametric studies were normal (ANAs, RF, ESR, and CRP, slightly elevated ACE) and the Mantoux test was negative. Chest x-ray revealed modest perihilar thickening. It was confirmed by tomography scan that also identified adenopathic perihilar and mediastinic conglomerates. Respiratory function tests were normal. Biopsy of the nodular lesions reported changes consistent with «subcutaneous sarcoidosis» (fig. 2). Follow-up and surveillance were decided upon. The patient had clinical improvement and symptoms disappeared 6 months later. All diagnoses of sarcoidosis within the last 2 years were

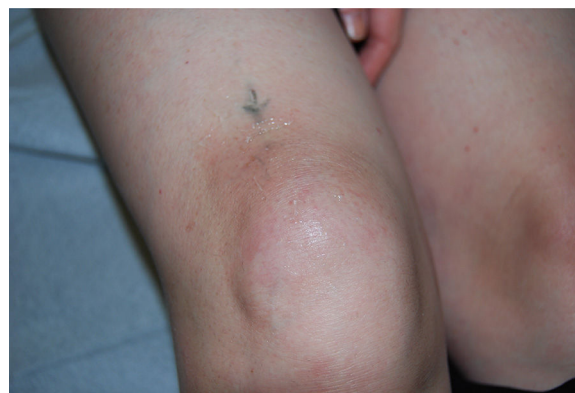

Figure 1 Hardened, erythematous zones above the right knee, with increased local temperature.

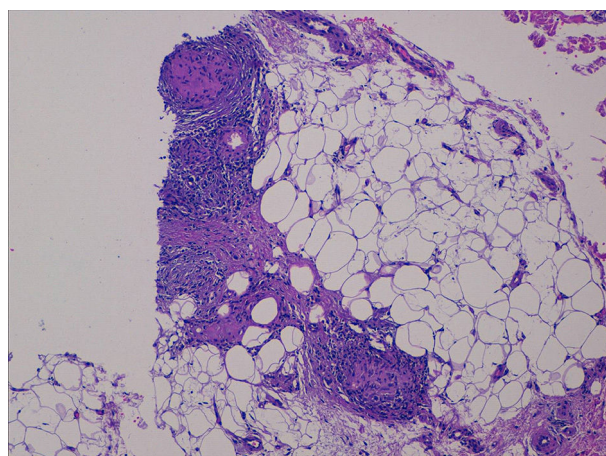


Figure 2 Non-caseating granulomas consistent «with sarcoidosis» are observed.

reviewed in our hospital database and we found no other similar case.

There is a clear relation between the appearance of sarcoidosis and interferon alpha use and various cases of sarcoidosis activation/reactivation during the disease course of patients with hepatitis C virus undergoing said treatment.^{2,4,6,9}

Symptoms can occur during treatment or up to 2 years after its suspension. Nevertheless, it is difficult to know the incidence of this entity.¹

Even though the natural history of sarcoidosis is highly variable, in one study of patients with interferon-associated

[☆] Please cite this article as: Flores-Robles BJ, Sangüesa-Gómez CP, Barbadillo Mateos C, Roustán-Gullón LG, Kovtun I. Sarcoidosis posterior a tratamiento con interferón alfa en paciente con hepatitis C: una asociación que todo médico debería conocer. Revista de Gastroenterología de México. 2017;82:185–186.

sarcoidosis, 85% of the patients were spontaneously cured and 10% of the cases became chronic, utilizing corticoids in the most severe cases.² Other treatments that have been used are hydroxychloroquine¹⁰ and infliximab.¹¹ The administration of corticoids can increase the viral burden and hepatitis C virus itself induces interferon alpha expression.¹²

It is relatively common in medical consultations to find patients with hepatitis C virus, therefore if there are symptoms that lead to suspicion of sarcoidosis, the physician must take into account the association of this entity with interferon alpha use.

Funding

No financial support was received in relation to this study/article.

Conflict of interest

The authors declare that there is no conflict of interest.

References

1. Doyle MK, Berggren R, Magnus JH. Interferon-induced sarcoidosis. *J Clin Rheumatol*. 2006;12:241–8.
2. Ramos-Casals M, Mañá J, Nardi N, et al. HISPAMEC Study Group. Sarcoidosis in patients with chronic hepatitis c virus infection. Analysis of 68 cases. *Medicine (Baltimore)*. 2005;84:69–80.
3. Hirano A, Kataoka M, Nakata Y, et al. Sarcoidosis occurring after interferon alpha therapy for chronic hepatitis C: Report of two cases. *Respirology*. 2005;10:529–34.
4. Fantini F, Padalino C, Gualdi G, et al. Cutaneous lesions as initial signs of interferon alpha-induced sarcoidosis. Report of three new cases and review of the literature. *Dermatol Ther*. 2009;22 Suppl 1:S1–7.
5. Trien R, et al. Interferon-alpha-induced sarcoidosis in a patient being treated for hepatitis C. *Am J Case Rep*. 2014;15:235–8.
6. Gayet AR, Plaisance P, Bergmann JF, et al. Development of sarcoidosis following completion of treatment for hepatitis c with

- pegylated interferon alpha and ribavirin. A case report and literature review. *Clin Med Res*. 2010;8:163–7.
7. Cardoso C, Freire R, Alves A, Oliveira A. Interferon-induced sarcoidosis. *BMJ Case Rep*. 2011;2011, bcr0320113929.
 8. Rodríguez-Lojo R, Almagro M, Barja JM, et al. Subcutaneous sarcoidosis during Pegylated interferon alfa and ribavirin treatment for chronic hepatitis C. *Dermatol Res Pract*. 2010;2010:230417.
 9. Hurst EA, Mauro T. Sarcoidosis associated with pegylated interferon alfa and ribavirin treatment for chronic hepatitis. A case report. *Arch Dermatology*. 2005;141:865–8.
 10. Jones E, Callen JP. Hydroxychloroquine is effective therapy for control of cutaneous sarcoid granulomas. *J Am Acad Dermatol*. 1990;23:487–9.
 11. Menon Y, Cucurull E, Reisin E, et al. Interferon-alpha-associated sarcoidosis responsive to infliximab therapy in: *Am J. Med Sci*. 1004, 328: 173-175.
 12. Buss G, Cattin V, Spring P, et al. Two cases of interferon-alpha-induced sarcoidosis Koebnerized along venous drainage lines: New pathogenic insights and review of the literature of interferon-induced sarcoidosis. *Dermatology*. 2013;226:289–97.

B.J. Flores-Robles^{a,*}, C.P. Sangüesa-Gómez^a,
C. Barbadillo Mateos^a, L.G. Roustán-Gullón^b, I. Kovtun^c

^a Rheumatology Service, Hospital Universitario Puerta de Hierro-Majadahonda, Majadahonda, Madrid, Spain

^b Dermatology Service, Hospital Universitario Puerta de Hierro-Majadahonda, Majadahonda, Madrid, Spain

^c Pathologic Anatomy Service, Hospital Universitario Puerta de Hierro-Majadahonda, Majadahonda, Madrid, Spain

* Corresponding author. Servicio de Reumatología, Hospital Universitario Puerta de Hierro-Majadahonda, Manuel de Falla no 1, Majadahonda, Madrid, Spain. Tel.: +695521497. E-mail address: aldolasa@hotmail.com (B.J. Flores-Robles). 2255-534X/

© 2016 Asociación Mexicana de Gastroenterología. Published by Masson Doyma México S.A. This is an open access article under the CC BY-NC-ND license (<http://creativecommons.org/licenses/by-nc-nd/4.0/>).

Severe complications of acute appendicitis with the laparoscopic approach[☆]



Complicaciones graves de apendicitis aguda con abordaje laparoscópico

Acute appendicitis is one of the surgically resolved abdominal pathologies with the highest incidence, occurring in 7%

of the general population.¹ Fortunately it has a low mortality rate under 0.1%.²⁻⁴

A 44-year-old man, who came to us from another hospital, had a relevant personal history of long progression type 2 diabetes mellitus that was apparently well controlled, and he had undergone a laparoscopic appendectomy on April 12, 2015 (38 days before we saw him). Phase III acute appendicitis was reported. It was defined as a venous infarction, total wall necrosis, and perforation, with the later formation of a localized abscess. Unfortunately, we had no detailed clinical report on the intraoperative findings or the surgical technique performed (use of antibiotic-impregnated sutures and/or preoperative asepsis and antisepsis measures). However, upon the patient's admission to our hospital, we observed a 3-port approach. One was a transumbilical port, another was at the level of the left flank, and the other was suprapubic. The first 2 had cicatrized, but abundant

[☆] Please cite this article as: Bahena-Aponte JA, González-Contreras Q, Tepeyac A. Complicaciones graves de apendicitis aguda con abordaje laparoscópico. *Revista de Gastroenterología de México*. 2017;82:186–189.