



CLINICAL IMAGE IN GASTROENTEROLOGY

Intra-abdominal synovial sarcoma[☆]

Sarcoma sinovial intraabdominal

J. Magaña-Reyes^a, L.G. Domínguez-Carrillo^{b,*}



^a Imaging Service of the Hospital Ángeles León, León, Guanajuato, Mexico

^b Rehabilitation Medicine Service, Facultad de Medicina de León, Universidad de Guanajuato, León, Guanajuato, Mexico

A 30-year-old man presented with colicky abdominal pain in the left hemiabdomen of 3-month progression along with the sensation of fullness. Physical examination revealed a hard, fixed 8 x 8 cm palpable mass in that area. Laboratory test results were normal. A contrast-enhanced abdominal computed tomography scan corroborated the presence of a mass in the left hemiabdomen. The patient underwent surgery resulting in the histologic diagnosis of synovial sarcoma (fig. 1).

Synovial sarcoma is the fourth most common type of soft-tissue sarcoma. Eighty to 95% of the cases present in the limbs. Fewer than 100 cases report it at the intra-abdominal level.¹ The histologic subtypes are: monophasic, biphasic, and poorly differentiated. They arise from transposition (X; 18) and have a high mortality rate due to local tumor extension. Histopathologic and immunohistochemical diagnosis is indispensable.² In tomography, the most frequent aspect of synovial sarcoma is that of a heterogeneous soft tissue mass with attenuation similar to that of intravenous contrast-enhanced muscle.³ Less attenuated areas repre-

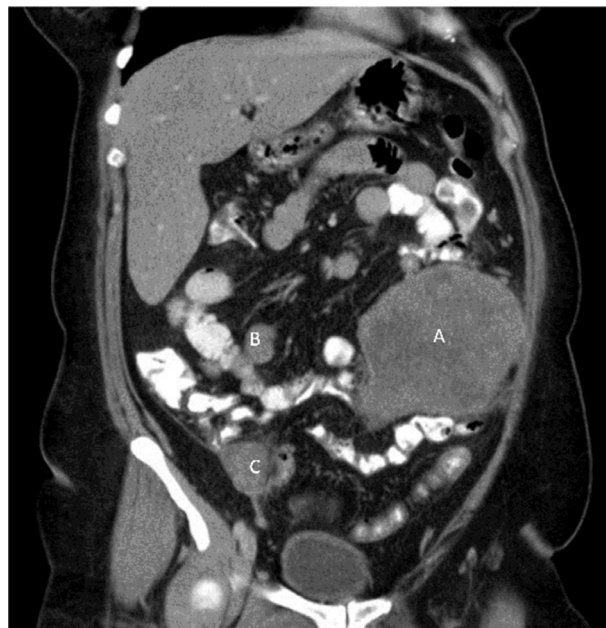


Figure 1 Contrast-enhanced coronal computed tomography multiplanar reconstruction in the venous phase showing a mass with no calcification with heterogeneous enhancement in the left hemiabdomen adjacent to the jejunal segments (A). Notice the metastatic satellite lesions with similar characteristics (B and C).

[☆] Please cite this article as: Magaña-Reyes J, Domínguez-Carrillo LG. Sarcoma sinovial intraabdominal. Revista de Gastroenterología de México. 2016;81:223–224.

* Corresponding author. Calzada Los Paraísos 701, Col. Los Paraísos. León, Gto. C.P. 37320. Tel.: +477-7185329.

E-mail address: lgdominguez@hotmail.com (L.G. Domínguez-Carrillo).

senting bleeding or necrosis are also frequent. Small lesions tend to be homogeneous and well-defined margins are found in 53% of cases.

Ethical responsibilities

Protection of persons and animals. The authors declare that no experiments were performed on humans or animals for this study.

Data confidentiality. The authors declare that no patient data appear in this article.

Right to privacy and informed consent. The authors declare that no patient data appear in this article.

Conflict of interest

The authors declare that there is no conflict of interest.

References

1. Fisher C, Folpe AL, Hashimoto H, Weiss SW. Intra-abdominal synovial sarcoma: A clinicopathological study. *Histopathology*. 2004;45:245-53.
2. Chatzipantelis P, Kafiri G. Retroperitoneal synovial sarcoma: A clinicopathological study of 6 cases. *J BUON*. 2008;13: 211-6.
3. Mahender KN, Madan R, Pathania OP, Anand R. Primary intra-abdominal synovial sarcoma. *Appl Radiol*. 2007;36, 48A-48D.