

H. pylori eradication treatment eliminates this stimulus.⁸ In addition, certain protein expression is related to good prognosis. CD-10 and BCL-6 are regarded as important markers in diagnosing germinal center B cell DLBCL and many studies have suggested that CD10 and BCL-6 expression in DLBCL predicts better overall survival rates.⁹

The treatment of DLBCL has evolved from routine gastrectomy to more conservative therapies such as radiotherapy in little more than a decade. The outcome of our case supports the suggestion in recent trials that excellent results can be obtained by treating limited-stage *H. pylori*-positive gastric DLBCL with antibiotics alone, reserving chemo-radiotherapy as an option for unresponsive patients and those with poor-prognosis.¹⁰

Financial disclosure

None.

Conflict of interest

The authors declare that they have no conflict of interests.

References

1. Herida M, Mary-Krause M, Kaphan R, et al. Incidence of non aids-defining cancers before and during the highly active antiretroviral therapy era in a cohort of human immunodeficiency virus infected patients. *J Clin Oncol*. 2003;21:3447-53.
2. Spina M, Carbone A, Vaccher E, et al. Outcome in patients with non-Hodgkin lymphoma and with or without human immunodeficiency virus infection. *Clin Infect Dis*. 2004;38:142-4.
3. Pizarro Á, García H, Riquelme A, et al. Linfomas asociados a infección por VIH en pacientes del Hospital Clínico San Borja Arriarán/Fundación Arriarán 2001-2008. *Rev Chilena Infectol*. 2013;30:23-30.
4. Ribeiro JM, Lucas M, Palhano MJ, et al. Remission of a high-grade gastric mucosa associated lymphoid tissue (MALT) lymphoma following *Helicobacter pylori* eradication and highly active

- antiretroviral therapy in a patient with AIDS. *Am J Med*. 2001;111:328-9.
5. Okame M, Takaya S, Sato H, et al. Complete regression of early-stage gastric diffuse large B-cell lymphoma in an HIV-1-infected patient following *Helicobacter pylori* eradication therapy. *Clin Infect Dis*. 2014;58:1490-2.
6. Boulanger E, Meignin V, Baia M, et al. Mucosa-associated lymphoid tissue lymphoma in patients with human immunodeficiency virus infection. *Br J Haematol*. 2008;140:464-74.
7. Kuo SH, Yeh KY, Wu MS, et al. *Helicobacter pylori* eradication therapy is effective in the treatment of early-stage *H. pylori*-positive gastric diffuse large B-cell lymphomas. *Blood*. 2012;119:4838-44.
8. Morgner A, Miehke S, Fischbach W, et al. Complete remission of primary high-grade B-cell gastric lymphoma after cure of *Helicobacter pylori* infection. *J Clin Oncol*. 2001;19:2041-8.
9. Zhang Z, Shen Y, Shen D, et al. Immunophenotype classification and therapeutic outcomes of Chinese primary gastrointestinal diffuse large B-cell lymphoma. *BMC Gastroenterol*. 2012;12:1-7.
10. Cuccurullo R, Govi S, Ferreri AJ. De-escalating therapy in gastric aggressive lymphoma. *World J Gastroenterol*. 2014;20:8993-7.

L. Verduzco-Rodríguez^a, F. Ramírez-Pérez^{b,*},
R.M. Clendenin^b, L.A. Cruz Lara^b

^a *Department of Oncology, Rio Blanco Regional Hospital, Ver., Mexico*

^b *Universidad Veracruzana, Faculty of Medicine, Campus Cd Mendoza, Ver., Mexico*

* Corresponding author at: Av. Miguel Hidalgo, Esq. Carrillo Puerto s/n, Colonia Centro, C.P. 94740, Camerino Z. Mendoza, Veracruz, Mexico.

E-mail address: fabio_k111@hotmail.com

(F. Ramírez-Pérez).

2255-534X/

© 2016 Asociación Mexicana de Gastroenterología. Published by Masson Doyma México S.A. This is an open access article under the CC BY-NC-ND license (<http://creativecommons.org/licenses/by-nc-nd/4.0/>).

Pyogenic granuloma of the jejunum; diagnosis and treatment with double-balloon enteroscopy: A case report[☆]



Granuloma piógeno de yeyuno. Diagnóstico y tratamiento con enteroscopia doble balón. Reporte de un caso

The causes of gastrointestinal bleeding of obscure origin (GIBOO) are frequently located in the small bowel,

and therefore both capsule endoscopy and double-balloon enteroscopy (DBE) can be used for identifying its etiology.

Pyogenic granuloma (PG) is an inflammatory vascular tumor that typically affects the oral cavity and skin. Digestive system involvement is a rare cause of GIBOO. We present herein a case of PG diagnosed and treated through DBE.

A 71-year-old woman had a past history of type 2 diabetes mellitus (metformin), chronic obstructive pulmonary disease (aerosol bronchodilators), congestive heart disease (hydrochlorothiazide), and coronary disease (isosorbide mononitrate). She sought medical attention for anemia of 8-month progression with no apparent bleeding. She received oral iron treatment with no response and required numerous hospitalizations for blood transfusions.

Upper gastrointestinal video endoscopy and video colonoscopy with intubation of the terminal ileum were normal. Serology for celiac disease was negative, the same as the gynecologic studies. Peripheral blood tests showed microcytic and hypochromic anemia.

[☆] Please cite this article as: De María J, Curvale C, Guidi M, Hwang H, Matanó R, Granuloma piógeno de yeyuno. Diagnóstico y tratamiento con enteroscopia doble balón. Reporte de un caso. *Revista de Gastroenterología de México*. 2017;82:94-96.

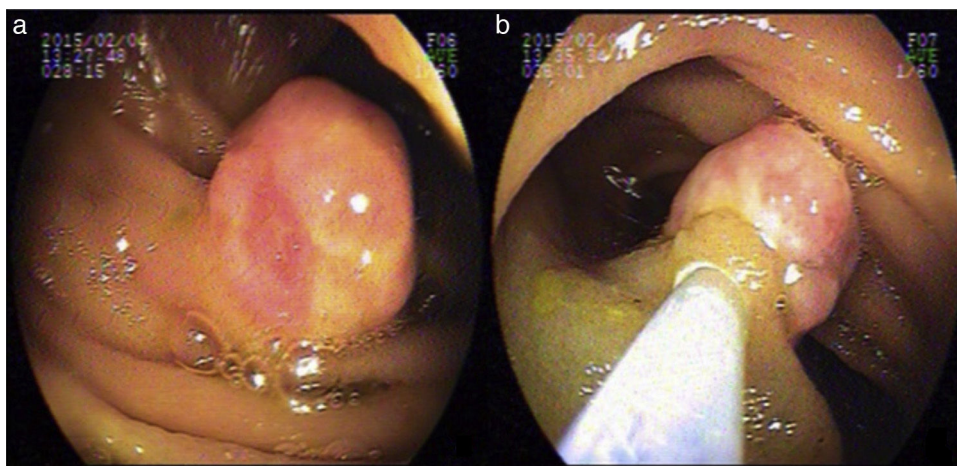


Figure 1 Double-balloon enteroscopy. a) Jejunal lesion 15 mm in diameter, and b) Injection at the base of the lesion.

Within the context of GIBOO, the decision was made to perform capsule endoscopy to study the small bowel. It had no positive findings and was considered an incomplete study reporting prolonged small bowel transit time.

Given the persistent anemia, lack of response to treatment, and the need for transfusions, the patient was referred to our Service for antegrade DBE.

During the procedure, 250 cm of small bowel were examined and a 15 mm sessile lesion covered with eroded pink mucosa was visualized 150 cm from the angle of Treitz. It was resected with a hot snare (after injection of the base with 1/20000 adrenaline) (fig. 1).

The histology study reported a polypoid formation with an epithelium with an ulcerated surface and edematous stroma with dense mixed inflammatory infiltrate accompanied by numerous neoformation vessels, scant cryptic structures with dense cellular cytoplasm, and nuclei with marked reactive changes. CD34 stain was positive for blood vessels and the diagnosis was intestinal PG. The resection margins were lesion-free (fig. 2).

After 8 months of follow-up, the patient progressed with stable hematocrit and no need for transfusion.

GIBOO is defined as gastrointestinal tract bleeding that persists or recurs with no obvious etiology after the performance of 2 gastrointestinal endoscopies (upper and lower). Capsule endoscopy enables the site of bleeding to be located and thus defines the entrance pathway of the DBE (antegrade or retrograde). DBE is a very effective therapeutic tool in the management of small bowel pathologies.¹⁻³ Capsule endoscopy provided no results in our patient and the diagnosis and treatment were established through the antegrade DBE.

PGs, also known as lobular capillary hemangiomas, are benign vascular tumors of the skin and mucosae that rarely involve the digestive system.⁴⁻⁷ Their pathophysiology implies mechanical damage. The etiology of GPs of the small bowel is unknown, unlike those located in the oral cavity and esophagus, which are presumed to be associated with damage to the mucosal layer due to foods, Barrett's esophagus, or gastroesophageal reflux.⁸ Endoscopically, they appear as

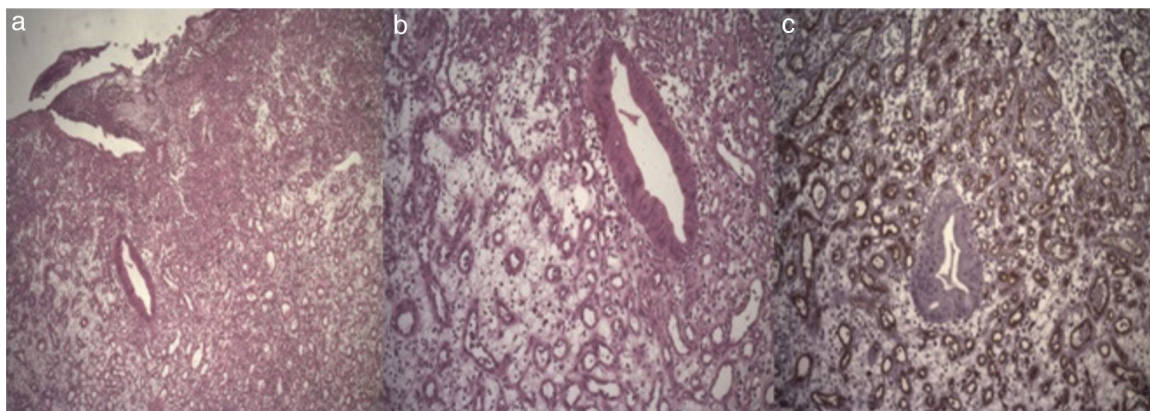


Figure 2 Histologic study of the lesion. Hematoxylin and eosin stain x4 (a), x100, (b) and marked with CD34 (c). Capillaries and vascular proliferation marked with dense mixed inflammatory infiltrate.

small, pink polyps, with a wide base and ulcers smaller than 3 cm in diameter. Some of them can bleed.⁶ The endoscopic characteristics found in our patient coincided with those reported in previous studies.

PG can originate in the mucosa or submucosa, appearing as an infiltrate of inflammatory cells and vascular proliferation.⁸

Given that these lesions are a cause of GIBOO and do not regress spontaneously, they should be treated endoscopically² or through surgery.^{3,4,7}

The anatomopathologic report of our case described complete lesion resection, including the arteriovenous anastomosis underlying the PG, which minimizes the recurrence of lesions associated with partial extractions.

Nagoya et al. reported a case of endoscopic resection in the ileum with DBE. However, they could not determine whether the vertical margins of the resection were negative.²

Nakaya et al. described persistent bleeding after biopsy and therefore its performance should be carefully considered.⁹

PG of the gastrointestinal tract is a rare condition and fewer than 30 cases have been published up to the present.¹⁻¹⁰ We believe that endoscopic polypectomy is a feasible treatment option, but because they are highly vascularized structures, the risk for bleeding at the time of extraction must be considered and additional measures of endoscopic hemostasis contemplated, such as adrenaline injection, clipping the base of the lesion, or thermal methods.

Financial disclosure

No financial support was received in relation to this article.

Conflict of interest

The authors declare that there is no conflict of interest.

Acknowledgements

The authors wish to thank the Research Area of the *Hospital "El Cruce"* Dr. Néstor Carlos Kirchner, and in particular the

physicians Maximiliano De Abreu and Laura Antonietti for their collaboration in preparing this manuscript.

References

1. Chou JW, Lai HC, Lin YC. Image of the month. Pyogenic granuloma of the small bowel diagnosed by capsule endoscopy and double-balloon enteroscopy. *Clin Gastroenterol Hepatol*. 2009;7:A26.
2. Nagoya H, Tanaka S, Tatsuguchi A, et al. Rare cause of obscure gastrointestinal bleeding due to pyogenic granuloma in the ileum detected by capsule endoscopy and treated with double balloon endoscopy. *Dig Endosc*. 2010;22:71-3.
3. Kikuchi A, Sujino T, Yamaoka M, et al. Pyogenic granuloma of the ileum diagnosed by double-balloon enteroscopy. *Intern Med*. 2014;53:2057-9.
4. Moffatt DC, Warwryko P, Singh H. Pyogenic granuloma: An unusual cause of massive gastrointestinal bleeding from the small bowel. *Can J Gastroenterol*. 2009;23:261-4.
5. Motohashi Y, Hisamatsu T, Ikezawa T, et al. A case of pyogenic granuloma in the small intestine [Article in Japanese]. *Nihon Shokakibyō Gakkai Zasshi*. 1999;96:1396-400.
6. Shirakawa K, Nakamura T, Endo M, et al. Pyogenic granuloma of the small intestine. *Gastrointest Endosc*. 2007;66:827-8, discussion 828.
7. Yamashita K, Arimura Y, Saito M, et al. Pyogenic granuloma of the small bowel. *Endoscopy*. 2013;45 Suppl 2:E9-10.
8. Van Eeden S, Offerhaus GJ, Morsink FH, et al. Pyogenic granuloma: An unrecognized cause of gastrointestinal bleeding. *Virchows Arch*. 2004;444:590-3.
9. Nakaya T, Tokunaga T, Aono S, et al. Pyogenic granuloma of the descending colon. *Endoscopy*. 2007;39 Suppl 1:E259-60.
10. Kuga R, Furuya CK, Fylyk SN, et al. Solitary pyogenic granuloma of the small bowel as the cause of obscure gastrointestinal bleeding. *Endoscopy*. 2009;41:E76-7.

J. De María, C. Curvale*, M. Guidi, H. Hwang, R. Matanó

Gastroenterology Service, Hospital de Alta Complejidad en Red El Cruce "Dr. Néstor Carlos Kirchner", Florencio Varela, Buenos Aires, Argentina

* Corresponding author. Boulogne sur Mer 478, CABA (1213), Argentina. Tel.: +54 9 11 4 0878193.

E-mail address: cecicurvale@hotmail.com (C. Curvale). 2255-534X/

© 2016 Asociación Mexicana de Gastroenterología. Published by Masson Doyma México S.A. This is an open access article under the CC BY-NC-ND license (<http://creativecommons.org/licenses/by-nc-nd/4.0/>).