

* Corresponding author at: Hospital General Ajusco Medio, Encinos Número 41, Col. Ampliación Miguel Hidalgo 4ª Secc., Delegación Tlalpan, C.P. 14250 Mexico City, Mexico. Tel.: +5132-1200 Ext. 119. E-mail address: investigacionhgam@gmail.com (J.A. Bahena-Aponte).

2255-534X/

© 2016 Asociación Mexicana de Gastroenterología. Published by Masson Doyma México S.A. This is an open access article under the CC BY-NC-ND license (<http://creativecommons.org/licenses/by-nc-nd/4.0/>).

Laparoscopic treatment of hepatic choristoma in the gallbladder wall: A clinical case presentation and literature review[☆]



Coristoma hepático en pared vesicular tratado por laparoscopia. Presentación de un caso clínico y revisión de la literatura

A 37-year-old woman was admitted for intense, continuous pain in the epigastrium and right hypochondrium accompanied by nausea, vomiting, tachycardia, and diaphoresis after eating food with a high fat content. She stated that she had presented with similar symptoms that were managed medically on an outpatient basis. Physical examination revealed a body temperature of 36.8 °C, RR 18, HR 79, pulse 79, BP 130/78, signs of mild dehydration, no jaundice, no cardiopulmonary pathology, with abdominal pain at 8/10 palpation, positive Murphy's sign, negative costovertebral percussion, and the presence of peristalsis. The patient had no family history relevant to her present illness.

Liver and biliary tract ultrasound identified thickening of the gallbladder wall and gallstones. Complete blood count reported leukocytosis of 17.4×10^3 with neutrophilia. Acute calculous cholecystitis was diagnosed and laparoscopic cholecystectomy was performed. The gallbladder had multiple omental adhesions, pericholecystic fluid, and a $1 \times 0.5 \times 0.5$ cm mass with the appearance of liver tissue in the medial gallbladder wall (Fig. 1). The gallbladder was extirpated using the conventional laparoscopic technique leaving the mass intact in the wall. The histopathology report stated gallbladder with the presence of mature, subserosal liver tissue, consistent with heterotopic liver in the gallbladder wall (choristoma) and acute cholecystitis overlapping with chronic calculous cholecystitis.

Patient progression was satisfactory and she was released 48 h after the procedure.

The term choristoma refers to a neof ormation with histology of heterotopic normal tissue. There can be ectopias of different organs and tissues in the body. One of the better known is of the pancreas, which can be found in nearby areas such as the duodenum, stomach, and Meckel's appendix.

Choristomas of amygdala, lung tissue, mammary tissue and grey matter, among others, have been reported in different locations of the body, including the eye, vulva, and bone.¹⁻³

The native liver can have accessory lobes communicated by a stalk of normal liver tissue. However, there are cases of heterotopic liver tissue without vascular, biliary, or parenchymatous connections, corresponding to a choristoma. There are different theories as to the origin of this entity. The most accepted is aberrant migration of liver tissue during embryologic development. During the fourth week of embryologic development, the liver and biliary system arise from the hepatic diverticulum of the liver bud and migrate in the direction of the septum transversum. Migration abnormalities may be the main cause of this condition.⁴

The presence of ectopic liver has been reported in extra-abdominal sites such as the chest, or abdominal sites that include all possible locations. The gallbladder is the most frequent and it is mainly located on the serosa, but it can also be found on the muscular or subserosa layer, as in this case.⁵

It is difficult to evaluate the real incidence of ectopic liver tissue in the gallbladder. The reported incidence of ectopic hepatic tissue in other locations in the general population varies from 0.24-0.47%.⁴ The incidence of liver choristomas in the gallbladder is also variable. Eiserth⁶ found only 3 cases in 5500 autopsies (0.05%). More recently, Watanabe et al.⁵ reported 3 cases in 1060 laparoscopies (0.28%). To the best of our knowledge from our literature review there are only 61 histologically confirmed cases of ectopic liver tissue in the gallbladder.⁴

This disease can be associated with other congenital anomalies such as biliary atresia¹ or agenesis of the caudate lobe,⁷ but they have not been described when the heterotopic tissue is situated in the gallbladder.⁸

It can also appear together with other pathologies. Choristomas have been reported with fat infiltration, cirrhosis, or even hepatocellular carcinoma, coinciding with similar findings in the native liver.

Ectopic tissue has been observed to have a susceptibility toward carcinogenesis, probably due to the metabolic alterations associated with the lack of normal venous and biliary drainage, and therefore its surgical resection is recommended given the high risk for developing hepatocellular carcinoma. If the histopathology study confirms a malignant neoplasia, a second surgical intervention is recommended to widen the resection margins with regional lymphadenectomy.

Choristoma is generally asymptomatic, but on rare occasions it can cause acute symptoms.⁴ Its diagnosis is not simple, given the lack of its own clinical manifestations. In regard to liver choristoma in the gallbladder, symptoms

[☆] Please cite this article as: Weber-Alvarez P, Weber-Sánchez LA, Carbó-Romano R, Garteiz-Martínez D. Coristoma hepático en pared vesicular tratado por laparoscopia. Presentación de un caso clínico y revisión de la literatura. *Revista de Gastroenterología de México*. 2017;82:189-190.

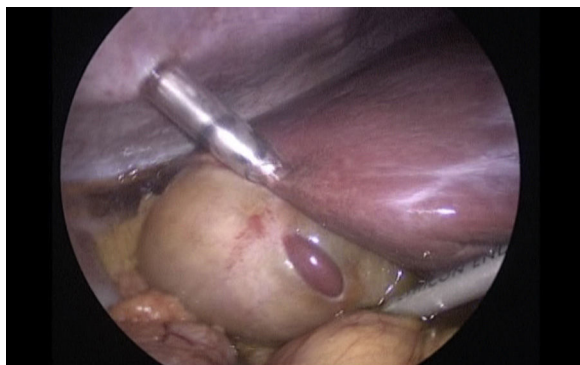


Figure 1 Gallbladder with multiple omental adhesions, pericholecystic fluid, and a 1 x 0.5 x 0.5 cm mass with the appearance of liver tissue in the medial gallbladder wall.

are frequently related to the clinical symptoms caused by gallbladder pathology and its discovery is made during the surgical intervention for that pathology, as occurred with our case. Its discovery has also been made during adult, as well as fetal, autopsies.⁶ Its own symptoms can present in cases of torsion, hemorrhagic necrosis, rupture, or compression into other structures.

Its identification through imaging studies is almost null. Of the 61 reported cases of gallbladder chorioma, only one was preoperatively diagnosed through ultrasound and another through computerized tomography and neither image was interpreted as liver tissue, but rather as a nonspecific tumor.^{9,10} Our case was not detected through ultrasound either.

Some authors are of the opinion that laparoscopic cholecystectomy has contributed to the better identification of these cases that are then confirmed in the histopathology study.⁶

Funding

No financial support was received in relation to this study/article.

Conflict of interest

The authors declare that there is no conflict of interest.

References

1. Beltrán A, Barria C, Almonacid J, et al. Coristoma hepático en la pared de la vesícula biliar. *Rev Chilena de Cirugía*. 2007;3:229–32.
2. Ringeisen AL, Wei LA, Lucarelli MJ. Orbital chorioma. *Ophthalmology*. 2015;122:1614.
3. Spalgais S, Gothi D, Verma AK. Pulmonary chorioma in a case of tuberous sclerosis complex. *J Postgrad Med*. 2015;61:193–6.
4. Martínez CA, de Resende HC Jr, Rodrigues MR, et al. Gallbladder-associated ectopic liver: A rare finding during a laparoscopic cholecystectomy. *Int J Surg Case Rep*. 2013;4:312–5.
5. Watanabe M, Matsura T, Takatori Y. Five cases of ectopic liver and a case of accessory lobe of the liver. *Endoscopy*. 1989;21:39–42.
6. Eiserth P. Beitrage zur kenntnis der nebenlebern. *Virchows Arch Pathol Anat*. 1940;207:307–13.
7. Shapiro JL, Metlay LA. Heterotopic supradiaphragmatic liver formation in association with congenital cardiac anomalies. *Arch Pathol Lab Med*. 1991;115:238–40.
8. Griniatsos J, Riaz AA, Isla MA. Two cases of ectopic liver attached to the gallbladder wall. *HPB (Oxford)*. 2002;4:191–4.
9. Arakawa M, Kimura Y, Sakata K, et al. Propensity of ectopic liver to hepatocarcinogenesis: Case reports and a review of the literature. *Hepatology*. 1999;29:57–61.
10. Lundy J, Johnson E, Edwards K, et al. Laparoscopic management of gallbladder-associated ectopic liver. *JLSLS*. 2005;9:485–7.

P. Weber-Alvarez^{a,*}, L.A. Weber-Sánchez^b,
R. Carbó-Romano^b, D. Garteiz-Martínez^b

^a Hospital Ángeles Lomas, Huixquilucan, Edo. de México, Mexico

^b Department of General Surgery, Hospital Ángeles Lomas, Huixquilucan, Edo. de México, Mexico

* Corresponding author. Vialidad de la Barranca s/n C410, Valle de las Palmas, Huixquilucan, 52763 Estado de México, México. Tel.: +52469527.

E-mail address: pbl.weber@hotmail.com

(P. Weber-Alvarez).

2255-534X/

© 2016 Asociación Mexicana de Gastroenterología. Published by Masson Doyma México S.A. This is an open access article under the CC BY-NC-ND license (<http://creativecommons.org/licenses/by-nc-nd/4.0/>).