



CLINICAL IMAGE IN GASTROENTEROLOGY

Pneumonia diagnosis in elderly patient with a bivalve shell lodged in the mid-esophagus[☆]



Diagnóstico de neumonía en paciente anciano con concha de bivalvo en esófago medio

P. López Pardo*, C. Jiménez Rojas, M. Isach Comallonga

Geriatrics Service, Hospital Central de la Cruz Roja San José y Santa Adela, Madrid, Spain

An 87-year-old man presented with the sudden onset of dysphagia for solids and liquids of one-hour progression, with nausea and vomiting, and non-radiating central thoracic oppressive pain that increased upon swallowing. He presented with dysthermia, accompanied by dyspnea upon moderate effort and coughing. He stated he had no previous choking episodes. He was evaluated in the emergency department with the following test results: 12,900 leukocytes with a leftward slant; PO₂: 52 mmHg; pH: 7.40; and PCO₂: 38 mmHg measured through arterial gasometry. He was admitted to the Geriatrics Service with right basal pneumonia and acute hypoxemic respiratory failure.

The patient was functionally independent, with no cognitive deterioration or known mental disorders. He lived alone. His past medical history included a carotid transient ischemic attack and severe aortic stenosis with left ventricular hypertrophy diagnosed 3 months prior.

Upon his admission to the service, 24h from the onset of clinical symptoms, an emergency chest x-ray was taken, given the lack of symptom improvement after medical treatment. The lateral projection revealed a foreign body

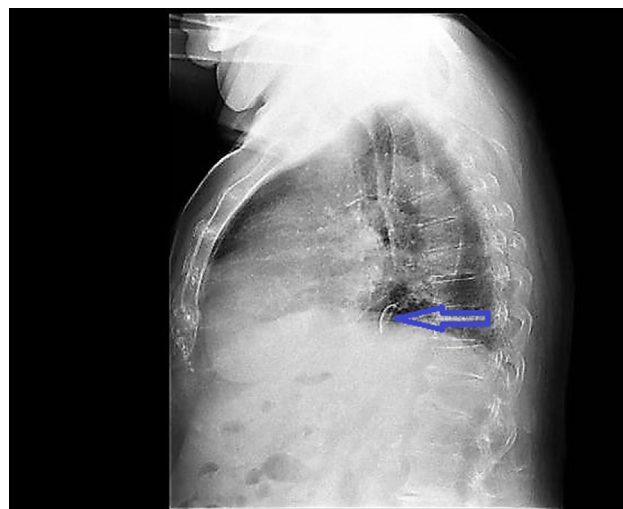


Figure 1 Lateral chest x-ray image of calcium density in the mid-esophagus, in the retrocardiac region, corresponding to a non-metallic foreign body.

[☆] Please cite this article as: López Pardo P, Jiménez Rojas C, Isach Comallonga M. Diagnóstico de neumonía en paciente anciano con concha de bivalvo en esófago medio. *Revista de Gastroenterología de México*. 2017;82:183–184.

* Corresponding author. Servicio de Geriátría, Hospital Central de la Cruz Roja San José y Santa Adela, Avenida de la Reina Victoria N.º 24, Madrid, Spain. Tel.: +34646071130; fax: (+34) 914 536 538. E-mail address: plpardo@hotmail.com (P. López Pardo).

anterior to the ascending aorta (fig. 1), with no consolidation at the base of the right lung (fig. 2). Upper gastrointestinal endoscopy was performed that identified a bivalve shell in the mid-esophagus (fig. 3) with edematous and erythematous esophageal mucosa, and a small ulcer. The shell was extracted with a polypectomy basket, resolving the symptoms.

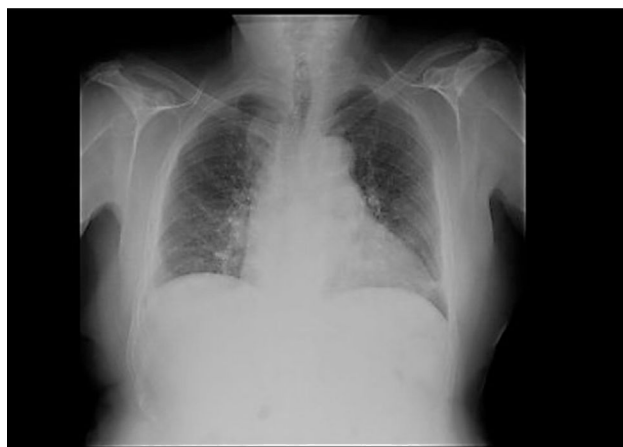

Figure 2 Posteroanterior chest x-ray with atelectasis in the lower left lobe of the lung.

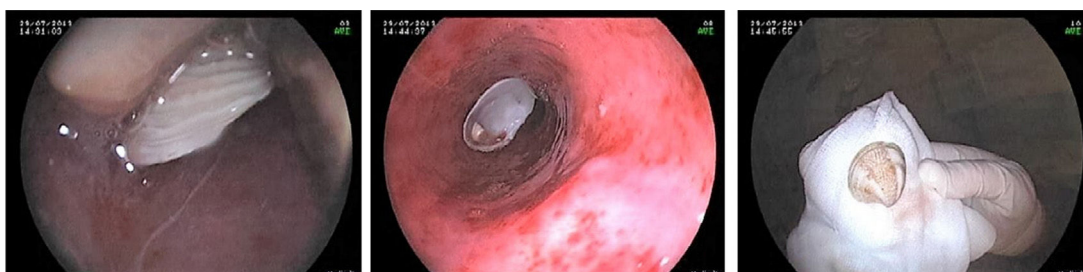


Figure 3 Endoscopic diagnosis: extraction of the foreign body (Venus clam shell) in the mid-esophagus. Hiatal hernia.

Ethical disclosures

Protection of human and animal subjects. The authors declare that the procedures followed were in accordance with the regulations of the relevant clinical research ethics committee and with those of the Code of Ethics of the World Medical Association (Declaration of Helsinki).

Confidentiality of data. The authors declare that no patient data appear in this article.

Right to privacy and informed consent. The authors declare that no patient data appear in this article.

Funding

No financial support was received in relation to this study.

Conflict of interest

The authors declare that there is no conflict of interest.

Acknowledgments

The authors wish to thank the gastroenterologists that participated in the study.