

Olmesartan-associated sprue-like enteropathy: An emerging cause of drug-induced chronic diarrhea[☆]



Enteropatía *sprue-like* asociada a olmesartán: causa emergente de diarrea crónica asociada a fármacos

A 72-year-old woman with no medication allergies had a past history of diabetes mellitus, hypercholesterolemia, high blood pressure, a ventriculoperitoneal shunt due to subarachnoid hemorrhage after a ruptured aneurysm, and atrophied chronic gastritis. She received eradication therapy for positive *Helicobacter pylori*, has a history of iron-deficiency anemia of at least 4-year known progression that is treated empirically, and continues treatment with omeprazole, insulin, metformin, olmesartan, nebivolol, and oral iron.

She was admitted to our service for the first time due to symptoms of 2-week progression of 5-10 diarrheic, watery stools per day, with no blood, mucus, or pus, and no fever. Her chronic anemia worsened (hemoglobin 9.4 mg/dl; usual values were around 11 mg/dl). Upper and lower endoscopic study identified atrophied chronic gastritis with no other alterations. Biopsy was not taken. Stool cultures were negative. After metformin was suspended as a possible triggering factor and the corresponding insulin readjustment was made, the diarrhea disappeared and the patient was released.

She was readmitted 2 months later because the diarrhea reappeared with similar characteristics. At physical examination, the patient had low blood pressure (89/56 mmHg), was pale, and presented with oligoanuria, all in the context of hypovolemic shock secondary to gastrointestinal losses, requiring treatment in the intensive care unit. Laboratory work-up: urea 197 mg/dl, creatinine 3.51 mg/dl, sodium 150 mmol/l, and potassium 5.24 mmol/l; hemoglobin 9.8 mg/dl, MCV 80 fl, and iron 15 µg/dl. Once she was clinically stable, thorough testing was undertaken, with the following results: liver function, folic acid, vitamin B12, thyroid hormones, basal cortisol, serum proteinogram, glycosylated hemoglobin, and digestion in feces were all normal. Stool cultures, stool ova and parasite exam, *Clostridium difficile* toxin, ANA, ANCA, and anti-transglutaminase IgA antibody (0.30 U/ml [reference values < 7 U/ml]) tests were all negative. No significant alterations were observed in the chest x-ray, abdominopelvic CAT scan, or bowel transit. Endoscopic study was repeated with biopsy from the second portion of the duodenum and the bulb, where partial atrophy with a villous pattern (fig. 1) with increased intraepithelial lymphocytes (modified Marsh 3b)¹ was observed (fig. 2).

With fluid and electrolyte resuscitation and a gluten-free diet, the laboratory test parameters normalized within 3 weeks and the number of stools decreased significantly and

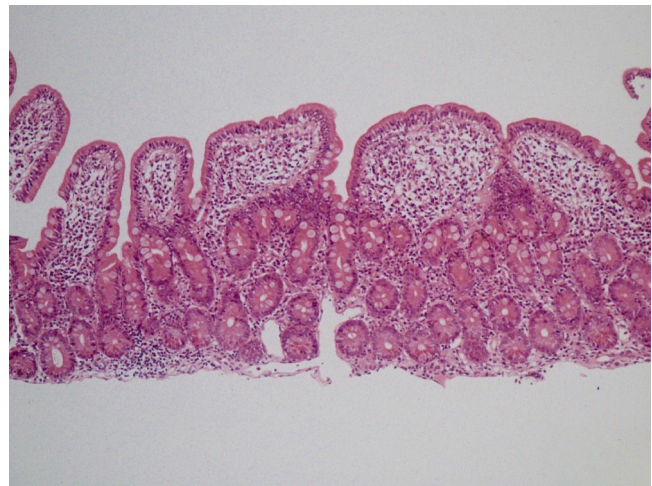


Figure 1 Intraepithelial lymphocytosis associated with loss of mucus secretion vacuoles, glandular crypt hyperplasia, and moderate villous atrophy (H&E x20).

their consistency increased. Once the patient's blood pressure figures stabilized, the antihypertensive medication was reintroduced and the watery diarrhea reappeared. Under those circumstances, we interpreted the symptoms as sprue-like enteropathy, associated with olmesartan (which she had been taking for 3 years at a dose of 40 mg daily). The olmesartan was suspended and substituted with verapamil. Six months after that suspension, the patient continues to be asymptomatic.

Olmesartan is an angiotensin receptor II selective blocker (ARB) that is commonly used to treat high blood pressure. Since July 2013, its label states sprue-like intestinal alterations as an adverse reaction to the medication.² Increasingly more cases associated with its use are being described, but not with other ARBs.³ Olmesartan should be included in the differential diagnosis in cases of chronic diarrhea with repeatedly negative serologic celiac disease tests.⁴

The causal mechanism of this pathology is unknown,⁵ but it could be due to an immunologic lesion, with elevated CD8+ and IL15 overexpression on the part of epithelial

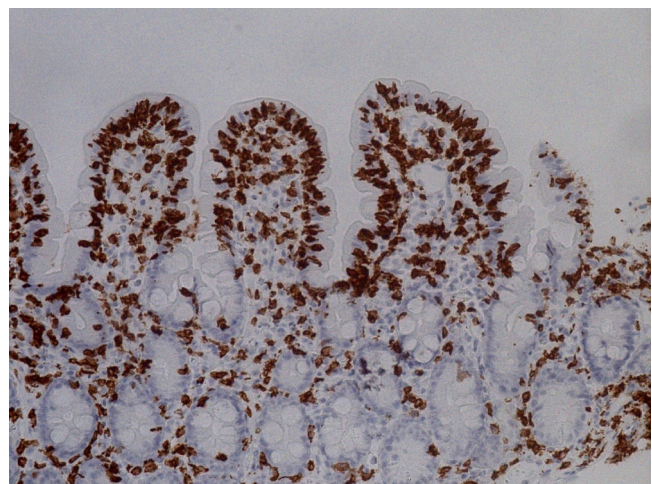


Figure 2 Intraepithelial lymphocytosis (> 30 lymphocytes/100 enterocytes) (IHC-CD3, x40).

[☆] Please cite this article as: Solano-Iturri G, García-Jiménez N, Solano-Iturri JD, Blanco-Sampascual S. Enteropatía *sprue-like* asociada a olmesartán: causa emergente de diarrea crónica asociada a fármacos. Revista de Gastroenterología de México. 2018;83:71-72.

cells.⁶ Villous atrophy and intraepithelial lymphocyte infiltration characteristic of celiac disease can be seen in other situations, such as bacterial overgrowth, Crohn's disease, intestinal lymphoma, or drug treatment,⁷ highlighting mofetil mycophenolate, azathioprine,⁸ and olmesartan, as was the case of our patient. Not only symptoms, but also histologic alterations, have been observed to remit with the suspension of the drug.⁹ Given our patient's good progression, intestinal biopsy has not been repeated. According to the Naranjo algorithm, causality was considered probable (7 points), and was reported to the Spanish Drug Surveillance Agency.

We therefore consider it essential to include this entity in the differential diagnosis of chronic diarrheic syndromes of unclear etiology, emphasizing the performance of a thorough anamnesis, including the detailed review of chronic drug treatments of patients, given that the associated complications can be potentially severe.

Financial disclosure

No financial support was received in relation to this study.

Conflict of interest

The authors declare that there is no conflict of interest.

References

- Rostom A, Murray JA, Kagnoff MF. American Gastroenterological Association (AGA) Institute technical review on the diagnosis and management of celiac disease. *Gastroenterology*. 2006;131:1981–2002.
- U.S. Food and Drug Administration. FDA Drug Safety Communication: FDA approves label changes to include intestinal problems (sprue-like enteropathy) linked to blood pressure medicine olmesartan medoxomil. 2013 [accessed 1 Mar 2014]. Available from: <http://www.fda.gov/Drugs/DrugSafety/ucm359477.htm>
- Lebwohl B, Ludvigsson JF. Sprue-like enteropathy due to olmesartan and other angiotensin receptor blockers – the plot thickens. *Aliment Pharmacol Ther*. 2014;40:1245–6.
- Ianiro G1, Bibbò S, Montalto M, et al. Systematic review: Sprue-like enteropathy associated with olmesartan. *Aliment Pharmacol Ther*. 2014;40:16–23.
- Rubio-Tapia A, Herman ML, Ludvigsson JF, et al. Severe sprue-like enteropathy associated with olmesartan. *Mayo Clin Proc*. 2012;87:732–8.
- Marietta EV, Nadeau AM, Cartee AK, et al. Immunopathogenesis of olmesartan-associated enteropathy. *Aliment Pharmacol Ther*. 2015;42:1303–14.
- DeGaetani M, Tennyson CA, Lebwohl B, et al. Villous atrophy and negative celiac serology: A diagnostic and therapeutic dilemma. *Am J Gastroenterol*. 2013;108:647–53.
- Seminario J, McGrath K, Arnold CA, et al. Medication-associated lesions of the GI tract. *Gastrointest Endosc*. 2014;79:140–50.
- Nielsen JA, Steephen A, Lewin M. Angiotensin-II inhibitor (olmesartan)-induced collagenous sprue with resolution following discontinuation of drug. *World J Gastroenterol*. 2013;19:6928–30.

G. Solano-Iturri^{a,*}, N. García-Jiménez^a, J.D. Solano-Iturri^b, S. Blanco-Sampascual^c

^a Internal Medicine Service, Hospital Universitario de Basurto, Bilbao, Vizcaya, Spain

^b Pathologic Anatomy Service, Hospital Universitario de Basurto, Bilbao, Vizcaya, Spain

^c Digestive Tract Service, Hospital Universitario de Basurto, Bilbao, Vizcaya, Spain

* Corresponding author. Hospital de Basurto, Avda. Montevideo 18, 48013 Bilbao, Vizcaya, Spain.

Tel.: +44006000 (extension 5468); fax: +946014514.

E-mail address: goizalnaz@gmail.com (G. Solano-Iturri). 2255-534X/

© 2017 Asociación Mexicana de Gastroenterología. Published by Masson Doyma México S.A. This is an open access article under the CC BY-NC-ND license (<http://creativecommons.org/licenses/by-nc-nd/4.0/>).

Gastric glomangioma, differential diagnosis of gastrointestinal stromal tumors[☆]



Glomangioma gástrico, diagnóstico diferencial de tumores del estroma gastrointestinal

Glomus tumors originate from smooth muscle cells of the glomus bodies that help regulate arteriolar flow. They are

mesenchymal tumors with malignant potential.¹ Though infrequent, malignant gastric glomus tumors with metastasis to different organs have been reported.²

A 52-year-old man presented with intermittent abdominal pain in the epigastrium of several months' progression, with partial response to medical treatment. He did not complain of fever, vomiting, constipation, diarrhea, weight loss, or any other systemic symptomatology. Physical examination revealed normal vital signs and no cardiopulmonary alterations. He had pain in the upper hemiabdomen upon deep palpation, no peritoneal irritation, and no other pathologic signs.

Endoscopy showed an ulcerated subepithelial tumor in the posterior wall of the gastric antrum. No abnormalities in the gastric mucosa were reported in the endoscopic biopsy. Endoscopic ultrasound (EUS) identified a 3 x 2.5 cm nodular, hypoechoic, heterogeneous tumor located in the muscular layer of the gastric wall, through Doppler imaging, with interior vascularity. The EUS data were consistent with a gastrointestinal stromal tumor (GIST) (fig. 1).

[☆] Please cite this article as: Rosales-López E, Salceda-Otero JC, Angulo-Molina D, Posada-Torres JA, Canchola-Aguilar MG, Lozoya-Gonzalez D. Glomangioma gástrico, diagnóstico diferencial de tumores del estroma gastrointestinal. *Revista de Gastroenterología de México*. 2018;83:72–74.