




REVISTA DE GASTROENTEROLOGÍA DE MÉXICO

www.elsevier.es/rgmx



SCIENTIFIC LETTERS

Esophagitis caused by L-arginine capsule retention: Presentation of four cases[☆]



Esofagitis causada por la retención de cápsulas de L-arginina. Presentación de 4 casos

In 1970, Pemberton¹ first published esophageal lesions produced by the ingestion of potassium chloride pills. Since then, reports of lesions caused by other substances, mainly antibiotics, nonsteroidal anti-inflammatory agents, and antihypertensive drugs, among others,^{2,3} have multiplied. We present herein the endoscopic lesions found in the esophagi of 4 adolescents that ingested L-arginine, their cause, and how to prevent them.

An 11-year-old girl was taking L-arginine to increase her height. After taking the drug with very little water, she presented with retrosternal pain, nausea, vomiting, dysphagia for solids, and odynophagia for liquids. Endoscopy revealed a 2-cm ulcer with irregular edges covered in fibrin and another smaller mirror-image, or “kissing”, ulcer in the middle third of the esophagus. She was managed with fasting, omeprazole, and steroids. She tolerated liquids within 2 days, and then solids. Symptomatology disappeared in 10 days.

A 14-year-old girl was taking 500 mg of L-arginine for 4 months because she was in the 10th weight and height percentile. Two days prior to the endoscopy study, she took a capsule with a small amount of water before bed. She woke up with intense retrosternal pain and progressive dysphagia, even for swallowing. Because the symptoms persisted she underwent endoscopy that showed mirror-image ulcers of 1 cm with irregular edges, covered in fibrin, in the middle third of the esophagus, and others in the distal esophagus. She was managed with a liquid diet, omeprazole, and sucralfate. She improved and her symptoms disappeared 4 days later.

A 13-year-old girl was taking 500 mg of L-arginine every 24 h to increase her height. She ingested a capsule with very little water and the next morning she presented with intense retrosternal pain, nausea, odynophagia for liquids, and dysphagia for solids. Endoscopy revealed a 2.5 cm ulcer with raised edges covered with fibrin and another smaller

mirror-image ulcer in the middle third of the esophagus (fig. 1). She was managed with a liquid diet, omeprazole, and sucralfate. Symptomatology disappeared in 10 days.

An 11-year-old boy was taking 500 mg of L-arginine every 24 h to increase his height, which was stunted due to renal tubular acidosis. He took the capsule at night with a small amount of water. In the morning, he complained of intense retrosternal and precordial pain, hyporexia, vomiting, and dysphagia for solids. Endoscopy showed an ulcer measuring approximately 1.5 cm with irregular edges covered in fibrin and another smaller mirror-image ulcer at the level of the middle third of the esophagus, and linear fibrin plaque at the proximal third (fig. 2). He was managed with a bland and liquid diet, omeprazole, sucralfate, and steroids for 72 h. Symptomatology disappeared 5 days later.

The exact mechanism through which these substances produce the esophageal lesion is unknown. It has been suggested that gastroesophageal reflux, immunosuppression, and infection can favor lesion presentation, or that direct contact of the substance, being corrosive, produces mucosal damage or a hyperosmolar cytotoxic effect.^{4–6} The causes that have been reported to promote medication retention are: taking it without a liquid, or with very little, and ingesting it before going to bed, with the consequent decubitus position aiding retention, as well as the fact that capsules

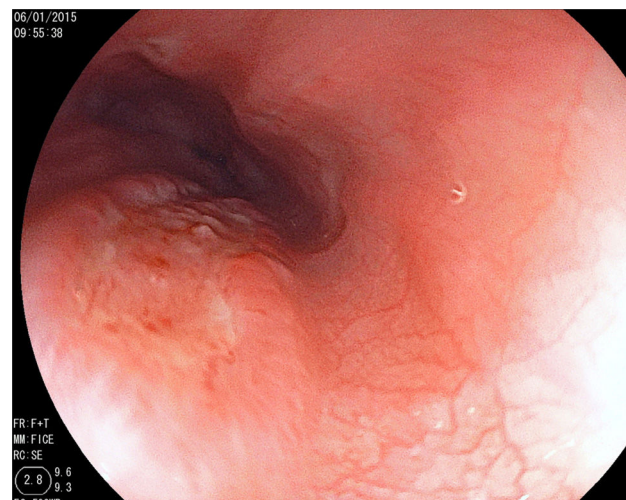


Figure 1 An ulcer measuring approximately 2 cm, with raised edges covered with a scant quantity of fibrin, and another smaller mirror-image ulcer are shown.

[☆] Please cite this article as: Blanco-Rodríguez G, Reyes-Retana R, Varela-Fascinetto G, Graham-Pontones S. Esofagitis causada por la retención de cápsulas de L-arginina. Presentación de 4 casos. *Revista de Gastroenterología de México*. 2018;83:196–197.

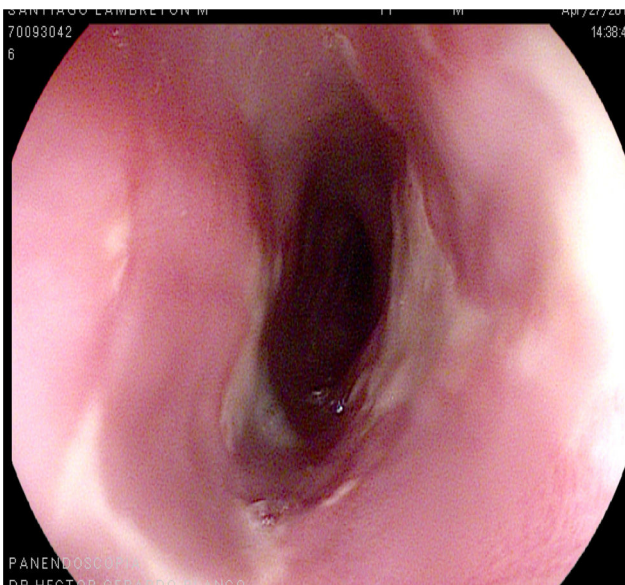


Figure 2 An ulcer measuring approximately 1.5 cm covered in fibrin with irregular edges and another smaller mirror-image ulcer are shown, along with other proximal fibrin zones.

are lighter and have a stickier surface than tablets, making them easier to become lodged.^{1,5,6} Diagnosis in the majority of cases is clinical, given that there is a correlation between product ingestion and symptom onset,⁷ such as: intense retrosternal pain, odynophagia, dysphagia, vomiting, and hematemesis. The first 2 are the most frequent and they increase upon swallowing liquids or solids.^{1,5,7} That history and the acute clinical symptoms are sufficient for making the diagnosis and endoscopy is not always required.⁶ However, performing the study enables the lesions to be viewed and the pill to be removed when whole, or eliminate its remnants when present. The mucosal lesions are found mainly in the middle third of the esophagus, because the compression of the callus of the aorta on the esophagus reduces the diameter of its lumen. This is favored by the decubitus position when sleeping. Mucosal lesions include: erythema, whitish exudate, erosions, solitary or multiple mirror-image ulcers, with or without exudate, friability of the mucosa, thickening of the esophageal wall, and less frequently, hemorrhagic zones.^{3,5,7} Our patients were treated with fasting, suspension of the medication, and the empirical use of local anesthetics, proton pump inhibitors, and sucralfate, with good results.³⁻⁵ L-arginine is a natural amino acid that is used to increase muscle volume. Its effect is based on increasing the blood flow, the quantity of nitric oxide in the blood, and potentiating the release of the growth hormone.⁸ It has been administered to some patients to promote growth, but its usefulness has not been

demonstrated in controlled trials.⁹ It is considered a weak acid and so its pathogenic effect is corrosive. We have found 2 previously reported cases.^{4,8} To prevent this lesion, patients and their relatives must be advised to take the medication with abundant liquid (100 ml), while sitting or standing, and to wait at least 10-15 min before lying down.^{1,3,7}

Conflict of interest

The authors declare that there is no conflict of interest.

References

1. Boyce HW. Drug-induced esophageal damage: Diseases of medical progress. *Gastrointest Endosc.* 1998;47:547-50.
2. Chen Z, Scudiere JR, Montgomery E. Medication-induced upper gastrointestinal tract injury. *J Clin Pathol.* 2009;62:113-9.
3. Zografos GN, Georgiadou D, Thomas D, et al. Drug-induced esophagitis. *Dis Esophagus.* 2009;22:633-7.
4. Marín-Pineda R, Rodríguez-Aguilera ML, Leyva-Bohórquez PC. Úlceras esofágica inducida por L-arginina: informe de un caso. *Endoscopia.* 2015;27:84-6.
5. Abid S, Mumtaz K, Jafri W, et al. Pill-Induced esophageal injury: Endoscopic features and clinical outcomes. *Endoscopy.* 2005;37:740-4.
6. Seminerio J, McGrath K, Arnold CA, et al. Medication-associated lesions of GI tract. *Gastrointest Endosc.* 2014;79:140-51.
7. Kikendall JW. Pill esophagitis. *J Clin Gastroenterol.* 1999;28:298-305.
8. Gallego Pérez B, Martínez Crespo JJ, García Belmonte D, et al. Úlceras esofágica por comprimido de L-arginina: causa no comunicada previamente de esofagitis por comprimidos. *Farm Hosp.* 2014;6:486-97.
9. Blazejwski S, Georges A, Forest K, et al. The chronic oral administration of arginine aspartate decreases secretion of IGF-1 and IGFBP-3 in healthy volunteers. *Fundam Clin Pharmacol.* 2009;23:339-44.

G. Blanco-Rodríguez^{a,*}, R. Reyes-Retana^b,
G. Varela-Fascinetto^b, S. Graham-Pontones^c

^a *Pediatric Endoscopist, Mexico City, Mexico*

^b *Pediatric Surgeon, Mexico City, Mexico*

^c *Pediatrician, Mexico City, Mexico*

*Corresponding author. Petén 25 int. 301, Col. Narvarte, C.P. 03020 Mexico City, Mexico. Tel.: +4404497; fax: +55781701.

E-mail address: gerardoblancor@yahoo.com.mx

(G. Blanco-Rodríguez).

2255-534X/

© 2017 Asociación Mexicana de Gastroenterología. Published by Masson Doyma México S.A. This is an open access article under the CC BY-NC-ND license (<http://creativecommons.org/licenses/by-nc-nd/4.0/>).