

- mentales à *Trichomonas vaginalis*. *Ann Inst Pasteur (Paris)*. 1959;96:238–41.
29. Cosar C, Ganter P, Julou L. Etude expérimentale du metronidazole (8823 RP). Activités trichomonacide et amoebicide. Toxicité et propriétés pharmacologiques générales. *Prese Medica*. 1961;69:1069–72.
 30. Powell SJ, MacLeod I, Wilmot AJ, et al. Metronidazole in amoebic dysentery and amoebic liver abscess. *Lancet*. 1966;2:1329–31.
 31. Powel SJ. Therapy of amebiasis. *Bull NY Acad Med*. 1971;47:469–77.
 32. Sepúlveda B. Hemagglutination and precipitation reactions with axenic amoebic antigen in invasive amebiasis. *Arch Invest Med (Mex)*. 1970;1 Suppl:111–6.
 33. Sepúlveda B. Progress in amebiasis. *Scand J Gastroenterol*. 1982;77:153–64.
 34. Pérez-Tamayo R. Amibiasis hepática. *Rev Gastroenterol Mex*. 2006;71 Supl 2:47–72.
 35. Escandón-Romero C, Treviño N, Escobedo J, et al. La amibiasis y el absceso hepático amebiano en México, un problema de salud pública de actualidad. *Rev Gastroenterol Mex*. 1996;61:378–86.
 36. Conde BC, De la Mora ZC. *Entamoeba histolytica*: un desafío vigente. *Salud Pública Méx*. 1992; 34:335–41.
 37. Martínez-Palomo A, Espinosa-Cantellano M. Amebiasis and other protozoan infections. In: Cohen J, Powerly WG, editors. *Infectious diseases*. 2.^a ed. Londres: Elsevier; 2004. p. 1567-1571.
 38. Martínez-Palomo A. *The biology of Entamoeba histolytica*. Chichester: Research Studies Press/John Wiley; 1982.
 39. Martínez-Palomo A, ed. *Amebiasis*. México: Médica Panamericana; 1989.
 40. Tanimoto M, Sigler L, Treviño N, et al. Amibiasis. ¿Ha variado su expresión clínica? *Rev Gastroenterol Mex*. 2006;71:Supl. 2:163-166.
 41. Gaxiola R. History of amoebic liver abscess in Mexico. *Prensa Med Mex*. 1969;34:427–37.
 42. Stoopon M, Casal R, Elizondo L, et al. Las alteraciones angiográficas del absceso hepático amebiano estudio de 60 casos. *Rev Mex Radol*. 1969;23:9–22.
 43. Stoopon M, Elizondo L, Landa L. Estado actual del diagnóstico radiológico en la amebiasis. *Arch Invest Med Mex*. 1972;3:387–402.
 44. Stoopon M, Hori S, Diaz Lopez A, et al. Evaluation de la utilidad de la tomografía computada en el diagnóstico del absceso hepático (informe preliminar). *Rev Gastroenterol Mex*. 1979;44:239.
 45. Stoopon M, Kimura K. La tecnología de los ochentas. Ultrasonido, tomografía computada y resonancia magnética: ¿han contribuido a mejorar el diagnóstico del absceso hepático? *Rev Gastroenterol Mex*. 1989;54:167–75.
 46. Clark CG, Diamond LS. The Laredo strain and other *Entamoeba histolytica*-like amoebae are *Entamoeba moshkovskii*. *Mol Biochem Parasitol*. 1991;46:11–8.
 47. Haque R, Huston CD, Hughes M, et al. Amebiasis. *N Engl J Med*. 2003;348:1565–73.
 48. Loftus B, Anderson I, Davies R, et al. The genome of the protist parasite *Entamoeba histolytica*. *Nature*. 2005;433:865–8.
- G. Arellano-Aguilar^{a,*}, E. Marín-Santillán^b,
J.A. Castilla-Barajas^b, M.C. Bribiesca-Juárez^b,
L.G. Domínguez-Carrillo^c
- ^a Internal Medicine Division, Hospital Ángeles León, León, Guanajuato, Mexico
^b Surgery Division, Hospital Ángeles León, León, Guanajuato, Mexico
^c School of Medicine, Universidad de Guanajuato, León, Guanajuato, Mexico
- * Corresponding author. Hospital Ángeles León, Av. Cerro Gordo 311, León, Guanajuato, Mexico.
Tel.: (+52) 477-788-5600.
E-mail address: gregareag@gmail.com (G. Arellano-Aguilar). 2255-534X/
- © 2017 Asociación Mexicana de Gastroenterología. Published by Masson Doyma México S.A. This is an open access article under the CC BY-NC-ND license (<http://creativecommons.org/licenses/by-nc-nd/4.0/>).

A giant mesenteric cyst mimicking untreatable ascites[☆]



Quiste mesentérico gigante simulador de ascitis intratable

Mesenteric cysts are very rare intra-abdominal tumors with a minimum of clinical symptoms, making their preoperative diagnosis difficult. Diagnosis is generally made through abdominal ultrasound or computed tomography studies. The differential diagnosis should be made with other abdominal or retroperitoneal tumors. Treatment is surgical, with complete resection of the cyst through laparotomy or laparoscopy.

Given that this type of lesion is not often contemplated preoperatively and that its symptomatology can be very ambiguous, we present herein the case of a giant mesenteric cyst whose diagnosis was suspected in the preoperative period, but had previously been confused with another pathology.

A 65-year-old housewife with an obstetric history of gravida 1, para 0, abortus 1, cesarean section 0, had a ruptured ectopic pregnancy at 30 years of age for which she underwent an exploratory laparotomy with profuse intraoperative blood loss and several transfusions in the postoperative period. Her current illness had a 2-year progression and began with gradual, nonpainful abdominal growth that eventually became incapacitating. It caused dyspnea in the dorsal decubitus position, the patient was unable to get up on her own, and it limited her walking due to respiratory difficulty.

She was examined and managed by a general practitioner, who after numerous failed treatments with diuretics for apparent progressive ascites, referred her for control and management of cirrhosis due to post-transfusional hepatitis.

[☆] Please cite this article as: Vallejo-Soto M, Orozco-Simental S. Quiste mesentérico gigante simulador de ascitis intratable. *Revista de Gastroenterología de México*. 2017;82:348–351.

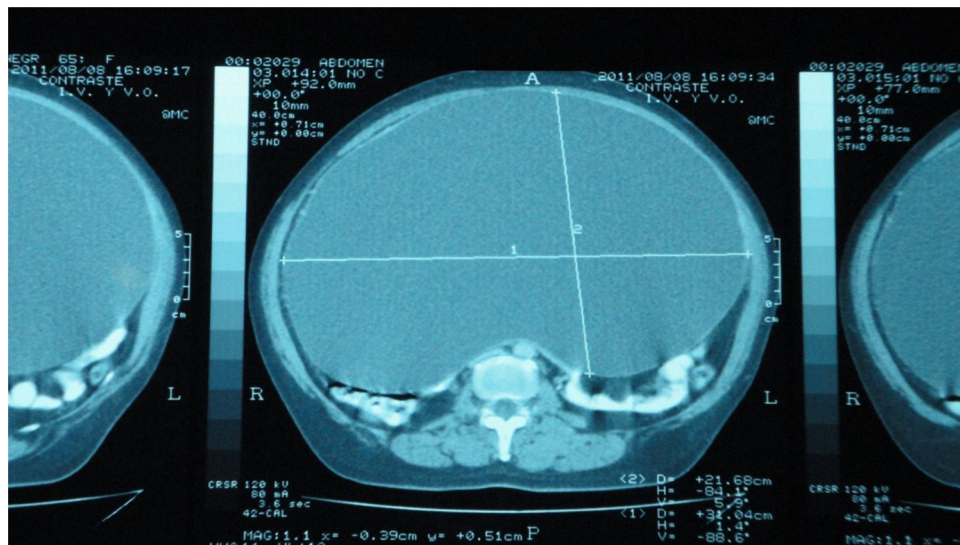


Figure 1 Abdominal computed axial tomography scan that reveals the large size of the mesenteric cyst, displacing the entire intra-abdominal content upwards and behind the abdomen, measuring 31 x 21 cm.

At her referral consultation, the patient presented with dyspnea after slight physical exertion, no cachexia or jaundice, and with an important increase and tension in abdominal volume, but no signs of chronic hepatopathy.

Complete blood count, blood chemistry, and liver function tests were ordered, all of which were normal. There were no indications of liver failure or thrombocytopenia due to hypersplenism. Ultrasound study was ruled out because the possibility of an intra-abdominal tumor was contemplated, and non-contrast and contrast-enhanced abdominal computed tomography scans were carried out instead. They revealed a liver with normal consistency and morphology, but that was importantly displaced toward the upper abdomen by a large, fluid-containing, thin-walled intra-abdominal mass that moved all the intra-abdominal viscera from their usual positions and took up the entire abdominal cavity. The preoperative diagnostic suspicion was a giant mesenteric cyst (figs. 1 and 2).

Having ruled out chronic hepatopathy, and given that the patient had normal coagulation tests, open laparotomy was performed. It revealed a giant mesenteric cyst that was not attached to any viscera and was only being nourished through its pedicle, which arose from the mesentery of the rectosigmoid colon. The patient had no alterations during the immediate postoperative period and was released from the hospital on the second day after surgery, tolerating oral diet well.

The histopathology study corresponded to: mesenteric (mesothelial) cyst.

Mesenteric cysts are very rare intra-abdominal cystic tumors with a prevalence from 1:100,000 to 1:250,000 of hospitalizations in adults and 1:20,000 in the pediatric population.¹⁻⁴ The origin of mesenteric cysts is not very clear and the following have been considered: lymphatic duct obstruction, lymphatic duct injury, lymph node degeneration, ectopic lymphatic tissue proliferation, and failure of the mesenteric sheets to fuse together. Congenital

diseases, diverticula, pelvic cavity surgery, and inflammatory pelvic disease have also been described as possible etiologies.⁵

These cysts are generally asymptomatic, slow-growing, and benign. They are more frequent in women than in men and can be detected at any age, but their greatest incidence is in patients between 40 and 70 years of age.⁶

Size varies, with a mean up to 10 cm in diameter. They do not cause specific symptomatology, and when symptoms do appear they are related to the gastrointestinal tract. Acute symptoms resulting from torsion, rupture, or bowel obstruction are extremely rare.^{7,8}

Some uncommon cases have presented with complications, such as infection, hemorrhage, volvulus, perforation, ileus, and acute abdomen.^{9,10}

As with all intra-abdominal tumors, diagnosis is easy to make through ultrasound or tomography, but the precise, preoperative diagnosis of mesenteric cyst is difficult because it is a rare entity with no specific symptoms.

Complete surgical resection is the treatment of choice and can be performed through laparotomy or laparoscopy.⁴⁻⁹ In the majority of cases, the pedicle of the cyst is situated in the mesentery of the small bowel, involv-

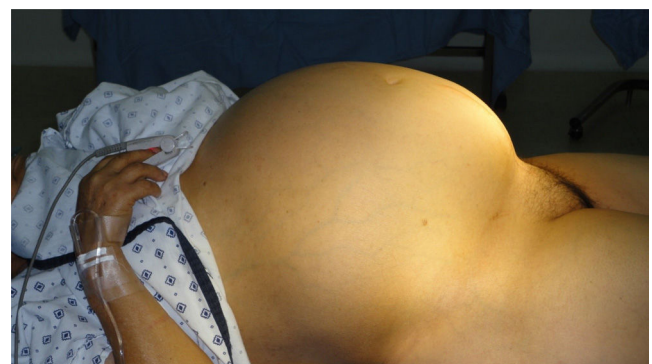

Figure 2 Preoperative aspect of the patient. Lateral view.

ing that organ and often making bowel resection necessary, requiring end-to-end anastomosis after en bloc resection of the cyst. In other cases, the pedicle is located in the mesentery of the descending colon or the rectum.⁸

Our patient was referred to us with an erroneous diagnosis after numerous diuretic treatments, confusing the giant cyst with untreatable tension ascites secondary to a supposed cirrhosis from post-transfusion hepatitis.

The present case is interesting because the cyst was diagnosed in the preoperative period through abdominal tomography, which is extremely rare, and because of its very large size.

Resection through laparoscopy can be attempted in smaller tumors, but given the size of our patient's cyst, laparotomy was preferred. First the cyst was punctured and gradual decompression was carried out, so as not to cause hemodynamic alterations. Eleven liters of a clear, citrine fluid (fig. 3) were drained. Once the cyst was emptied, its vascular pedicle was located in the mesentery of the rectosigmoid colon and was clamped and cut (figs. 4 and 5).

The patient had a very satisfactory postoperative period and was released 48 h later. There has been no recurrence or complication inherent to the pathology or surgery at the follow-up at 48 months.

The histopathology report was a mesothelial mesenteric cyst, corresponding to type 2 of the current classification, which considers 6 variants based on histopathologic characteristics: 1) cysts of lymphatic origin (simple lymphatic cysts and lymphangiomas), 2) cysts of mesothelial origin (simple mesothelial cyst, benign cystic mesothelioma, and malig-



Figure 3 Citrine characteristics of the intracystic fluid. Eleven liters were obtained.

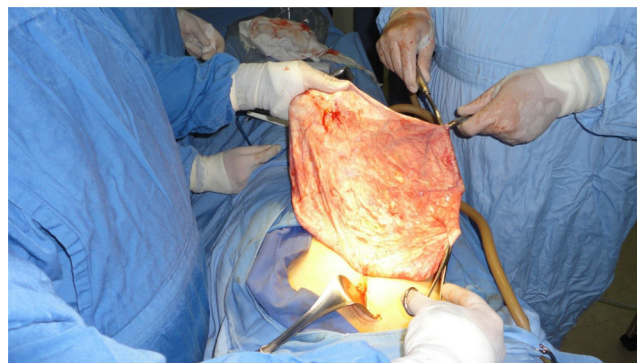

Figure 4 Aspect of the emptied cyst.

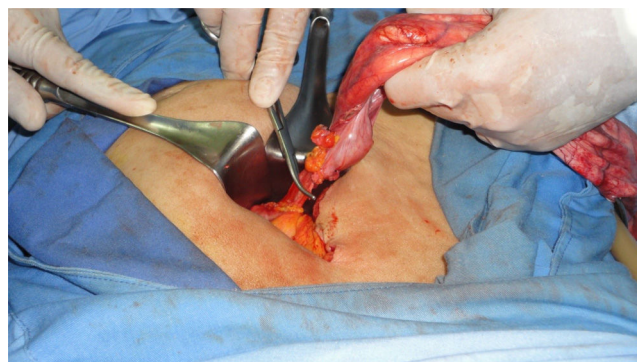


Figure 5 Ligature and cutting of the pedicle of the cyst in the mesentery of the rectosigmoid colon.

nant cystic mesothelioma), 3) cysts of enteric origin (enteric cysts and enteric duplication cysts), 4) cysts of urogenital origin, 5) mature cystic teratoma (dermoid cysts), and 6) pseudocysts (infectious and traumatic cysts).¹ Malignancy presents in only 3% of the cases.⁴

In conclusion, mesenteric cyst is a rare, slow-growing entity, with no clinical pathognomonic signs. Its diagnosis is not considered in the preoperative period and it is generally diagnosed as an imaging study finding. All of these cysts should be resected through laparotomy or laparoscopy.

Financial disclosure

No financial support was received in relation to this article.

Conflict of interest

The authors declare that there is no conflict of interest.

Referencias

1. De Perrot M, Bründler MA, Tötsch M, et al. Mesenteric cysts. Toward less confusion? *Dis Surg.* 2000;17:323–8.
2. Tan JJ, Tan KK, Chew SP. Mesenteric cysts: An institution experience over 14 years and review of literature. *World J Surg.* 2009;33:1961–5.

3. Botianu PVH, Gliga M, Moldovan SC, et al. Anatomic-clinical analysis of 14 consecutive cases of primary cystic mesenterico-epiploic tumors. *Chirurgia*. 2014;109:644-8.
4. Al-Harfoushi R, Stevenson L, Binnie N. Mesenteric cyst: Drained and marsupialised laparoscopically avoiding enterectomy. *BMJ Case Reports*. 2012;2012, pii: bcr0220125916. doi: 10.1136/bcr-02-2012-5916. PubMed PMID: 22948982; PubMed Central PMCID: PMC4543056.
5. Liew SC, Glenn DC, Storey DW. Mesenteric cyst. *Aust N Z J Surg*. 1994;64:741-4.
6. Sánchez FP, Mier y Díaz J, Blanco BR, et al. Quiste mesentérico. Informe de un caso. *Cir Ciruj*. 1999;67:143-5.
7. Sato M, Ishida H, Konno K, Komatsuda T, Konno S, Watanabe S, et al. Mesenteric cyst: Sonographic findings. *Abdom Imaging*. 2000;25:306-10.
8. Barreto SW, Wendell LP, Barreto AJ, et al. Cisto mesentérico —aspectos clínicos e anatómopatológicos [Mesenteric cyst—clinical and pathological aspects]. *Rev Col Bras Cir*. 2010;37:260-4.
9. Kwan E, Lau H, Yuen WK. Laparoscopic resection of a mesenteric cyst. *Gastrointest Endosc*. 2004;59:154-6.

10. Ozdogan M. Acute abdomen caused by a ruptured spontaneously infected mesenteric cyst. *Turk J Gastroenterol*. 2004;15:120-1.

M. Vallejo-Soto^{a,*}, S. Orozco-Simental^b

^a General Surgery Service, Hospital Ángeles y Star Médica de Querétaro, Querétaro, Mexico

^b Clínica de Diagnóstico Servicios Integrados de Imagenología, Querétaro, Querétaro, Mexico

* Corresponding author. Bernardino del Razo 21-110, Col. Ensueño, C.P. 76178, Querétaro, Qro., Mexico. Telephone and fax: +442 192 3028; cell phone: 442 230 1806.

E-mail address: mvallejosoto@gmail.com (M. Vallejo-Soto). 2255-534X/

© 2017 Asociación Mexicana de Gastroenterología. Published by Masson Doyma México S.A. This is an open access article under the CC BY-NC-ND license (<http://creativecommons.org/licenses/by-nc-nd/4.0/>).

Cavitating mesenteric lymph node syndrome: An uncommon complication of celiac disease[☆]



Síndrome del nódulo mesentérico cavitado: complicación infrecuente de la enfermedad celíaca

Celiac disease (CD) is a process with an autoimmune base that affects the small bowel and is triggered by the ingestion of gluten in genetically susceptible individuals. Numerous complications associated with CD have been described, among which cavitating mesenteric lymph node syndrome (CMLNS) stands out for its rarity. Little is known of its etiopathogenesis, and it should be recognized early and differentiated from infections and lymphoma, in particular. We present herein a case of CD with this complication associated with other concomitant diseases with an autoimmune base.

A 52-year-old woman was diagnosed with Sjögren syndrome (SS) and she sought medical attention for altered transaminases and cholestatic enzymes, and positive AMA with positive M2 and elevated IgM. An abdominal ultrasound (US) study and liver biopsy were ordered and treatment with ursodeoxycholic acid at a dose of 14 mg/kg/day was begun due to primary biliary cholangitis (PBC) diagnosis. The patient complained of non-bloody, pasty stools 4-5 times a day over a 6-month period and a consequent weight loss of 8 kg. Physical examination was normal. Weight: 65 kg and height: 167 cm. Body mass index: 23.3. The remarkable laboratory test results were: alanine

aminotransferase: 68 (0-31) U/l; aspartate aminotransferase: 113 (0-55) U/l; alkaline phosphatase: 264 (5-36) U/l; GGT: 341 (35-104) U/l; immunoglobulins: IgM: 624 mg/dl (40-230); AMA: 1/604; AMA-M2: positive; and anti-transglutaminase: 160 U (0-20). The US study identified pathologic mesenteric adenopathies with a cystic appearance. Tumor markers were normal. The microbiology study was negative for human immunodeficiency virus and tuberculosis. A thoracoabdominal computerized tomography (CT) scan showed multiple adenopathies in the mesentery > 1 cm, with a rounded cystic aspect and low attenuation in the central area (fig. 1). Colonoscopy was normal and gastroscopy revealed an atrophied duodenal nodular mucosal pattern that was histologically consistent with Marsh IIIa stage disease (figs. 2 and 3). Liver biopsy was consistent with stage II PBC.

Once infections (tuberculosis and Whipple's disease) and Crohn's disease were ruled out, the main differential diag-

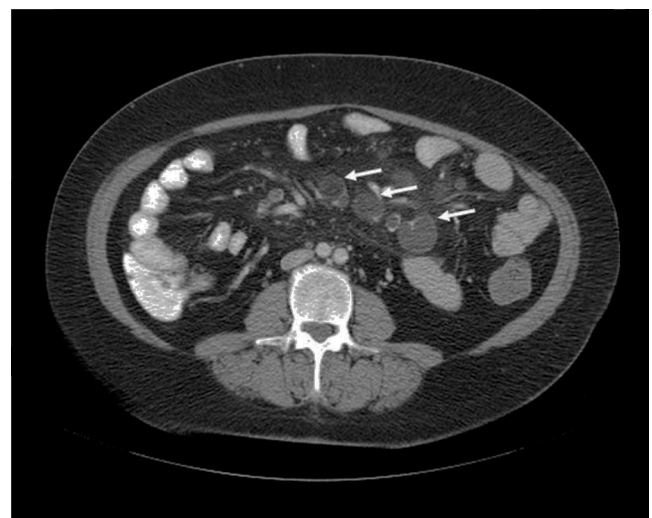


Figure 1 Adenopathies with rounded cystic central zones.

[☆] Please cite this article as: Ruiz-Clavijo García D, García de Galdiano Fernández A, González de la Higuera Carnicer B, Rubio-Marco I, Mercado Gutiérrez M. Síndrome del nódulo mesentérico cavitado: complicación infrecuente de la enfermedad celíaca. *Revista de Gastroenterología de México*. 2017;82:351-353.