




REVISTA DE GASTROENTEROLOGÍA DE MÉXICO

www.elsevier.es/rgmx



SCIENTIFIC LETTERS

A brief history of amoebic liver abscess with an illustrative case[☆]



Breve historia del absceso hepático amebiano, con un caso ilustrativo

Introduction

Amoebiasis is caused by the protozoan, *Entamoeba histolytica* (*E. histolytica*). This parasite has 2 life stages: as a cyst, which is the infectious form, and as a trophozoite, which is the form that causes invasive disease. Approximately 500 million persons are annually infected worldwide,¹ and frequently in poor countries, due to socioeconomic conditions and sanitation levels. The majority of cases are asymptomatic, but the disease can manifest as amoebic dysentery, amoebic liver abscess, and can sometimes affect the lungs, heart,² and brain.³ Amoebiasis is situated between the third and fifth cause of death from parasitic disease at the world level.⁴ *E. histolytica* trophozoites invade the colonic mucosa, causing inflammation. In some cases the amoebas break through the mucosal barrier⁵ and travel through the portal circulation to the liver, where they cause abscesses. Amoebic liver abscess (ALA) is the most frequent extraintestinal manifestation of amoebiasis.⁶ It is estimated that from 2 to 5% of intestinal amoebiasis cases progress to liver abscess. Mexico has the characteristics of an endemic country, with a mean ALA rate of 3.66 per 100,000 inhabitants. An epidemiologic map of the country shows that few States are affected by ALA; in some the incidence rate is lower than the national mean. For example, in the federal entity of Mexico City, it is 0.69 and the rates in the following states are: Sinaloa, 11.37; Nayarit, 10.11; Colima, 9.5; and Chiapas, 11.1. Sonora has the highest rate,⁷ with 13.4. Hernández et al.⁸ and Valenzuela et al.⁹ explain this by showing that there are differences in the presence of alleles in the major histocompatibility complex (*HLA-DRB1* and *HLA-DQB1*) among the inhabitants of different regions of the country, conferring resistance to the development of amoebic liver abscess, as occurs in Mexico City. The population of Sonora does not have those alleles

and so they have a greater susceptibility to the disease. ALA presents more frequently in men^{10,11} between the ages of 30 and 50 years, with a ratio of 10:1. There are important case series reported in Mexico: In the *Centro Médico Nacional Siglo XXI* of the *Instituto Mexicano del Seguro Social*, Cuarón and Gordon¹² conducted a multicenter study between 1963 and 1969 based on tomographic findings, gathering information on a total of 4,286 ALAs in 2,500 patients. Eighty-three percent of the cases had a single ALA and the remaining 17% presented with more than one lesion. Between 1968 and 1972, at the *Instituto Mexicano del Seguro Social*, 3,000 cases of hepatic amoebiasis were reported by Barroso,¹³ with 1,200 patients with ALA. The case series from the *Hospital Juárez* by Pérez-García and Zamora-Godínez¹⁴ in 1994 included studies on platelets and lymphocytes as outcome indicators of ALA. Another important series on ALA (1,128 patients) was conducted by Cerecero and Gaxiola¹⁵ in 1980 at the *Hospital General de México*, the same hospital center where a study was carried out in 1996 on ultrasound-guided evacuating puncture that included 160 patients.¹⁶ The number of cases of ALA since 2002 is unknown. A report of 48 cases, between 2005 and 2007, was conducted in the State of Sonora.⁷ ALA continues to be a health problem linked to poverty. One study found cases from 1.7 to 2.1% in patients hospitalized in general hospitals for very low-income persons, whereas in the registers of hospitalized patients in private hospitals, only 0.8% cases of ALA were found. Liver abscesses are usually treated with drugs, such as metronidazole, with a success rate of 90%.¹⁷ The contributions of Sigler et al.¹⁸ guided many surgeons in Mexico in the successful treatment of ALA. In recent years, percutaneous liver puncture^{19,20} has been considered the criterion standard of surgical treatment, more than 150 years after its implementation by the Mexican physician, Miguel. F. Jiménez, in 1856.

Clinical case

A 57-year-old man from San Luis de la Paz, Guanajuato, with a low socioeconomic level, had a 2-week progression of diarrhea with mucus and blood accompanied by straining and tenesmus, along with 10 days of fever and moderate-to-intense abdominal pain located at the right upper quadrant and irradiating to the right shoulder. Physical examination revealed: temperature of 39° C; heart rate of 100 beats/min; respiratory rate of 20 breaths/min; and blood pressure of 95/60 mmHg. Peristalsis was present, there was pain in the right hypochondrium upon palpation, hepatomegaly of 4 cm below the costal margin, and positive fist percussion

[☆] Please cite this article as: Arellano-Aguilar G, Marín-Santillán E, Castilla-Barajas JA, Briebesca-Juárez MC, Domínguez-Carrillo LG. Breve historia del absceso hepático amebiano, con un caso ilustrativo. *Revista de Gastroenterología de México*. 2017;82:344–348.

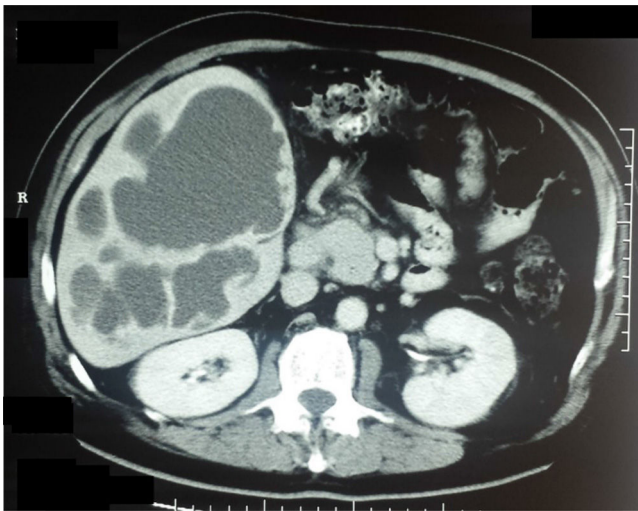


Figure 1 Axial view of a double-contrast computed tomography scan showing: an enlarged liver with multiple cystic lesions of 18 Hounsfield units (thick fluid), corresponding to amoebic liver abscesses.

in the hepatic area with no signs of peritoneal irritation. The patient was hospitalized with the clinical diagnosis of amoebic liver abscess. Abdominal ultrasound showed multiple cystic formations in the liver that were confirmed through contrast-enhanced abdominal tomography scan and scintigram (figs. 1 and 2). Blood cytometry reported leukocytes of $12,000 \times 10^3/\mu\text{l}$, with 78% neutrophilia, and a positive serologic latex agglutination test. Metronidazole was administered at a dose of 750 mg 3 times/day for 10 days. The

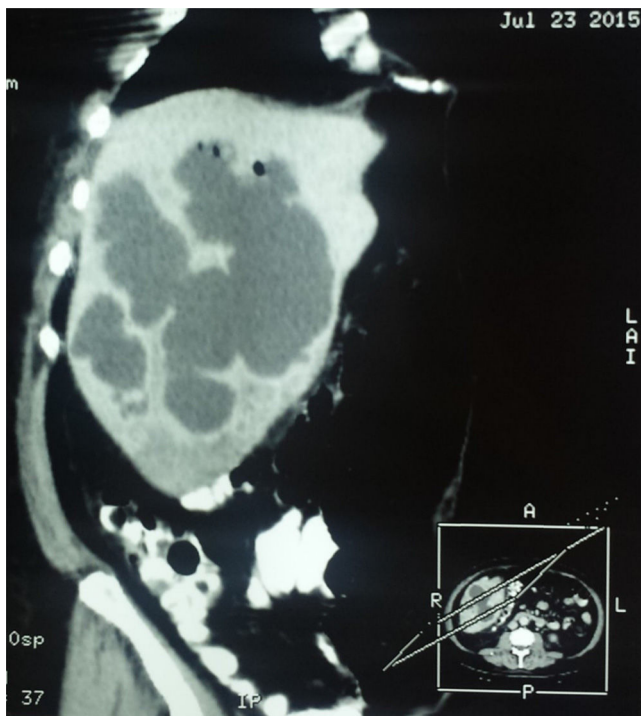


Figure 2 Oblique sagittal view of a double-contrast computed tomography scan showing cystic lesions, corresponding to amoebic liver abscesses.

patient was released on the 12th day of hospitalization with no symptoms.

Some interesting historic facts about amoebic liver abscess and its causal agent

The book *Bibliografía mexicana del absceso hepático* by Dr. Raoul Fournier,²¹ published in 1956, contains an annotation by the physician and historian, Francisco Fernández del Castillo,²² relating the arrival in 1608 of the Archbishop of Mexico and future Viceroy of New Spain, Fray García Guerra, who died 6 months after being promoted to viceroy in 1611 (probably from an amoebic liver abscess). According to the chronicle in the words of Mateo Alemán, "He was suffering from a lack of animus, distress, and a bit of too much heat." To get away from the hectic pace of the capital he sought refuge in Tacubaya, where he was treated by several physicians. Nevertheless, the fever, pain in the liver, and the fact that "that abscess having spontaneously corrupted itself from the inside" made it necessary one Sunday at four in the afternoon -the bull-fighting hour- to open His Grace, who survived only two weeks'. In the autopsy "they found, by the concave part of the tip of the liver, where it touches the ribs, half an egg's worth of putrid matter."

One hundred seventy-eight years later, in 1790, the Royal Tribunal of the Protomedicato (Medical Board)²³ called the physicians to an academic contest on "Inflammatory obstructions of the liver". One of the awarded participants was Don Joaquín Pío Eguía y Muro, "professor of Vespers of Medicine at that Royal University, physician at the San Andrés General Hospital, and Proto-Attorney of the Tribunal of the Protomedicato". Eguía speaks of "an epidemic of malignant bilious fevers" that in 1783 "made it impossible to explain the normal anatomy of the liver to the students of anatomic practice, because all the cadavers provided (seven) presented with this bloody entrail".

The first mention of the existence of amoebas²⁴ corresponds to Rösel von Rosenhof of Nuremberg, who in 1755 described what he called "the little Proteus", alluding to the changing form of the cells. The name later given to amoebas comes from the Greek, ἀμείβω, *amoibé*, which means change.

One hundred years later, one of Mexican medicine's contributions to surgical treatment of the liver abscess was made by the physician, Miguel F. Jiménez. In 1856, he began the puncture and cannulation of the liver abscess as an effective therapeutic procedure, thus reducing the mortality of this disease, whose causal agent would be known almost 20 years later.²⁵

In chapter V of the *Crónicas de la Medicina Mexicana*,²⁶ the following is written: "Dr. Jiménez made the fortunate decision to write down and publish his observations, research, and clinical lessons. His most well-known works are those on liver abscess. He described very complete clinical symptoms, according to the different locations of the abscess. He also described the complications and the method to cure the hepatic lesion through evacuating punctures". The eminent Mexican physician, Miguel F. Jiménez, died on April 2, 1875.

One of the most paradoxical facts in the history of amoebiasis,²⁷ a disease characteristic of countries with

warm climates, is that it was first discovered in St. Petersburg (a city with temperatures below 7° C, three quarters of the year) by Dr. Fedor Aleksandrovich Lesh. In 1875, he attended to a patient from the Arkhangelsk district, close to the Arctic Circle. The patient had diarrhea, general malaise, and rectal discomfort. Upon examining the patient's stools, Lesh found numerous microscopic formations that he believed to be amoebas, due to their form and mobility. In his words, their microscopic appearance indicated that "they cannot be confused with anything, not even for a moment, that are not amoebic cells". Microscopically, he described the presence of refractile nucleoli, or intranuclear bodies (rediscovered one hundred years later). In addition, in an experiment on 4 dogs, he infected them with the contaminated fecal matter from the patient with diarrhea and one became sick. This confirmed that the amoebas were capable of producing intense irritation that progressed to ulceration of the large intestine.

William Osler described the first case of amoebic liver abscess studied in the United States at the end of the nineteenth century. He found abundant amoebas in a 19-year-old physician who was a former resident of Panama, where he had suffered various episodes of dysentery ending in fever, general malaise, and pain in the area of the liver. The patient died April 5, 1890 and the article on his cause of death appeared in the Johns Hopkins Hospital bulletin the following month. After Osler's description, his disciples reported 15 cases of invasive amoebiasis at a hospital in Baltimore.

One year later, William Councilman published the monograph on the pathology of amoebiasis in which the terms "amoebic dysentery" and "amoebic liver abscess" were introduced. In addition to the description of the lesions produced by the parasite, he suggested that the human intestine could contain different species of amoeba, some pathogenic and some not.

The differentiation between *Entamoeba coli* (*E. coli*) and *E. histolytica* was begun in 1893 by two German physicians, Quincke (who introduced the lumbar puncture technique) and Roos, who discovered the cystic form of the amoeba. Fritz Schaudinn (the discoverer of *Treponema pallidum*) finally differentiated *E. coli* from *E. histolytica*. Schaudinn died at 35 years of age (another paradox) from complications of amoebiasis, resulting from self-experimentation with the pathogen. In 1909, Huber demonstrated that amoebas propagate from one host to another in the form of cysts.

In 1913, Walker and Sellards conducted one of the most important experiments of medical parasitology and knowledge of amoebiasis. With the help of Phillipino volunteers that were inmates in the Bilibid prison, they showed that *E. coli* was not capable of producing dysentery. Twenty prisoners were fed *E. coli* organisms, 17 became infected, and none of them became ill. *E. histolytica* was given to 20 other volunteers, 18 became infected, and only 4 of the 18 had dysentery. The experiment showed that the same organism could be a pathogen in some individuals and not cause disease in others. It also led to the conclusion that an asymptomatic carrier could transmit a pathogenic parasite to other individuals. The conditions under which Walker and Sellards carried out the experiments were striking. The following is their description of what is known today as informed consent: "The nature of the experiment, and the possibility of developing dysentery as a result of it,

were carefully explained to each of the men in their native dialect and each one signed his agreement to the conditions of the experiment. No promises of immunity from prison discipline, commuted sentences, or financial reward were granted in exchange for volunteering".

In 1925, the French parasitologist, Émile Brumpt, based on epidemiologic considerations, emphasized that the amoeba of cosmopolitan distribution was a non-pathogenic parasite that he named *Entamoeba dispar* (*E. dispar*), whereas the parasite located in certain tropical countries in which dysentery and liver abscess were frequent, was another amoeba, which he named *Entamoeba dysenteriae*, establishing the basis for the existence of 2 different species of amoeba, one that was a pathogen and the other that was not.

The life cycle of *E. histolytica* was described in 1928 by the English zoologist, Clifford Dobell.²⁷

With respect to the initial treatment of amoebiasis, long before the arrival of the Europeans to the western edges of the Atlantic Ocean, *ipecacuanha* was used by the indigenous tribes to treat dysentery. At the beginning of the nineteenth century, Pelletier isolated emetine from the root of the *ipecacuanha*. However, it was Rogers, in 1912, who demonstrated its usefulness against the symptoms of amoebiasis. In the following years, a synthetic form of emetine was achieved that combined anti-amoebic effectiveness, with fewer adverse effects than those from the infusion prepared with the root of the plant. In 1955, Nakamura isolated azomycin (2-nitromidazole) from *Streptomyces vaginalis*. Thus began the synthesis of drugs derived from nitroimidazoles. At the end of the 1950s, Cosar and Julou²⁸ synthesized metronidazole, and in 1961,²⁹ they reported their experiences in the management of trichomoniasis and amoebiasis. The work of Powell et al.³⁰ in 1966 and Powell³¹ in 1971 confirmed the usefulness of metronidazole, modifying the treatment of amoebiasis and amoebic liver abscess worldwide. The year 1980 brought about the modification of the epidemiology of amoebiasis.

During the second half of the twentieth century, thanks to the insistence and perseverance of the distinguished Mexican physician, Bernardo Sepulveda, the *Centro de Estudios sobre Amibiasis* was founded in 1968, and included a myriad of Mexican medical scientists from the *Universidad Nacional Autónoma de México*, the *Instituto Mexicano del Seguro Social*, and the *Secretaría de Salud*, as well as from international agencies. It is impossible to mention them all, but the work of the following contributors must be highlighted: that of Sepulveda, himself;^{32,33} the experimental research of Pérez-Tamayo;³⁴ the contributions of Escandón³⁵ on the management of asymptomatic carriers; the research of Muñoz, described by Conde and De La Mora,³⁶ on diagnostic methods; the work and experiences contained in the book by Martínez-Palomo;³⁷⁻³⁹ the contributions on epidemiology from Tanimoto⁴⁰ and his indefatigable experiments on animals; and the vast number of historic information masterfully related by Gaxiola.⁴¹ Over the years, the efforts of the *Centro de Estudios sobre Amibiasis* resulted in: a) broad knowledge about the structure and physiology of *E. histolytica*, based on the axenic culture of the amoeba by Diamond and Harlow in 1961 and 1978 (culturing it without the presence of bacteria), enabling many aspects of the amoeba to

be studied; b) knowledge of the mechanism of initial penetration into the tissues, carried out in animal models, as well as agglutination and its mechanism of action, cytotoxicity, phagocytosis, cytolysis, and the discovery of ionic channel forming-proteins, beta-N-glucuronidase, and chemotaxis inhibitors; c) knowledge of human immunology against amoebiasis; and d) the isolation and characterization of *E. histolytica* antigens, along with the equally important recognition by the World Health Organization (WHO) of amoebiasis as a worldwide health problem. Once again, we emphasize that this came about thanks to the unwavering dedication of Dr. Sepúlveda (from 1968 to 1984). To these contributions, we must add those of Stopen in diagnostic imaging, made over a period of 20 years.⁴²⁻⁴⁵ In 1993, Clark and Diamond⁴⁶ realized that amoebas isolated from sickened individuals were different from those in healthy individuals, due to their agglutination capacity with certain lectins that had specific isoenzyme patterns, antigenic differences, and differences in DNA, based on biochemical, immunologic, and genetic evidence. This fact enabled the scientific community to adopt *E. dispar* as a species that was distinct from, but morphologically identical to, *E. histolytica*, which was accepted by the WHO in 1997. In 2003, the prestigious New England Journal of Medicine dedicated a review article to amoebiasis,⁴⁷ signifying that it continues to be a current theme. The technology of the present century has enabled the gene sequencing⁴⁸ of an internationally recognized strain, *E. histolytica* HM1: IMSS (of Mexican origin), thus opening new fields for the study of this parasite. Nevertheless, amoebiasis continues to be a public health problem in many parts of the world, and even more so with the migration of large populations that is presently occurring in Europe. Perhaps the twenty-first century will provide the key to controlling poverty, which among many other concerns, is linked to amoebiasis.

Financial disclosure

No financial support was received in relation to this article.

Conflict of interest

The authors declare that there is no conflict of interest.

Referencias

1. Haque R, Huston CD, Hughes M, et al. Amebiasis. *N Engl J Med*. 2003;348:1565.
2. Miyauchi T, Takiya H, Sawamura T, et al. Cardiac tamponade due to intrapericardial rupture of an amebic liver abscess. *Jpn J Thorac Cardiovasc Surg*. 2005;53:206-9.
3. Maldonado-Barrera CA, Campos-Esparza MR, Muñoz-Fernández L, et al. Clinical case of cerebral amoebiasis caused by *E. histolytica*. *Parasitol Res*. 2012;110:1291-5.
4. Stanley SL Jr. Amoebiasis. *Lancet*. 2003;361:1025.
5. Ralston KS, Petri WA Jr. Tissue destruction and invasion by *Entamoeba histolytica*. *Trends Parasitol*. 2011;27:254-63.
6. Blazquez S, Rigotherier MC, Huerre M, et al. Initiation of inflammation and cell death during liver abscess formation by *Entamoeba histolytica* depends on activity of the galactose/N-acetyl-D-galactosamine lectin. *Int J Parasitol*. 2007;37:425-33.
7. Puebla CJ, Clark, Alday NM, et al. Particularidades del absceso hepático amebiano en México: revisión de una cohorte de pacientes del Hospital General del Estado de Sonora. *Med Int Mex*. 2012;28:440-5.
8. Hernández EG, Granados J, Partida-Rodríguez O, et al. Prevalent HLA class II alleles in Mexico City appear to confer resistance to the development of amebic liver abscess. *PLOS ONE*. DOI:10.1371/journal.pone.0126195 May 4, 2015.
9. Valenzuela O, Morán P, Gómez A, et al. Epidemiology of amoebic liver abscess in Mexico: The case of Sonora. *Ann Trop Med Parasitol*. 2007;101:533-8.
10. Snow M, Chen M, Guo J, et al. Short report: Differences in complement-mediated killing of *Entamoeba histolytica* between men and women—An explanation for the increased susceptibility of men to invasive amoebiasis? *Am J Trop Med Hyg*. 2008;78:922-3.
11. Lotter H, Helk E, Bernin H, et al. Testosterone increases susceptibility to amebic liver abscess in mice and mediates inhibition of IFN γ secretion in natural killer T cells. *PLoS ONE* 8:e55694. doi: 10.1371/journal.pone.0055694.
12. Cuarón A, Gordon F. Liver scanning analysis of 2,500 cases of amebic hepatic abscesses in Hospital General, Centro Médico Nacional, Mexico City, Mexico. *J Nucl Med*. 1970;11:435-9.
13. Barroso E. Aspectos sobresalientes de la amebiasis hepática. *Gac Med Mex*. 1965;95:251-254.
14. Pérez-García R, Zamora-Godínez J. El absceso hepático amebiano en el nuevo Hospital Juárez de México. *Cir Cir*. 1994;62:138-40.
15. Cerecero CV, Gaxiola R. Absceso hepático amebiano: estudio de 1128 pacientes. *Rev Med Hosp Gral Mex SS*. 1980;43:26-8.
16. Perdigon CG, Fabian SMM, Ponce VN, et al. Efectividad de la punción evacuadora dirigida por ultrasonido en pacientes refractarios a tratamiento médico en el absceso hepático amebiano. *Rev Med Hosp Gral Mex*. 1996;59:4-7.
17. Diagnóstico, tratamiento del absceso hepático amebiano no complicado. Guía de Práctica clínica. México: Secretaría de Salud; 2014.
18. Sigler ML, Miery Díaz J, Melgoza OC, et al. Amibiasis, tratamiento quirúrgico en 1989. *Rev Gastroenterol Méx*. 1989;54:185-9.
19. Khan R, Hamid S, Abid S, et al. Predictive factors for early aspiration in liver abscess. *World J Gastroenterol*. 2008;14:2089-93-97.
20. Bammigatti C, Ramasubramanian N, Kadiravan T, et al. Percutaneous needle aspiration in uncomplicated amebic liver abscess: A randomized trial. *Trop Doct*. 2013;43:19-22.
21. Fournier R. Bibliografía mexicana del absceso hepático. México: La Prensa Médica Mexicana; 1956.
22. Fernández del Castillo F. Historia de la Academia Nacional de Medicina de México. Libro conmemorativo del nonagésimo aniversario de la fundación de la Sección Médica de la Comisión Científica de México. 30 de abril de 1864. México: Fournier; 1956. p. 210.
23. Brand HT, Pérez-Tamayo R. Amibiasis. México: La Prensa Médica Mexicana; 1970.
24. Martínez-Palomo A. La amebiasis, enemigo invisible. 6th ed. México: Fondo de Cultura Económica; 1996.
25. Beltrán E. Notas de historia protozoológica. IV. Las amebas parásitas. *Anales de la Sociedad Mexicana de Historia de la Ciencia y de la Tecnología (México)*. 1974;4:259-308.
26. Martínez GM. Cuatro médicos personales del Emperador Maximiliano de Habsburgo. 1864-1867. *Bol Mex His Fil Med*. 2003;6:17-22.
27. Dobell C. The amoebae living in man. A zoological monograph. Londres: John Bale, Sons & Danielsson; 1919.
28. Cosar C, Julou L. Activité de 1'(hydroxy-2-ethyl)-1-methyl-2-nitro- 5-imidazole (8.823R.P.) vis-a-vis des infections expéri-

- mentales à *Trichomonas vaginalis*. *Ann Inst Pasteur (Paris)*. 1959;96:238–41.
29. Cosar C, Ganter P, Julou L. Etude expérimentale du metronidazole (8823 RP). Activités trichomonacide et amoebicide. Toxicité et propriétés pharmacologiques générales. *Prese Med-icale*. 1961;69:1069–72.
 30. Powell SJ, MacLeod I, Wilmot AJ, et al. Metronidazole in amoebic dysentery and amoebic liver abscess. *Lancet*. 1966;2:1329–31.
 31. Powel SJ. Therapy of amebiasis. *Bull NY Acad Med*. 1971;47:469–77.
 32. Sepúlveda B. Hemagglutination and precipitation reactions with axenic amebic antigen in invasive amebiasis. *Arch Invest Med (Mex)*. 1970;1 Suppl:111–6.
 33. Sepúlveda B. Progress in amebiasis. *Scand J Gastroenterol*. 1982;77:153–64.
 34. Pérez-Tamayo R. Amibiasis hepática. *Rev Gastroenterol Mex*. 2006;71 Supl 2:47–72.
 35. Escandón-Romero C, Treviño N, Escobedo J, et al. La amibiasis y el absceso hepático amebiano en México, un problema de salud pública de actualidad. *Rev Gastroenterol Mex*. 1996;61:378–86.
 36. Conde BC, De la Mora ZC. *Entamoeba histolytica*: un desafío vigente. *Salud Pública Méx*. 1992; 34:335–41.
 37. Martínez-Palomo A, Espinosa-Cantellano M. Amebiasis and other protozoan infections. In: Cohen J, Powerly WG, editors. *Infectious diseases*. 2.^a ed. Londres: Elsevier; 2004. p. 1567-1571.
 38. Martínez-Palomo A. *The biology of Entamoeba histolytica*. Chichester: Research Studies Press/John Wiley; 1982.
 39. Martínez-Palomo A, ed. *Amebiasis*. México: Médica Panamericana; 1989.
 40. Tanimoto M, Sigler L, Treviño N, et al. Amibiasis. ¿Ha variado su expresión clínica? *Rev Gastroenterol Mex*. 2006;71:Supl. 2:163-166.
 41. Gaxiola R. History of amoebic liver abscess in Mexico. *Prensa Med Mex*. 1969;34:427–37.
 42. Stoopen M, Casal R, Elizondo L, et al. Las alteraciones angiográficas del absceso hepático amebiano estudio de 60 casos. *Rev Mex Radol*. 1969;23:9–22.
 43. Stoopen M, Elizondo L, Landa L. Estado actual del diagnóstico radiológico en la amebiasis. *Arch Invest Med Mex*. 1972;3:387–402.
 44. Stoopen M, Hori S, Diaz Lopez A, et al. Evaluation de la utilidad de la tomografía computada en el diagnóstico del absceso hepático (informe preliminar). *Rev Gastroenterol Mex*. 1979;44:239.
 45. Stoopen M, Kimura K. La tecnología de los ochentas. Ultrasonido, tomografía computada y resonancia magnética: ¿han contribuido a mejorar el diagnóstico del absceso hepático? *Rev Gastroenterol Mex*. 1989;54:167–75.
 46. Clark CG, Diamond LS. The Laredo strain and other *Entamoeba histolytica*-like amoebae are *Entamoeba moshkovskii*. *Mol Biochem Parasitol*. 1991;46:11–8.
 47. Haque R, Huston CD, Hughes M, et al. Amebiasis. *N Engl J Med*. 2003;348:1565–73.
 48. Loftus B, Anderson I, Davies R, et al. The genome of the protist parasite *Entamoeba histolytica*. *Nature*. 2005;433:865–8.
- G. Arellano-Aguilar^{a,*}, E. Marín-Santillán^b, J.A. Castilla-Barajas^b, M.C. Bribiesca-Juárez^b, L.G. Domínguez-Carrillo^c
- ^a Internal Medicine Division, Hospital Ángeles León, León, Guanajuato, Mexico
^b Surgery Division, Hospital Ángeles León, León, Guanajuato, Mexico
^c School of Medicine, Universidad de Guanajuato, León, Guanajuato, Mexico
- * Corresponding author. Hospital Ángeles León, Av. Cerro Gordo 311, León, Guanajuato, Mexico.
 Tel.: (+52) 477-788-5600.
 E-mail address: gregareag@gmail.com (G. Arellano-Aguilar). 2255-534X/
- © 2017 Asociación Mexicana de Gastroenterología. Published by Masson Doyma México S.A. This is an open access article under the CC BY-NC-ND license (<http://creativecommons.org/licenses/by-nc-nd/4.0/>).

A giant mesenteric cyst mimicking untreatable ascites[☆]



Quiste mesentérico gigante simulador de ascitis intratable

Mesenteric cysts are very rare intra-abdominal tumors with a minimum of clinical symptoms, making their preoperative diagnosis difficult. Diagnosis is generally made through abdominal ultrasound or computed tomography studies. The differential diagnosis should be made with other abdominal or retroperitoneal tumors. Treatment is surgical, with complete resection of the cyst through laparotomy or laparoscopy.

Given that this type of lesion is not often contemplated preoperatively and that its symptomatology can be very ambiguous, we present herein the case of a giant mesenteric cyst whose diagnosis was suspected in the preoperative period, but had previously been confused with another pathology.

A 65-year-old housewife with an obstetric history of gravida 1, para 0, abortus 1, cesarean section 0, had a ruptured ectopic pregnancy at 30 years of age for which she underwent an exploratory laparotomy with profuse intraoperative blood loss and several transfusions in the postoperative period. Her current illness had a 2-year progression and began with gradual, nonpainful abdominal growth that eventually became incapacitating. It caused dyspnea in the dorsal decubitus position, the patient was unable to get up on her own, and it limited her walking due to respiratory difficulty.

She was examined and managed by a general practitioner, who after numerous failed treatments with diuretics for apparent progressive ascites, referred her for control and management of cirrhosis due to post-transfusional hepatitis.

[☆] Please cite this article as: Vallejo-Soto M, Orozco-Simental S. Quiste mesentérico gigante simulador de ascitis intratable. *Revista de Gastroenterología de México*. 2017;82:348–351.