



REVISTA DE GASTROENTEROLOGÍA DE MÉXICO

www.elsevier.es/rgmx



CLINICAL IMAGE IN GASTROENTEROLOGY

A rare cause of dyspepsia[☆]

Una rara causa de dispepsia



A. Guzmán-Lepe^{a,*}, J.A. Velarde Ruiz-Velasco^a, E. Navarro-del Río^b

^a Department of Gastroenterology, Hospital Civil Fray Antonio Alcalde, Guadalajara, Jalisco, Mexico

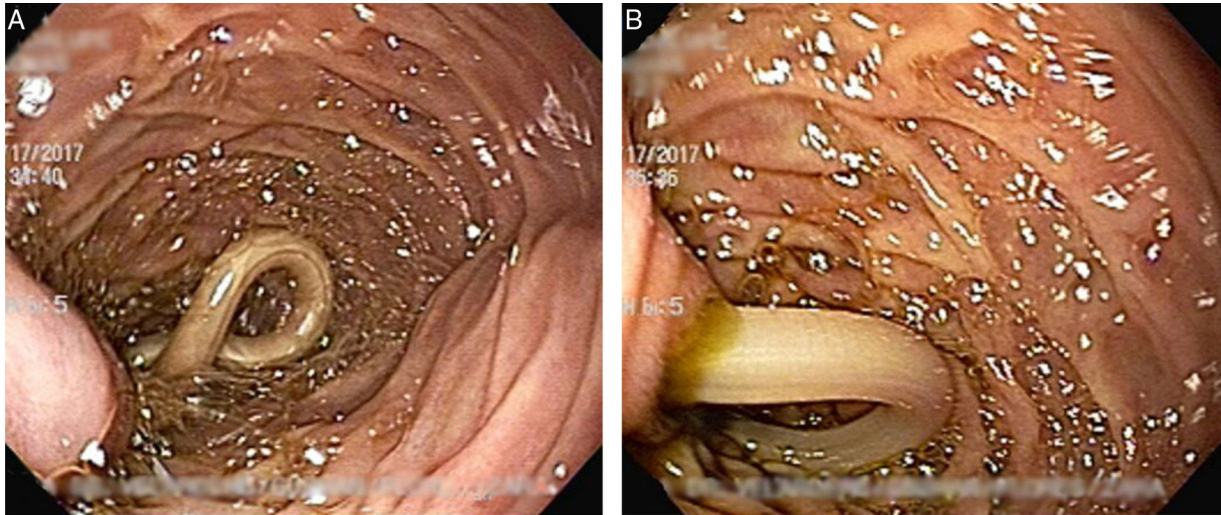
^b Department of General Surgery, Hospital Civil Fray Antonio Alcalde, Guadalajara, Jalisco, Mexico

A 27-year-old woman from a rural zone in Jalisco, Mexico, was admitted to the hospital for nausea, vomiting, and abdominal pain. One month earlier, she presented with burning abdominal pain in the epigastrium and right upper quadrant, along with abdominal bloating. Laboratory test results showed altered liver enzymes with a mixed pattern (AST 64IU/L, ALT 146 IU/L, GGT 185 IU/L, and ALP 188 IU/L), normal bilirubin level, and eosinophilia of 2.06 (14.2%) in the hemogram. The ultrasound study revealed normal-caliber extrahepatic and intrahepatic bile ducts, normal thickness of the gallbladder wall, no stones inside

the gallbladder, and a homogeneous liver parenchyma. The patient underwent esophagogastroduodenoscopy as the approach to uninvestigated dyspepsia, which showed a type of nematode occluding the ampulla of Vater (figs. A and B). It was extracted in its entirety with a biopsy forceps and measured 27 cm in length (fig. 2). The ampulla had a posterior “pregnant” aspect (fig. 3). The patient had no signs of cholangitis or pancreatitis, the abdominal symptoms resolved, and she was released from the hospital under medical treatment. Biliary obstruction is a rare and important complication of *Ascaris lumbricoides* infestation.

[☆] Please cite this article as: Guzmán-Lepe A, Velarde Ruiz-Velasco JA, Navarro-del Río E. Una rara causa de dispepsia. Revista de Gastroenterología de México. 2018;83:66–68.

* Corresponding author. Avenida República #1755, Colonia Blanco y Cuellar, C.P. 44730, Guadalajara, Jalisco, Mexico. Telephones: 044-3312229736, (01 33)-36137317, Ext.: 44413. Fax: +01 33 39424400. E-mail address: lepe_88@hotmail.com (A. Guzmán-Lepe).



Figures 1A and 1B A and B) Nematode occluding the ampulla of Vater.

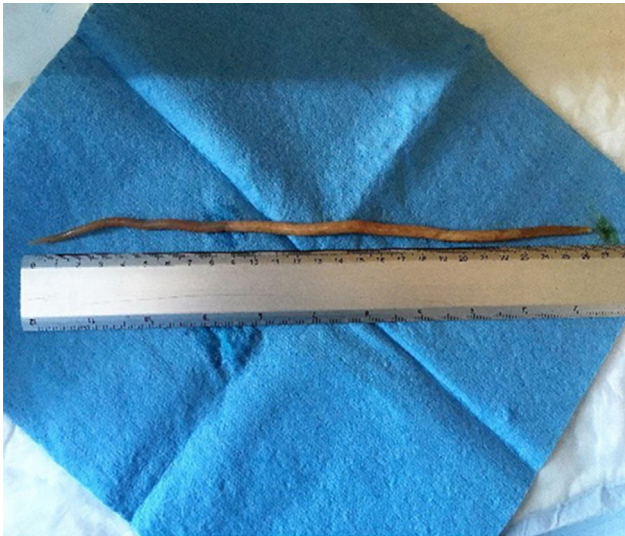

Figure 2 Ascaris lumbricoides measuring 27 cm in length.

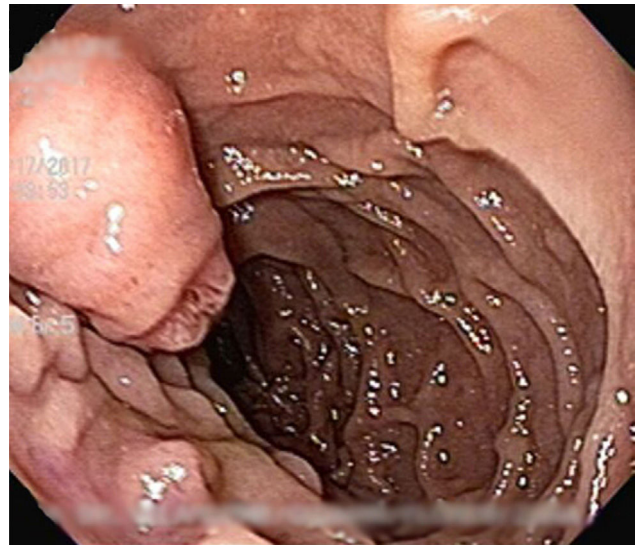


Figure 3 Ampulla with posterior 'pregnant' aspect.

Ethical responsibilities

Protection of persons and animals. The authors declare that no experiments were performed on humans or animals for this study.

Data confidentiality. The authors declare that no patient data appear in this article.

Right to privacy and informed consent. The authors declare that no patient data appear in this article.

Conflict of interest

The authors declare that there is no conflict of interest.