



# REVISTA DE GASTROENTEROLOGÍA DE MÉXICO

[www.elsevier.es/rgmx](http://www.elsevier.es/rgmx)



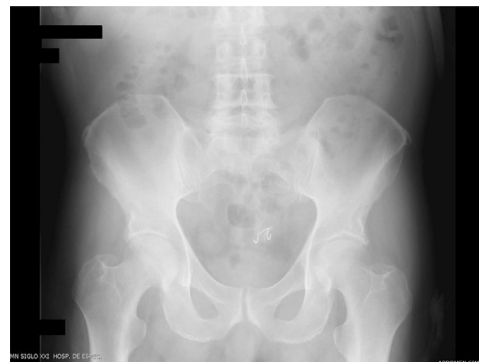## SCIENTIFIC LETTERS

### Successful endoscopic extraction of dental prosthesis impacted in a sigmoid diverticulum<sup>☆</sup>



### Extracción endoscópica exitosa de prótesis dental impactada en divertículo de sigmoides

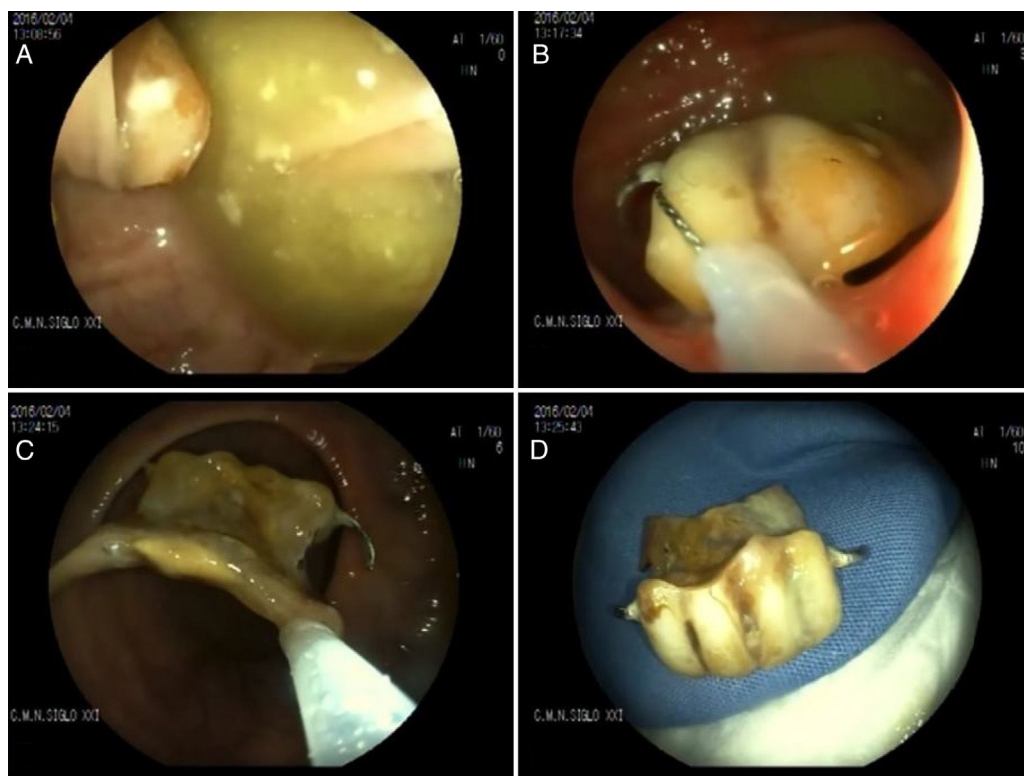
A 75-year-old man had a past surgical history of sigmoidectomy with primary anastomosis due to complicated diverticulitis in 2007. The patient accidentally swallowed a 4-tooth dental prosthesis. Gastroscopy performed 12 h after the accident did not reveal the foreign body. During the ensuing 10-month follow-up, x-rays were taken until repeated images of the foreign body lodged in the sigmoid colon, with no progression, were observed (fig. 1). Through colonoscopy, the impacted prosthesis was identified inside a sigmoid diverticulum, proximal to the anastomosis. It was gently extracted from the diverticulum by means of a 27-mm loop polypectomy snare. Once the prosthesis was out of the diverticulum, its large size prevented it from being placed inside the overtube. Thus, it was held in place by the loop and with delicate maneuvers was extracted through the anastomosis to the rectum, without damaging the mucosa. Once in the rectum, the endoscopist eased the prosthesis out with his fingers (fig. 2). This is the first report of a case of a dental prosthesis lodged in a diverticulum of the colon.



**Figure 1** Unenhanced abdominal x-ray showing the dental prosthesis in the sigmoid colon.

Foreign body ingestion occurs more frequently in children than in adults. Accidental ingestion in adults is more common in the elderly.<sup>1</sup> Most ingested foreign bodies pass through the digestive tract with no complications, but 10 to 20% of cases require endoscopic removal and 1% require surgical treatment.<sup>2</sup> Once they pass the pylorus, 20% of long, sharp foreign bodies can cause perforations, generally at the level of the ileocecal valve.<sup>3</sup> Perforations caused by foreign body impaction in the lower digestive tract are managed through urgent surgery. Foreign bodies that do not cause perforations can be extracted endoscopically with adequate morbidity and mortality rates.<sup>4</sup>

<sup>☆</sup> Please cite this article as: Blanco-Velasco G, Hernández-Mondragón OV, Altamirano-Castañeda ML, Blancas-Valencia JM. Extracción endoscópica exitosa de prótesis dental impactada en divertículo de sigmoides. *Revista de Gastroenterología de México*. 2019;84:106–107.



**Figure 2** A) Dental prosthesis impacted in the diverticulum. B) Loop extraction of the prosthesis. C) Passage of the prosthesis through the anastomosis. D) Extracted dental prosthesis.

### Financial disclosure

No financial support was received in relation to this article.

### Conflict of interest

The authors declare that there is no conflict of interest.

### References

1. Birk M, Bauerfeind P, Deprez PH, et al. Removal of foreign bodies in the upper gastrointestinal tract in adults: European Society of Gastrointestinal Endoscopy (ESGE) Clinical Guideline. *Endoscopy*. 2016;48:489–96.
2. Müller KE, Arató A, Lakatos PL, et al. Foreign body impaction in the sigmoid colon: A twenty euro bet. *World J Gastroenterol*. 2013;19:3892–4.
3. Glasbrenner B, Schweitzer A, Ludolph T. A rare cause of sigmoid obstruction in a 77-year-old patient. *Endoscopy*. 2003;35:886.
4. Wang YP, Shi B. Toothpick impaction with localized sigmoid perforation: Successful double-balloon enteroscopic management. *Endoscopy*. 2012;44 Suppl 2 UCTN:E29.

G. Blanco-Velasco\*, O.V. Hernández-Mondragón,  
M.L. Altamirano-Castañeda, J.M. Blancas-Valencia

*Servicio de Endoscopia, Hospital de Especialidades, Centro Médico Nacional Siglo XXI, Instituto Mexicano del Seguro Social, Mexico City, Mexico*

\* Corresponding author. Avenida Cuauhtémoc 330, Colonia Doctores, Delegación Cuauhtémoc, C.P. 06720, Mexico City, Mexico. Tel.: +5523077204 and 56276900, Ext.: 21317 and 21318.

*E-mail address:* [gerardoblancov@hotmail.com](mailto:gerardoblancov@hotmail.com)  
(G. Blanco-Velasco).

2255-534X/

© 2018 Published by Masson Doyma México S.A. on behalf of Asociación Mexicana de Gastroenterología. This is an open access article under the CC BY-NC-ND license (<http://creativecommons.org/licenses/by-nc-nd/4.0/>).