

## SCIENTIFIC LETTERS

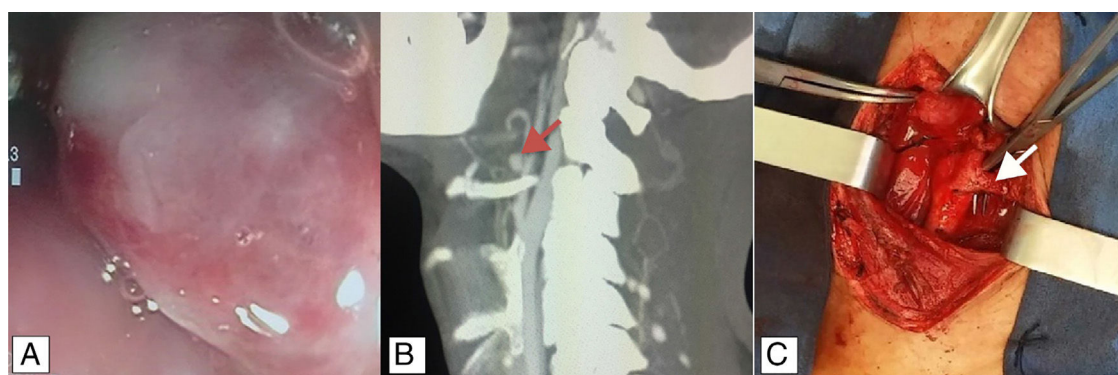
### **Congenital lingual artery aneurysm as an unusual cause of upper gastrointestinal bleeding**<sup>☆</sup>



### **Aneurisma congénito de la arteria lingual como causa inusual de sangrado de tubo digestivo alto**

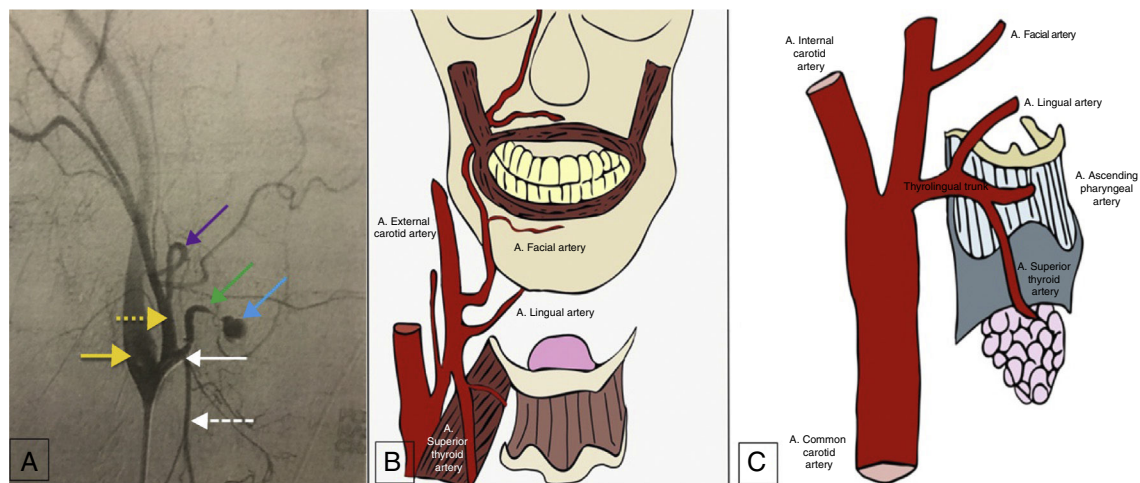
Upper gastrointestinal bleeding is a common problem that presents in the outpatient setting, as well as in the emergency service. The most common causes of this clinical entity are peptic ulcer disease, Mallory-Weiss tear, gastrointestinal neoplasias,<sup>1</sup> and variceal bleeding in the case of patients with portal hypertension. Aneurysms of the lingual artery are infrequent. Aneurysms of the external carotid artery are estimated to account for 2.2% of all cervical carotid aneurysms. Among those, superficial temporal artery and facial artery aneurysms are the most common, whereas lingual artery aneurysms are rare. They only appear in the literature in case reports and their incidence cannot be determined.<sup>2</sup> The majority of cases are pseudoaneurysms, associated with trauma, neoplasias, surgical procedures,<sup>3</sup> or radiofrequency ablation.<sup>4</sup> There are few cases of true idiopathic congenital aneurysms.

A 39-year-old man had a past medical history of appendectomy due to complicated appendicitis, as well as numerous symptoms of lower gastrointestinal bleeding from probable hemorrhoidal disease that were untreated. He was admitted to the hospital for 2-day progression of symptoms characterized by melena and hematemesis. Endoscopy was performed that identified: pulsatile, erythematous, and congestive polypoid tumoral lesion, 3 x 4 cm in diameter, in the right posterolateral wall of the hypopharynx. There were no signs of active bleeding (fig. 1A), but fibrin-covered ulcers extended from the soft palate and proximal portion of the right piriform sinus. Twenty-four hours later, the patient presented with a new episode of bleeding. Angiotomography revealed a thickened hypopharynx and an irregular, right hypodense image, 21 x 17 x 17 mm in diameter, at the level of the inferior constrictor muscle that protruded toward the lumen, obstructing 50% of it, with contrast medium leakage. A sacular image dependent on the aberrant artery was also observed that emerged from the trunk of the superior thyroid artery as a probable variant of the lingual artery (fig. 1B). After angiotomography, the patient presented with sudden onset of massive bleeding through the oral cavity. He became hemodynamically unstable, with AP of 48/30 mmHg and MAP of 33 mmHg. Carotid arteriography was performed (fig. 2A) that identified a 1.5-mm vessel at the level of the



**Figure 1** A) Endoscopy: pulsatile lesion in the hypopharynx. B) Cervical angiotomography: a probable anatomic variation of the lingual artery is observed (red arrow). C) Intraoperative image of the thyrolingual trunk (white arrow).

<sup>☆</sup> Please cite this article as: Ramírez-Ramírez MM, Clemente-Gutiérrez UE, Silva-González M, Zúñiga-Zamora HM, Sánchez-Conejo AR. Aneurisma congénito de la arteria lingual como causa inusual de sangrado de tubo digestivo alto. Revista de Gastroenterología de México. 2019;84:248–250.



**Figure 2** A) Arteriography. Yellow arrow: internal carotid artery; dotted yellow arrow: external carotid artery; purple arrow: facial artery; green arrow: lingual artery; blue arrow: aneurysm of the lingual artery; white arrow: thyrolingual trunk; dotted white arrow: superior thyroid artery. B) Most frequent anatomy of the branches of the external carotid artery. C) Thyrolingual trunk, seen in 0.99% of cases.

bifurcation that drains into the trachea above and to the right of the vallecula. Two sacs measuring approximately 5 and 8 mm were observed along its tract. Failed embolization resulted in carrying out vascular examination of the neck with selective ligation of the first branch of the right external carotid artery (thyrolingual trunk) (fig. 1C). Bleeding control was adequate, and the patient was sent to the intensive care unit, where he underwent blood transfusion. His postoperative period was uneventful.

The clinical presentation of pseudoaneurysms generally involves upper gastrointestinal bleeding, whereas congenital aneurysms are asymptomatic, and so their diagnosis is usually made as an incidental radiologic finding from contrast-enhanced tomography of the cervical region.<sup>2</sup> Upper gastrointestinal bleeding secondary to a pseudoaneurysm of the lingual artery is a potentially fatal event. The customary treatment reported in the literature is embolization through interventional radiology. The case presented herein was unusual in that it was a congenital aneurysm with a history of intermittent gastrointestinal bleeding. Finally, the patient presented with hemorrhagic shock, embolization was unsuccessful, and he then underwent surgical treatment with thyrolingual trunk ligation.

The right common carotid artery arises from the brachiocephalic trunk and the left common carotid artery from the aortic arch. After the posterolateral ascent within the carotid sheath, it divides at the level of the superior edge of the thyroid cartilage into the internal carotid artery and external carotid artery, which have a posterolateral and an anteromedial tract, respectively. They usually do not give off any branches in the neck. The eight habitual branches of the external carotid artery are: the superior thyroid artery, lingual artery, occipital artery, posterior auricular artery, maxillary artery, and superficial temporal artery.<sup>5</sup> The lingual branch originates in the external carotid artery in 84.16% of cases. The majority (24.75%) arise between the superior thyroid artery and facial artery (fig. 2B) at the level of the hyoid bone and 14.85% form a common trunk with the facial artery. The lingual artery originates together

with the superior thyroid artery in only 0.99% of cases (fig. 2C).<sup>6</sup>

## Ethical disclosures

**Protection of human and animal subjects.** The authors declare that no experiments were performed on humans or animals for this study.

**Confidentiality of data.** The authors declare that no patient data appear in this article.

**Right to privacy and informed consent.** The authors declare that no patient data appear in this article.

## Financial disclosure

No financial support was received in relation to this study/article.

## Conflict of interest

The authors declare that there is no conflict of interest.

## References

1. Feinman M, Haut ER. Upper gastrointestinal bleeding. *Surg Clin North Am.* 2014;94:43–53.
2. Brindle RS, Fernandez PM, Sattenberg RJ, et al. Idiopathic lingual artery aneurysm: CT findings and endovascular therapy — A case report. *Interv Neuroradiol.* 2010;16:103–6.
3. Walshe P, Ramos E, Low C, et al. An unusual complication of tonsillectomy. *Surgeon.* 2005;3:296–8.
4. Herzog M, Schmidt A, Metz T, et al. Pseudoaneurysm of the lingual artery after temperature-controlled radiofrequency tongue base reduction: A severe complication. *Laryngoscope.* 2006;116:665–7.
5. Gray SW, Skandalakis JE, Skandalakis PN, et al. *Atlas of Surgical Anatomy for General Surgeons.* Athens: PMP; 2009. p. 15–421.

6. Antonetti C, Díaz F, Castro AM. Variety in collateral branching coming off the external carotid artery. *Revista de la Sociedad Venezolana de Ciencias Morfológicas*. 2010;16:5–10.

M.M. Ramírez-Ramírez<sup>a,\*</sup>, U.E. Clemente-Gutiérrez<sup>b</sup>,  
M. Silva-González<sup>a,b</sup>, H.M. Zúñiga-Zamora<sup>a</sup>,  
A.R. Sánchez-Conejo<sup>a</sup>

<sup>a</sup> General Surgery, SSA, Hospital Regional de Alta Especialidad de Ixtapaluca, Ixtapaluca, State of Mexico, Mexico

<sup>b</sup> General Surgery, Instituto Nacional de Ciencias Médicas y Nutrición Salvador Zubirán, Mexico City, Mexico

\* Corresponding author. Consultorio 404, Avenida Árbol de fuego 80, Coyoacán, El Rosario, 04380, Mexico City. Tel.: +55-29-00-13-48, Tel.: +36-83-75-00 Ext. 5404  
E-mail address: [moy1510@hotmail.com](mailto:moy1510@hotmail.com)  
(M.M. Ramírez-Ramírez).

2255-534X/

© 2018 Published by Masson Doyma México S.A. on behalf of Asociación Mexicana de Gastroenterología. This is an open access article under the CC BY-NC-ND license (<http://creativecommons.org/licenses/by-nc-nd/4.0/>).

## Gastrointestinal stromal tumor as a cause of cancer-associated thrombosis<sup>☆</sup>



### Tumor del estroma gastrointestinal como causa de trombosis asociada a cáncer

A 59-year-old man that worked as a firefighter had a remarkable past medical history of prostatic syndrome and gastroesophageal reflux, with no previous history of venous thromboembolism (VTE). The patient had stopped smoking one year before, with a smoking index of 10 packs/year. He led an active life, with no other cardiovascular risk factors. The patient had no recent history of immobilization or prolonged travel. He did not have varicose veins in his lower limbs and his BMI was 24.8 kg/m<sup>2</sup>.

Six months prior to the present episode, the patient was evaluated at a gastroenterology outpatient clinic in another healthcare center for gastroesophageal reflux symptom worsening. Upper endoscopy was performed, showing a submucosal lesion in the gastric fundus. Endoscopic ultrasound revealed a hypoechoic, 18 x 12 mm tumor with regular borders. The lesion was biopsied and the anatomicopathologic study of the sample revealed spindle cells arranged in fasciculi and interlacing bundles. The tumor stained positive for c-KIT (CD117) and CD34, and negative for alpha smooth muscle actin, desmin, and S-100, confirming the diagnosis of gastrointestinal stromal tumor (GIST). The Ki-67 proliferative index was less than 1%. The treating gastroenterologists decided on conservative tumor management with annual endoscopic follow-up.

The patient arrived at the emergency room of our hospital due to sudden onset of dyspnea and chest pain. Upon physical examination, his blood pressure was 144/76, heart rate was 78 beats per minute, oxygen saturation when breathing ambient air was 97%, and respiratory rate was 15 breaths per minute. His lower extremities were normal, with no signs of deep vein thrombosis (DVT) and

no varicose veins. The rest of the examination was normal. Blood analysis results were: hemoglobin 15.9 mg/dl, 304,000 platelets/mm<sup>3</sup>, creatinine 0.78 mg/dl, and D-dimer 1344 ng/ml. Arterial blood gases were: pO<sub>2</sub> 74 mmHg, pCO<sub>2</sub> 35 mmHg, and oxygen saturation 95%. A chest computed tomography (CT) scan revealed bilateral filling defects in multiple sub-segmental arteries (fig. 1). Weight-adjusted enoxaparin was then begun, and the patient was admitted to the Venous Thromboembolism Unit.

An echocardiogram showed a mildly dilated right ventricle with normal ventricular function. Estimated pulmonary artery systolic pressure (PASP) was 43 mmHg. An abdominal CT scan was also performed to evaluate the extension of the gastric tumor, showing a solid 18 mm lesion in the gastric fundus, with no adenopathies or metastasis. A Doppler ultrasound of the lower extremities showed no echographic findings of DVT.

The patient's clinical situation improved, and he was discharged after 5 days. Since the tumor was possibly related to the development of VTE, the case was re-evaluated together with the General Surgery and Oncology services, and the decision was made to defer surgery until completing 3 months of anticoagulant treatment. The patient was treated with enoxaparin for 3 months, and then scheduled for partial gastrectomy. Thrombophilia testing that included antithrombin, homocysteine, protein C, protein S, antiphospholipid antibodies, factor V Leiden, and prothrombin mutation, was negative. The procedure was performed with good outcome and the sample was sent to our Pathology Department (fig. 2). Seven days after surgery, treatment with enoxaparin was discontinued and rivaroxaban 20 mg/day was started.

Patient progression was favorable, with the gradual disappearance of dyspnea on exertion. A control echocardiogram revealed a non-dilated right ventricle with normal PASP. Three months after surgery, anticoagulant treatment was discontinued. At present, after 2 years of follow up, the patient remains asymptomatic with no new episodes of VTE after anticoagulation completion.

GISTs are the most common mesenchymal tumors of the gastrointestinal tract. Their initial histologic label was leiomyosarcoma, but after the identification of unique activating mutations in the *KIT* gene, they were classified as a distinct entity.<sup>1</sup> Treatment of GIST may involve surgery and/or the use of tyrosine kinase inhibitors. For tumors 2 cm or smaller, with a mitotic index of 5 or less, the indication

<sup>☆</sup> Please cite this article as: Demelo-Rodríguez P, Lavilla Olleros C, Martín Higuera E, Peligros I, del Toro-Cervera J. Tumor del estroma gastrointestinal como causa de trombosis asociada a cáncer. *Revista de Gastroenterología de México*. 2019;84:250–252.