



REVISTA DE GASTROENTEROLOGÍA DE MÉXICO

www.elsevier.es/rgmx



CLINICAL IMAGE IN GASTROENTEROLOGY

Fulminant amoebic colitis with cecal pneumatosis[☆]

Colitis amibiana fulminante con neumatosis cecal

U. Rodríguez-Wong^{a,*}, U. Rodríguez-Medina^b



^a Hospital Ángeles Lindavista, Mexico City, Mexico

^b Facultad Mexicana de Medicina, Universidad La Salle, Mexico City, Mexico

A 67-year-old man had a history of type 2 diabetes mellitus. He sought medical attention for the 7-day progression of 6 to 7 diarrheic stools with mucus and blood per day, fever, nausea, and vomiting of stomach content. He presented with stabbing abdominal pain the last 3 days that began in the lower right quadrant and then became generalized. Physical examination revealed tachycardia, tachypnea, and hyperthermia of 38.7° C. He had acute abdomen with muscle resistance, a positive Blumberg's sign, and reduced peristalsis. Laboratory test results showed leukocytosis, neutrophilia, and bandemia. Plain abdominal x-rays in the standing and decubitus positions identified bowel segment distension and pneumatosis of the wall of the cecum (figs. 1 and 2). Laparotomy revealed areas of necrosis in the entire colon, with fibrinopurulent secretion and crepitation in the cecum. Subtotal colectomy was performed (fig. 3). Indirect hemagglutination and PCR testing supported the diagnosis of invasive amoebiasis. The histopathology study reported hematophagous trophozoites of *Entamoeba histolytica* in the wall of the colon^{1,2} and lymphoplasmacytic infiltrate (fig. 4).

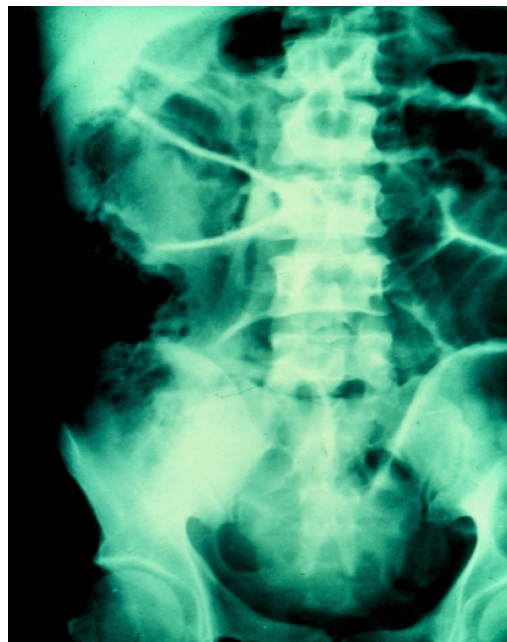

Figure 1 Radiologic image showing bowel segment distension and pneumatosis in the cecum.

[☆] Please cite this article as: Rodríguez-Wong U, Rodríguez-Medina U. Colitis amibiana fulminante con neumatosis cecal. Revista de Gastroenterología de México. 2018;83:453–454.

* Corresponding author. Hospital Ángeles Lindavista, Rio Bamba 639-330 07760 Mexico City. Tel.: +57-54-85-04 y 57-54-84-08.

E-mail address: ulisesromed@prodigy.net.mx (U. Rodríguez-Wong).

Ethical disclosures

Protection of human and animal subjects. The authors declare that no experiments were performed on humans or animals for this study.

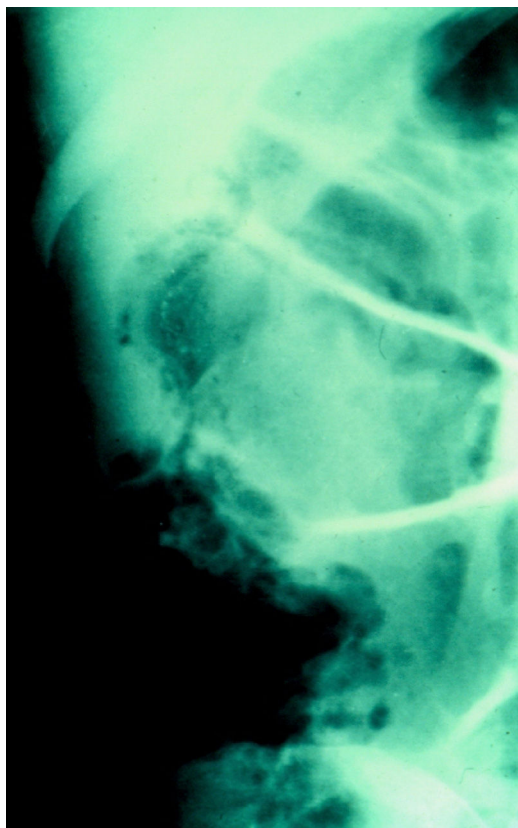


Figure 2 Radiologic image showing pneumatosis in the cecum in greater detail.

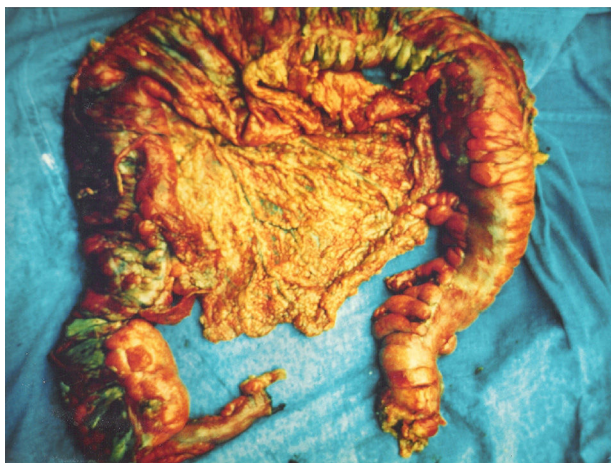

Figure 3 Surgical specimen from the subtotal colectomy.

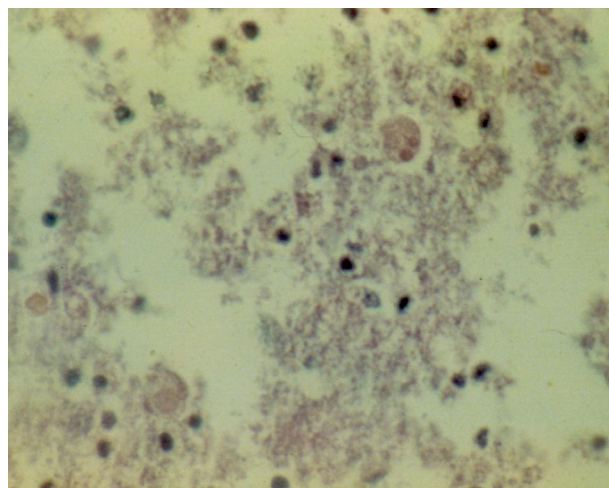


Figure 4 *Entamoeba histolytica* trophozoites in the wall of the colon, identified in the histopathology study of the patient.

Confidentiality of data. The authors declare that no patient data appear in this article.

Right to privacy and informed consent. The authors declare that no patient data appear in this article.

Financial disclosure

No financial support was received in relation to this study/article.

Conflict of interest

The authors declare that there is no conflict of interest.

References

1. Yamada H, Matsuda K, Akahane T, et al. A case of fulminant amebic colitis with multiple large intestinal perforations. *Int Surg.* 2010;95:356–9.
2. Redaelli M, Mahmoohdzad J, Lang R, et al. Globalised world, globalised diseases: A case report on an amoebiasis-associated colon perforation. *World J Clin Cases.* 2013;1:79–81.