

SCIENTIFIC LETTER

Drug-induced liver injury secondary to anabolic steroid use[☆]



Lesión hepática inducida por fármacos secundaria al uso de esteroides anabólicos

Drug-induced liver injury (DILI) is a rare condition, but nevertheless, it causes 40-50% of the cases of acute liver failure.^{1,2} There are 3 patterns of injury: hepatocellular, cholestatic, and mixed, and the cholestatic pattern accounts for 20-40% of the cases.^{3,4} Its manifestations range from biochemical alterations in the absence of symptoms to acute liver failure and chronic liver damage. It is a diagnosis of exclusion, based on circumstantial evidence. In the majority of cases, the patient's symptoms improve with the removal of the medication responsible for the injury.⁵

We present herein the case of a 38-year-old man with a history of alcoholism of 15-year progression, drinking 21.6 g of alcohol daily. The date of his last alcohol consumption (1 liter of fermented alcohol), without reaching a drunken state, was one week before the onset of clinical symptoms. He had been applying one vial a week of intramuscular anabolic steroids, containing 250 mg of testosterone, 100 mg of nandrolone, and 50 mg of stanozolol, for 31 days.

After one day of not injecting those drugs, the patient presented with clinical symptoms characterized by jaundice, generalized pruritus, and nausea. Upon his admission to the emergency unit, the patient's vital signs were within

normal parameters. Physical examination revealed jaundice, no asterixis, and abdominal pain at the level of the right hypochondrium, described as 5/10 on the Visual Analogue Scale. Laboratory work-up results showed: total bilirubin 33.87 mg/dl (0.1-1.0), direct bilirubin 26.41 mg/dl (0.1-0.25), ALT 49 IU/l (10-40), AST 65 IU/l (15-41), GGT 60 IU/l (9-40) and alkaline phosphatase 207 IU/l (38-126). A hepatobiliary ultrasound study was carried out that demonstrated no evidence of bile duct dilation and identified vascular permeability and normal liver morphology. Magnetic cholangioresonance revealed no alterations. Special laboratory tests were ordered as part of the approach to cholestasis, and the results were negative for hepatotropic virus serology (HAV, HBV, HCV, and HEV) and for cytomegalovirus and Epstein-Barr virus. The serologic profile of autoimmune hepatopathies reported negative ANAs (IIF), antimitochondrial antibodies, anti-smooth muscle antibodies, and anti-LKM1 antibodies.

DILI secondary to the application of anabolic steroids was suspected, and so an R value of 0.27 was calculated, indicating a pattern of cholestatic injury. A percutaneous biopsy of liver tissue was taken and accentuated intracytoplasmic and canalicular cholestasis predominating in perivenular zones 2 and 3 (Figs. 1 and 2) was reported. A score of 9 was calculated using the Council for International Organizations of Medical Scientists/Roussel Uclaf Assessment Method (CIOMS/RUCAM) scale, indicating definitive DILI.

The patient was initially managed with 60 mg of methylprednisolone every 24 h and then with a reduced dose of prednisone, 500 mg of S-adenosylmethionine (SAME) every

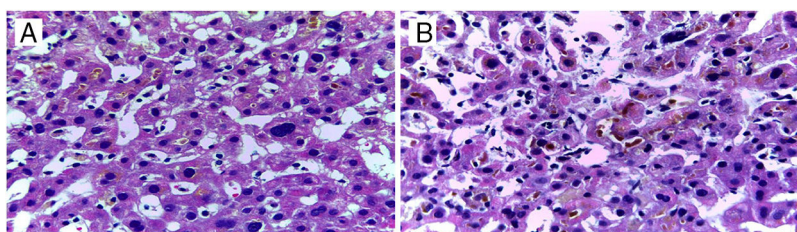


Figure 1 Liver biopsy. A) Sinusoidal dilation with intracytoplasmic bile pigment. B) Lakes of bile pigment in the dilated canaliculi.

[☆] Please cite this article as: Díaz-García JD, Córdova-Gallardo J, Torres-Viloria A, Estrada-Hernández R, Torre-Delgadillo A. Lesión hepática inducida por fármacos secundaria al uso de esteroides anabólicos. *Revista de Gastroenterología de México*. 2020;85:92–94.

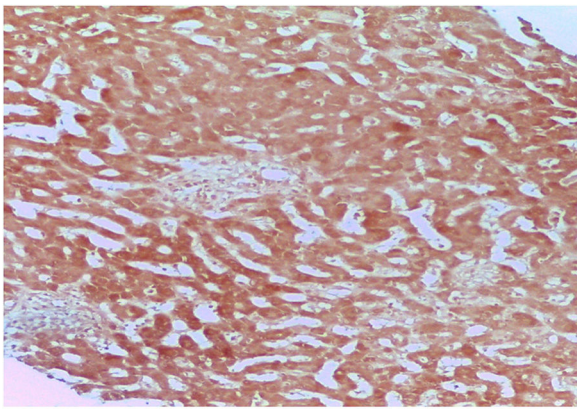


Figure 2 Liver biopsy: negative Orcein stain.

12 h and 15 mg/kg/day of ursodeoxycholic acid in 3 takes during 5 days of hospital stay, with adequate clinical progression. After his release from the hospital, the patient's progression was favorable, and his liver function tests became normal 4 months after anabolic steroid suspension.

Even though there is little epidemiologic information on the toxic effect of drugs on the liver, it is known that its incidence is increasing in parallel with the introduction of new medications, the increase in life expectancy, and polypharmacy. Accurate diagnosis is complicated and notification of adverse reactions to drugs by healthcare professionals is limited.¹⁻³ The problem of under-notification with respect to anabolic steroids is even greater because they are substances that are often obtained and consumed with no medical prescription.

Currently there are very few accepted indications for either oral or parenteral anabolic steroid use. Hepatotoxicity induced by anabolic steroids is dose-dependent and predictable. Its most frequent presentation is cholestatic hepatitis, and other types of injury associated with high doses of the drugs are: bland or "pure" cholestasis, acute cholestatic hepatitis, acute hepatocellular injury, and hepatic tumors.⁴

In the case presented herein, the patient had severe jaundice with a minimal elevation of liver enzymes, consistent with bland cholestasis. There was a clear temporal relation between the beginning/end of treatment and the appearance/disappearance of symptoms, respectively. In addition, other causes of liver injury were ruled out. With all the above and a score of 9 on the CIOMS/RUCAM hepatotoxicity evaluation scale,⁵⁻⁷ it was concluded that the patient had highly probable or definitive hepatotoxicity due to anabolic steroid use. The US National Institutes of Health also has a website (www.livertox.nih.gov) that describes cases of hepatotoxicity and the mechanism of the liver injury the drugs can cause.

Our patient's liver biopsy showed a canalicular pattern consistent with his clinical and biochemical characteristics and he had adequate progression after the suspension of the anabolic steroids.

As occurred in our patient, SAME use has shown a favorable response when combined with ursodeoxycholic acid. Different meta-analyses have determined the efficacy of

SAME in reducing pruritus and the serum bilirubin values associated with cholestasis, compared with placebo.⁸

The long-term prognosis for DILI generally depends on the initial clinical and biochemical presentation in the patient.⁹ The present case is of interest due to the approach carried out to reach the diagnosis of DILI, its adequate treatment, and the good progression of the patient, despite his initially high total bilirubin levels.

Ethical disclosures

The authors declare that the present article contains no personal information that could identify the patient and meets the current norms of and is approved by the institutional research and ethics committee.

Financial disclosure

No financial support was received in relation to this article.

Conflict of interest

The authors declare that there is no conflict of interest.

Acknowledgements

The authors wish to thank the personnel at the Departments of Internal Medicine and Pathologic Anatomy of the *Hospital General "Dr. Manuel Gea González"*, Mexico City, Mexico.

References

1. Chalasani NP, Hayashi PH, Bonkovsky HL, et al. ACG Clinical guideline: the diagnosis and management of idiosyncratic drug-induced liver injury. *Am J Gastroenterol*. 2014;109:950-66.
2. Bhamidimarri KR, Schiff E. Drug-induced cholestasis. *Clin Liver Dis*. 2013;17:519-31.
3. Danan G, Benichou C. Causality assessment of adverse reactions to drugs —I. A novel method based on the conclusions of international consensus meetings: Application to drug-induced liver injuries. *J Clin Epidemiol*. 1993;46:1323-30.
4. Kaplowitz N. Idiosyncratic drug hepatotoxicity. *Nat Rev Drug Discov*. 2005;4:489-99.
5. Maddur H, Chalasani N. Idiosyncratic drug-induced liver injury: A clinical update. *Curr Gastroenterol Rep*. 2011;13:65-71.
6. Bjornsson ES, Jonasson JG. Drug-induced cholestasis. *Clin Liver Dis*. 2013;17:191-209.
7. Kleiner DE, Chalasani NP, Lee WM, et al. Hepatic histological findings in suspected drug-induced liver injury: Systematic evaluation and clinical associations. *Hepatology*. 2014;59:661-70.
8. Sánchez-Osorio M, Duarte-Rojo A, Martínez-Benítez B, et al. Anabolic-androgenic steroids and liver injury. *Liver Int*. 2008;28:278-82.
9. Rambaldi A, Gluud C. S-adenosyl-L-methionine for alcoholic liver diseases. *Cochrane Database Syst Rev*. 2001;4:22-35.

J.D. Díaz-García^{a,*}, J. Córdova-Gallardo^b,
A. Torres-Viloria^a, R. Estrada-Hernández^c,
A. Torre-Delgadillo^d

^a Servicio de Medicina Interna, Hospital General «Dr. Manuel Gea González», Mexico City, Mexico

^b Servicio de Hepatología, Hospital General «Dr. Manuel Gea González», Mexico City, Mexico

^c Servicio de Anatomía Patológica, Hospital General «Dr. Manuel Gea González», Mexico City, Mexico

^d Servicio de Hepatología, Hospital Ángeles Pedregal, Mexico City, Mexico

* Corresponding author. Calzada de Tlalpan 4800, Belisario Domínguez Sección 16, 14080 Tlalpan, CDMX, Mexico. Phone: +525534133330

E-mail address: judan.digar@hotmail.com

(J.D. Díaz-García).

2255-534X/ © 2019 Asociación Mexicana de Gastroenterología.

Published by Masson Doyma México S.A. This is an open access article under the CC BY-NC-ND license (<http://creativecommons.org/licenses/by-nc-nd/4.0/>).

Infected walled-off pancreatic necrosis managed with percutaneous-endoscopic transabdominal drainage: A case report[☆]



Drenaje percutáneo endoscópico transabdominal en la necrosis pancreática encapsulada infectada: reporte de caso

The management of walled-off pancreatic necrosis is currently a challenge. Innovative, minimally invasive techniques have been developed in recent years and have shown excellent results, compared with conventional surgical techniques. Some such minimally invasive techniques are image-guided percutaneous pigtail catheter drainage and endoscopic transgastric drainage, with or without the use of endoscopic ultrasound.¹⁻³ However, when there is therapeutic failure or contraindication with the use of those options, walled-off pancreatic necrosis management tends to lean toward laparoscopy and/or laparotomy, which are more invasive and produce important morbidity and mortality. A retroperitoneal and transabdominal percutaneous-endoscopic approach has begun to be performed, with a satisfactory success rate, as a new therapeutic option, before resorting to the more aggressive procedures.⁴⁻⁷ A case is presented herein to describe a therapeutic approach with percutaneous-endoscopic transabdominal drainage, utilizing an esophageal fully covered self-expanding metal stent for accessing and debriding the infected pancreatic necrosis.

A 53-year-old woman presented with colicky epigastric pain of 7-hour progression, accompanied by emesis, and radiating to the lumbar region. Her amylase level was 3-times higher than its usual value (754 U/l). Upon admission, the patient had a Ranson's criteria score of 2, a mild Atlanta classification, and a double-contrast tomography scan identified changes consistent with acute pancreatitis with a Balthazar E severity score. It also revealed a focus of multiseptated, superinfected, necrotizing pancreatitis, compromising more than 50% of the pancreatic parenchyma.

In addition, possible communication of the pancreatic duct with the collection, significant edema around the entire pancreas, and peripancreatic fluid were found, for which initial clinical and endoscopic management were carried out. Endoscopic retrograde cholangiopancreatography was indicated due to the high risk for gallstones in the bile duct that presented at evaluation (total bilirubin 4.8 mg/dl, direct bilirubin 4.2 mg/dl, AST 74 mg/dl, ALT 56 mg/dl) and the possible communication of the pancreatic duct with the infected necrosis previously observed in the tomography scan.

Endoscopic retrograde cholangiopancreatography was carried out. After biliary and pancreatic sphincterotomy, both the bile and pancreatic ducts were cannulated. Due to the high suspicion of a main pancreatic duct fistula at the level of the body of the pancreas, a 5 Fr plastic pancreatic stent was inserted, after which extrusion of purulent material into the duodenum was observed. Bile duct stone extraction was also performed utilizing a Dormia basket.

Upon evaluation, the patient had been hospitalized for a longer period of time, with the recent in-hospital diagnosis of diabetes mellitus that required insulin therapy. Her clinical picture deteriorated, and she presented with an active systemic inflammatory response, treated with broad-spectrum antibiotic therapy indicated by the Infectious Diseases Service. The decision was made by the Interventional Radiology Service to perform percutaneous drainage of the lesions described above, providing only partial

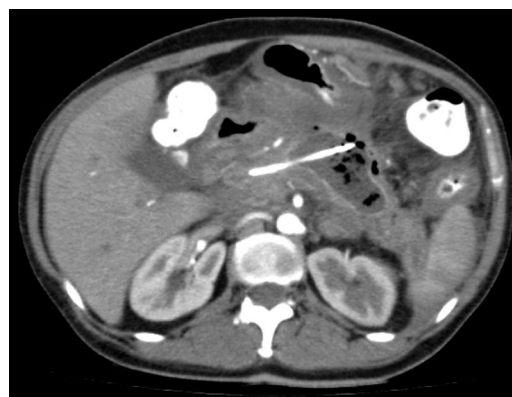

Figure 1 Abdominal tomography scan before the intervention. The walled-off necrotizing pancreatic collection is seen, with percutaneous pigtail catheter drainage. The presence of the pancreatic collection indicates the site of rupture of the main pancreatic duct.

[☆] Please cite this article as: Mendoza J, Tovar G, Galvis M, Mendoza M, Lozano C. Drenaje percutáneo endoscópico transabdominal en la necrosis pancreática encapsulada infectada: reporte de caso. *Revista de Gastroenterología de México*. 2020;85:94-97.