

*coralis* is negative after 2 weeks of treatment, thus ensuring eradication and eliminating the autoinfection cycle.<sup>10</sup>

Therefore, clinical, endoscopic, and histologic suspicion of colitis due to *Strongyloides* infection is important in a patient with inflammatory diarrhea and endoscopic findings suggestive of ulcerative colitis, given that an erroneous diagnosis and late treatment can be fatal.

## Ethical considerations

The present scientific letter follows the guidelines of the 1975 Declaration of Helsinki. No authorization by an ethics committee or patient informed consent for receiving a treatment was required, given that we only described a case, respecting the patient's privacy.

The authors declare that no personal information of the patient appears in the letter and patient anonymity was respected, making consent for publication unnecessary.

**Protection of human and animal subjects.** The authors declare that no experiments were performed on humans or animals for this study.

**Confidentiality of data.** The authors declare that the patient data that appear in this article are completely anonymous.

**Right to privacy and informed consent.** The authors declare that they have respected the privacy of the patient data and have the consent for publication signed by the authors.

## Financial disclosure

No specific grants were received from public sector agencies, the business sector, or non-profit organizations in relation to this study.

## Conflict of interest

The authors declare that there is no conflict of interest.

## References

1. Marcos LA, Terashima A, Canales M, et al. Update on strongyloidiasis in the immunocompromised host. *Curr Infect Dis Rep.* 2011;13:35–46.

2. Vildosola Gonzales H. *Strongyloidiasis*. *Rev Gastroenterol Perú.* 1997;17 Supl1:575–91.
3. Poveda J, Sharkawy F, Arosemena LR, et al. *Strongyloides Colitis* as a harmful mimicker of inflammatory bowel disease. *Case Rep Pathol.* 2017;2017:2560719, <http://dx.doi.org/10.1155/2017/2560719>.
4. Minematsu H, Hokama A, Makishi T, et al. Colonoscopic findings and pathologic characteristics of *Strongyloides colitis*: a case series. *Digestion.* 2011;83:210–4.
5. Keiser PB, Nutman TB. *Strongyloides stercoralis* in the immunocompromised population. *Clin Microbiol Rev.* 2004;17:208–17.
6. Grossi PA, Lombardi D, Petrolo A, et al. *Strongyloides stercoralis* hyperinfection in an hiv-infected patient successfully treated with subcutaneous ivermectin. *Trop Med Infect Dis.* 2018;3:46.
7. Siegel M, Simon G. Is human immunodeficiency virus infection a risk factor for *Strongyloides stercoralis* Hyperinfection and dissemination. *PLoS Negl Trop Dis.* 2012;6:e1581.
8. Kishimoto K, Hokama A, Hirata T, et al. Endoscopic and histopathological study on the duodenum of *Strongyloides stercoralis* hyperinfection. *World J Gastroenterol.* 2008;14:1768–73.
9. Qu Z, Kundu UR, Abadeer RA, et al. *Strongyloides colitis* is a lethal mimic of ulcerative colitis: the key morphologic differential diagnosis. *Hum Pathol.* 2009;40:572–7.
10. Luvira V, Watthanakulpanich D, Pittsuttithum P. Management of *Strongyloides stercoralis*: A puzzling parasite. *Int Health.* 2014;6:273–81.

P. Gomez-Hinojosa<sup>a,\*</sup>, C. García-Encinas<sup>a</sup>,  
A. Carlin-Ronquillo<sup>a</sup>, R.P. Chancafe-Morgan<sup>b</sup>,  
J. Espinoza-Ríos<sup>a,c</sup>

<sup>a</sup> Servicio de Gastroenterología, Departamento de Medicina, Hospital Cayetano Heredia, Lima, Peru

<sup>b</sup> Servicio de Anatomía Patológica, Hospital Cayetano Heredia, Lima, Peru

<sup>c</sup> Universidad Peruana Cayetano Heredia, Lima, Peru

\* Corresponding author at: Jr. Alhelí # 874 - San Martín de Porres, Tel.: +984342744.

E-mail address: [pagoi@hotmail.com](mailto:pagoi@hotmail.com) (P. Gomez-Hinojosa).

2255-534X/ © 2019 Asociación Mexicana de Gastroenterología. Published by Masson Doyma México S.A. This is an open access article under the CC BY-NC-ND license (<http://creativecommons.org/licenses/by-nc-nd/4.0/>).

## Perianal lipoma with an intersphincteric fistula in an adult patient<sup>☆</sup>



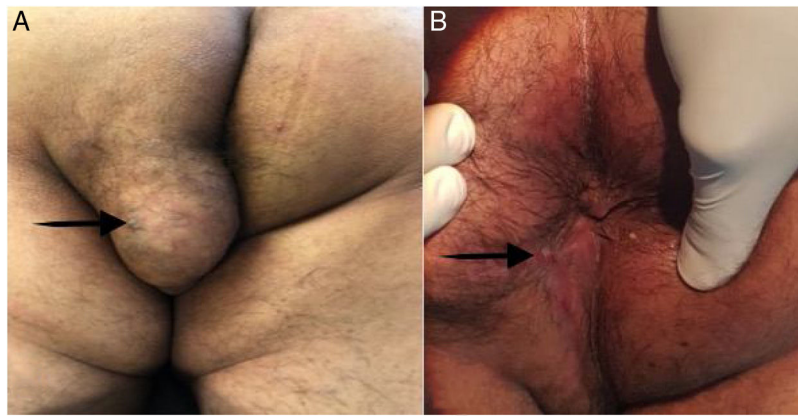
### Lipoma perianal con fístula interesfintérica en un paciente adulto

An anal fistula, or fistula-in-ano, is an abnormal granulating tract between the anorectum and the perianal region. Incidence varies between 0.86 and 2.32 per 10,000/year

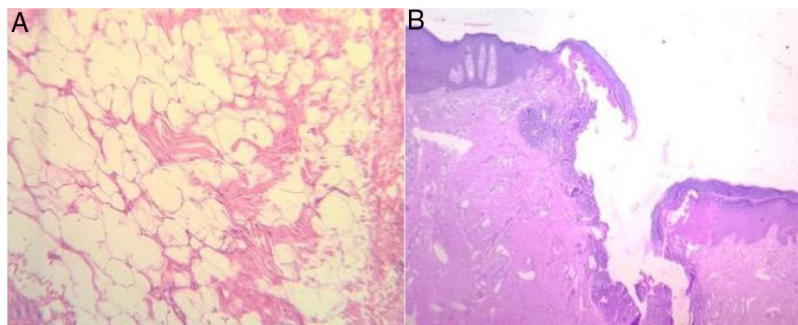
and is predominant in males, with ratios ranging from 2:1 to 5:1.<sup>1</sup> Lipomas are benign soft tissue tumors composed of adipocytes within a thin fibrous capsule and account for almost 50% of all soft tissue tumors.<sup>2</sup> Able to occur in any part of the body that has normal fat deposits, they develop where those deposits are greatest, such as the trunk, forearms, and thighs. Lipomas are rarely found in areas that naturally have little fat, such as the perineum.<sup>3</sup> Soft tissue lipomas are commonly seen in daily practice and present in around 2% of the population.<sup>2</sup>

A 35-year-old man had an unremarkable past medical history, except for surgical drainage of a perianal abscess, 7 years prior. He arrived at our surgical clinic, presenting with a purulent discharge and drainage of pus near the anus that irritated the perianal space and the anal canal, causing itching and discomfort. He stated that his symptoms had not

<sup>☆</sup> Please cite this article as: González-Urquijo M, Zambrano-Lara M, Espinosa-Loera JJ, Gil-Galindo G. Lipoma perianal con fístula interesfintérica en un paciente adulto. *Revista de Gastroenterología de México.* 2020. <https://doi.org/10.1016/j.rgm.2019.08.007>



**Figure 1** (A) A well-defined, 6 × 6 cm tumor in the left buttock and perineum. The black arrow points to the external orifice of the perianal fistula. (B) The perianal wound was healed by secondary intention, at the follow-up at 12 months. The black arrow points to the scar of the completely healed perianal fistula's external orifice.



**Figure 2** Histologic images. (A) Mature white adipose tissue with no atypia. (B) The fistulous tract, with mostly variable scarring and inflammatory and granulation tissue.

resolved since his initial procedure 7 years earlier and he complained of a painless lump in the left buttock of 4-month progression.

Physical examination revealed a well-defined, non-tender, freely mobile, 6 × 6 cm lump on the left buttock whose overlying skin was normal in color, texture, and temperature. It was superficially situated on the subcutaneous plane, 3 cm from the anal verge (Fig. 1A). The initial diagnosis was benign soft tissue tumor. Digital rectal examination revealed a fibrous cord beneath the skin, between the lump and the anal verge, that caused discomfort and pain. There was no evidence of swelling, purulent discharge, or internal masses. The patient was transferred to the operating room, and under regional epidural anesthesia, was placed in the jack-knife position. An anoscopy was performed, identifying the internal orifice of the communicating tract at the 7 o'clock position. An intersphincteric fistula passed from the internal opening into the lump, in a straight line. The fistula was de-roofed through careful diathermy, and the lump was excised, using an elliptical incision. The wound was left open and the tract and wound were packed. Upon gross examination, the tumor was soft and well-circumscribed by a thin fibrous capsule. The patient was discharged on post-operative day 4, with no complications. The histopathologic examination confirmed the diagnosis of lipoma, with a fistulous tract reaching the anal canal, and no evidence of malignancy (Fig. 2A and B). Six months after the initial procedure, the tract was obliterated, with no loss of sphincter

function, and the wound was completely healed by secondary intention, with no significant deformities (Fig. 1B). At the follow-up at 12 months, the patient was healthy, with no complications.

An anal fistula is the chronic phase of an ongoing perianal infection. Most fistulas begin as anorectal abscesses. When the abscess opens spontaneously, a fistula may occur, which is then kept open by an infectious source.<sup>4</sup> In over 90% of cases, anal fistulas are caused by infected anal glands, which provide free channels through which the infection can pass from the anal lumen into the deep sphincter muscles, becoming the chronic phase of an ongoing perianal infection. The infection penetrates the wall of the anal canal through a fissure or other wound, and once established, the infected tract is kept open by fecal content.<sup>5</sup>

Our patient had presented with a perianal abscess 7 years earlier, which we believe was the origin of the fistulous tract. Only the abscess had been treated at the time, and the fistulous tract was left intact. Most likely, over time, a soft tissue tumor developed at the site of the cavity of the previous abscess, with the internal orifice of the fistulous tract at the anal canal and the development of its external orifice at the site of the tumor.

The perianal region is a rare site for lipomas or soft tissue tumors. It is difficult for those patients to be in a seated position and there can be interference with defecation if there is intersphincteric extension or mechanical

obstruction from swelling.<sup>3,6</sup> Endosonography, computerized tomography, and magnetic resonance imaging (MRI) can be used in the diagnosis of perianal tumors, with MRI being the best modality for ruling out intersphincteric tumor extension.<sup>3,7</sup> None of those imaging studies were available at our hospital, so we took the patient directly into the operating room to perform an anal examination under anesthesia, to determine the anatomic relation of the sphincters to the mass, and perform the necessary intervention. Perianal soft tissue tumors should be carefully dissected away from the perianal fat, always attempting to preserve the anal sphincters, if they are involved. In our patient, the anal sphincters were indirectly involved through communication with the tumor and so fistulotomy was performed, with no complications.

We found no cases in the literature of perianal lipoma with a fistulous tract reaching the anal canal and a surgical approach as the treatment of choice.

### Ethical disclosures

The authors declare that no experiments were performed on humans or animals for this report. It was approved by the ethics committee of the *Tecnológico de Monterrey* and complies with the norms of the bioethical research regulations.

A written statement of informed consent was obtained from the patient for the publication of this scientific letter and its accompanying images. A copy of the written consent statement is available for review by the Editor-in-Chief of this journal upon request.

### Funding

No specific grants were received from public sector agencies, the business sector, or non-profit organizations in relation to this article.

### Conflict of interest

The authors declare that there is no conflict of interest.

### References

1. Onkelen RSV. *Anal fistulas: new perspectives on treatment and pathogenesis*. Rotterdam: Erasmus University; 2015.
2. Rahman GA, Abdulkadir AY, Yusuf IF. Lipomatous lesions around the shoulder: recent experience in a Nigerian hospital. *Int J Shoulder Surg* [Internet]. 2009;3:13–5. Available from: <http://www.ncbi.nlm.nih.gov/pmc/articles/PMC2895296/>
3. Kale PA. Lipoma of the perineum: a case report. *Ann Int Med Dent Res*. 2015;1:348–9.
4. Kumar BA, Rao PR, Kalyan KASSN. Study of fistula-in-ano and its aetiological aspects. *Int J Curr Med Appl Sci*. 2017;14:15–9.
5. Srivastava KN, Agarwal A. A complex fistula-in-ano presenting as a soft tissue tumor. *Int J Surg Case Rep*. 2014;5:298–301, <http://dx.doi.org/10.1016/j.ijscr.2014.03.018>.
6. Deolekar S, Shaikh TP, Ansari S, et al. Pedunculated perianal lipoma: a rare presentation. *Int J Res Med Sci*. 2015;3:1557–8, <http://dx.doi.org/10.18203/2320-6012.ijrms20150191>.
7. Akyüz C, Fatih N, Derya Peker K, et al. A rare case: a large perianal epidermal cyst. *Med J Bakirköy*. 2014;10:182–4.

M. González-Urquijo<sup>a,b,\*</sup>, M. Zambrano-Lara<sup>a,b</sup>, J.J. Espinosa-Loera<sup>b</sup>, G. Gil-Galindo<sup>a,b</sup>

<sup>a</sup> *Tecnológico de Monterrey, Escuela de Medicina y Ciencias de la Salud, Monterrey, Nuevo León, Mexico*

<sup>b</sup> *División de Cirugía, Hospital Metropolitano «Dr. Bernardo Sepúlveda», San Nicolás de los Garza, Nuevo León, Mexico*

\* Corresponding author at: Dr. Ignacio Morones Prieto O 3000, Monterrey 64710, Mexico. Tel.: +52 8119103675. E-mail address: [mauriciogzzu@gmail.com](mailto:mauriciogzzu@gmail.com) (M. González-Urquijo).

2255-534X/ © 2019 Asociación Mexicana de Gastroenterología. Published by Masson Doyma México S.A. This is an open access article under the CC BY-NC-ND license (<http://creativecommons.org/licenses/by-nc-nd/4.0/>).

## Symptomatic patency capsule retention in a patient with confirmed Crohn's disease<sup>☆</sup>



### Retención sintomática de la cápsula Patency en un paciente con enfermedad de Crohn confirmada

In capsule endoscopy (CE) performed on patients with confirmed Crohn's disease, the video capsule is retained in up to 13% of cases,<sup>1</sup> motivating the development of a patency

capsule (PC) (Given Imaging, Yokneam, Israel). The PC is a biodegradable capsule, with a diameter similar to that of the PillCam SB3 video capsule, that begins to degrade 30h after its ingestion, enabling it to pass through a stricture that has caused its retention.<sup>2</sup> Symptomatic PC retention is a rare complication, with few descriptions in the literature. It is characterized by transitory obstructive symptoms in the majority of cases.<sup>3</sup> A multicenter study including 1615 patients that underwent a PC test reported symptomatic retention in 20 patients (1.2%), only one of which required surgery. The rest of the cases resolved spontaneously or after corticosteroid therapy.<sup>4</sup> The case of a patient with intestinal obstruction secondary to PC ingestion is presented herein.

A 68-year-old man with a diagnosis of Crohn's disease of 9-year progression had a history of 2 episodes of bowel obstruction secondary to the disease. He was currently asymptomatic and under treatment with mesalazine, azathioprine, and adalimumab. CE was ordered to evaluate

<sup>☆</sup> Please cite this article as: Blanco-Velasco G, Ramos-García J, Zamarripa-Mottú R, Solórzano-Pineda OM, Hernández-Mondragón OV. Retención sintomática de la cápsula Patency en un paciente con enfermedad de Crohn confirmada. *Revista de Gastroenterología de México*. 2020. <https://doi.org/10.1016/j.rgmx.2019.08.005>