

- tosystemic shunt. *Aliment Pharmacol Ther.* 2016;43:955–65, <http://dx.doi.org/10.1111/apt.13569>.
6. Cazzaniga M, Salerno F, Pagnozzi G, et al. Diastolic dysfunction is associated with poor survival in patients with cirrhosis with transjugular intrahepatic portosystemic shunt. *Gut.* 2007;56:869–75, <http://dx.doi.org/10.1136/gut.2006.102467>.
  7. Pudil R, Praus R, Hulek P, et al. Transjugular intrahepatic portosystemic shunt is associated with significant changes in mitral inflow parameters. *Ann Hepatol.* 2013;12:464–70.
  8. Modha K, Kapoor B, Lopez R, et al. Symptomatic Heart Failure after Transjugular intrahepatic Portosystemic Shunt Placement: Incidence, Outcomes and Predictors. *Cardiovascular Intervention Radiol.* 2018;41:564–71, <http://dx.doi.org/10.1007/s00270-017-1848-1>.
  9. Badano LP, Muraru D, Enriquez-Sarano M, et al. Assessment of functional tricuspid regurgitation. *Eur Heart J.* 2013;34:1875–85, <http://dx.doi.org/10.1093/eurheartj/ehs474>.

B. Valdivia-Correa<sup>a</sup>, V. Reynier-Garza<sup>b</sup>, N. Chávez-Tapia<sup>a</sup>, G. Alanis-Estrada<sup>b</sup>, D. Araiza-Garaygordobil<sup>b,\*</sup>

<sup>a</sup> *Departamento de Gastroenterología, Clínica y Fundación Médica Sur, Mexico City, Mexico*

<sup>b</sup> *Unidad Coronaria, Instituto Nacional de Cardiología Ignacio Chávez, Mexico City, Mexico*

\* Corresponding author at: Juan Badiano 1, Sección XVI Tlalpan, Mexico City, Mexico. Tel.: 55 2895 6977. E-mail address: [dargaray@gmail.com](mailto:dargaray@gmail.com) (D. Araiza-Garaygordobil).

2255-534X/ © 2020 Asociación Mexicana de Gastroenterología. Published by Masson Doyma México S.A. This is an open access article under the CC BY-NC-ND license (<http://creativecommons.org/licenses/by-nc-nd/4.0/>).

## Hepatocellular carcinoma associated with direct-acting antiviral therapy for hepatitis C virus: A report of two cases<sup>☆</sup>



### Carcinoma hepatocelular asociado con el uso de la terapia antiviral de acción directa para virus de hepatitis C: reporte de dos casos

Hepatocellular carcinoma (HCC) is the fifth most common neoplasm worldwide and hepatitis C virus (HCV) is the leading cause, conditioning a 3 to 7% risk per year in patients with liver cirrhosis (LC).<sup>1</sup> In the era of pegylated interferon (PEG-IFN), the sustained virologic response (SVR) was about 50%, and in cirrhotic patients that achieved SVR, the incidence of HCC decreased to 0.5-1% annually.<sup>2</sup>

The introduction of direct-acting antiviral (DAA) therapy resulted in a reported SVR above 90%, with a positive impact on the course of HCC, reducing the adverse effects in patients with a more advanced disease stage.<sup>3</sup> Despite the promising results of DAA therapy, some reports suggest it may increase the risk for HCC occurrence and recurrence,<sup>4</sup> hence our decision to present the following 2 cases (Table 1).

#### Case 1

A 66-year-old man was diagnosed with LC secondary to HCV in 2014. A magnetic resonance imaging (MRI) study performed that same year revealed a 7.3 cm lesion in segment VII, displaying typical HCC behavior, for which he underwent transarterial embolization (TAE). In 2015, he again required TAE, after which he had complete radiologic response (CRR)

(Fig. 1a-c) and remained under surveillance. In March 2017, the patient achieved SVR with DAA therapy. A control imaging study performed after SVR showed that the lesion had progressed, with vascular invasion (Fig. 1d-f).

#### Case 2

A 74-year-old woman was diagnosed with LC secondary to HCV in 2016. An ultrasound study performed before she started DAA therapy showed no focal lesions. After achieving SVR, she presented with acute cholecystitis. A tomography scan revealed 2 lesions, one measuring 7 mm that displayed typical HCC behavior, and the other measuring 1.7 cm that had contrast medium enhancement (Fig. 1g). A biopsy was performed on the larger lesion, and HCC was reported. The patient underwent radiofrequency ablation (RFA), and 2 months later, the lesion had increased in size from 7 mm to 2.5 cm (Fig. 1h).

Despite the fact that the development and recurrence of HCC observed in our case reports appear to be associated with DAA therapy, evidence from recent studies has shown no such association. In a cohort study on 33,137 patients, Mun et al. evaluated the risk of *de novo* HCC developing after antiviral treatment and concluded that there were no significant differences in HCC risk after DAA treatment.<sup>5</sup> Those results were consistent for *de novo* cases and recurrence in a systematic review and meta-analysis by Rutledge et al. that included 138 studies (n = 177,512).<sup>6</sup>

The impact of DAA on liver transplantation has been evaluated in cohorts at European and Latin American centers, and in both of those studies, no evidence of higher waitlist progression or post-transplantation recurrence was reported.<sup>7,8</sup> The controversy derived from previous analyses appears to be related to study methodology.

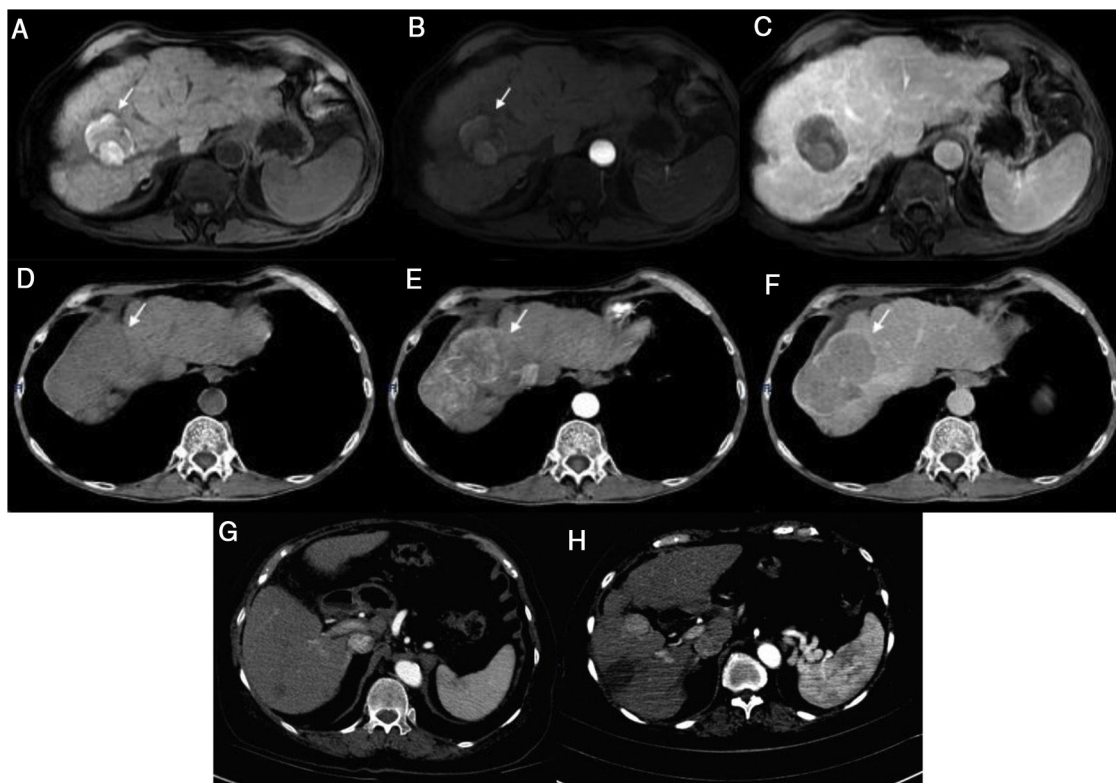
Today, the benefit of treating patients with DAAs is clear and has been associated with a decrease in all-cause mortality.<sup>9</sup> Predictive scoring systems have been developed with the aim of stratifying the risk for HCC in patients that have undergone DAA therapy.<sup>10</sup>

<sup>☆</sup> Please cite this article as: Tapia-Sosa R, Hernández-Cabral F, Gabutti A, Páez-Zayas VM, García-Juárez I. Carcinoma hepatocelular asociado con el uso de la terapia antiviral de acción directa para virus de hepatitis C: reporte de dos casos. *Revista de Gastroenterología de México.* 2021;86:197–199.

**Table 1** Summary of clinical cases.

Case	Age	Sex	HCV genotype	PCR IU/mL	DAA	Treatment duration	SVR	Tumor size	LRT
1	66	M	1b	2,900,000	Sofosbuvir Ledipasvir	24 weeks	Yes	7.3 cm segment VII	TAE RFA
2	74	F	1b	3,292,886	Sofosbuvir Ledipasvir	12 weeks	Yes	1.7 cm segment VI 0.7 cm segment V	RFA

DAA: direct-acting antiviral; F: female; HCV: hepatitis C virus; LRT: locoregional therapy; M: male; PCR: polymerase chain reaction; RFA: radiofrequency ablation; SVR: sustained virologic response; TAE: transarterial embolization.



**Figure 1** Case 1) Magnetic resonance imaging (MRI): T1 FatSat image shows hyperintensity of the tumor in segment VII secondary to necrosis with no arterial enhancement and no new lesions observed in the venous phase (a-c). The tumor seen on the previous MRI now shows activity and an increase in size (d-f). Case 2) Computed tomography (CT): 7 mm lesion with enhancement and a 17 mm lesion with typical behavior (g). Control image 2 months post-radiofrequency ablation shows the increase in size of the lesion from 7 mm to 25 mm, with a typical image of HCC (h).

## Ethical considerations

The present scientific letter meets the current bioethical research regulations. It was authorized by the ethics committee of the *Instituto Nacional de Ciencias Médicas y Nutrición "Salvador Zubirán"*. The patients cannot be recognized or identified through the images or data contained in the article.

## Financial disclosure

No financial support was received in relation to this article.

## Conflict of interest

The authors declare that there is no conflict of interest.

## References

1. Jemal A, Ward EM, Johnson CJ, et al. Annual report of the nation on the status of Cancer, 1975–2014, featuring survival. *J Natl Cancer Inst.* 2017;109, <http://dx.doi.org/10.1093/jnci/djx030>, djx030.
2. D'Ambrosio R, Della Corte C, Colombo M. Hepatocellular carcinoma in patients with a sustained response to anti-hepatitis C therapy. *Int J Mol Sci.* 2015;16:19698–712, <http://dx.doi.org/10.3390/ijms160819698>.

3. Grandhe S, Frenette CT. Occurrence and recurrence of hepatocellular carcinoma after successful direct-acting antiviral therapy for patients with chronic hepatitis C virus infection. *Gastroenterol Hepatol (N Y)*. 2017;13:421–5. <http://dx.doi.org/10.1016/j.jhep.2016.04.008>.
4. Reig M, Mariño Z, Perelló C, et al. Unexpected early tumor recurrence in patients with HCV-related HCC undergoing interferon-free therapy. *J Hepatol*. 2016;65:719–26. <http://dx.doi.org/10.1016/j.jhep.2016.04.008>.
5. Mun EJ, Green P, Berry K, et al. No difference between direct-acting antivirals for hepatitis C in hepatocellular carcinoma risk. *Eur J Gastroenterol Hepatol*. 2019;31:47–52.
6. Rutledge SM, Zheng H, Li DK. No evidence for higher rates of hepatocellular carcinoma after direct-acting antiviral treatment: a meta-analysis. *Hepatoma Res*. 2019;5:31. <http://dx.doi.org/10.20517/2394-5079.2019.19>.
7. Belli LS, Perricone G, Adam R, et al. Impact of DAAs on liver transplantation: major effects on the evolution of indications and results. An ELITA study based on the ELTR registry. *J Hep*. 2018;69:810–7. <http://dx.doi.org/10.1016/j.jhep.2018.06.010>.
8. Piñero F, Boin I, Chagas A, et al. Direct-Acting antivirals and hepatocellular carcinoma: no evidence of higher wait-list progression or posttransplant recurrence. *Liver Transpl*. 2020;26:640–50. <http://dx.doi.org/10.1002/lt.25744>.
9. Carrat F, Fonatine H, Dorival C, et al. Clinical outcomes in patients with chronic hepatitis C after direct-acting antiviral treatment: a prospective cohort study. *Lancet*. 2019;393:1453–64. [http://dx.doi.org/10.1016/S0140-6736\(18\)32111-1](http://dx.doi.org/10.1016/S0140-6736(18)32111-1).
10. Tani J, Morishita A, Sakamoto T, et al. Simple scoring system for prediction of hepatocellular carcinoma occurrence after hepatitis C virus eradication by direct-acting antiviral treatment: all Kagawa liver disease group study. *Oncol Lett*. 2019;19:2205–12. <http://dx.doi.org/10.3892/ol.2020.11341>.

R. Tapia-Sosa<sup>a</sup>, F. Hernández-Cabral<sup>a</sup>, A. Gabutti<sup>b</sup>, V.M. Páez-Zayas<sup>c</sup>, I. García-Juárez<sup>a,\*</sup>

<sup>a</sup> *Departamento de Gastroenterología, Instituto Nacional de Ciencias Médicas y Nutrición Salvador Zubirán, Mexico City, Mexico*

<sup>b</sup> *Departamento de Imagenología, Instituto Nacional de Ciencias Médicas y Nutrición Salvador Zubirán, Mexico City, Mexico*

<sup>c</sup> *Departamento de Donación y Trasplantes, Hospital General de México "Dr. Eduardo Liceaga", Mexico City, Mexico*

\* Corresponding author at: Vasco de Quiroga 15, Colonia Belisario Domínguez, Sección XVI, C.P. 14080, Mexico City. Tel.: 55 5487 0900.

E-mail address: [drinter77@gmail.com](mailto:drinter77@gmail.com) (I. García-Juárez).

2255-534X/ © 2020 Asociación Mexicana de Gastroenterología. Published by Masson Doyma México S.A. This is an open access article under the CC BY-NC-ND license (<http://creativecommons.org/licenses/by-nc-nd/4.0/>).

## Median arcuate ligament syndrome as a rare cause of chronic abdominal pain<sup>☆</sup>



### Síndrome de ligamento arcuato medio como causa poco frecuente de dolor abdominal crónico

A 66-year-old man had a surgical history of laparoscopic fundoplication in 1995 and laparoscopic cholecystectomy in 1996. He arrived at the emergency department due to predominantly moderate, sharp, pulsating pain in the epigastrium that was associated with food intake, and to nausea, vomiting, change in bowel movement pattern, and general malaise. The patient stated he had presented with the same pain over a 20-year period, for which he was studied on numerous occasions by different gastroenterologists, undergoing endoscopy procedures and tomography exams (the latest two years prior) but not resulting in an accurate diagnosis. Physical examination showed normal vital

signs and a murmur in the epigastric region, with no signs of peritoneal irritation. A contrast-enhanced computed tomography angiogram identified a reduction in the caliber of the origin of the short segment of the celiac trunk, with upward angulation of almost the entire celiac trunk, caused by the median arcuate ligament (Fig. 1A and B). A Doppler ultrasound was then carried out that showed a systolic velocity of 582 cm/s during expiration (normal value: below 350 cm/s), as well as a difference in the flow velocity during inspiration. Endovascular cannulation of the celiac trunk through the humeral artery was initially performed by the vascular surgery service, identifying important angulation of the celiac trunk (Fig. 2A). Afterwards, a laparoscopic procedure was performed at the general surgery service, finding fibrosis and adhesions at the level of the pillars of the diaphragm. Dissection was carried out until the celiac trunk was identified, which was found to be extrinsically compressed by the median arcuate ligament (Fig. 2B). The celiac trunk was freed, revealing its trifurcation, and its correct release from compression and flow improvement were corroborated by angiography. The patient was discharged on the second postoperative day, tolerating oral diet, experiencing no pain, and with 50% symptom improvement. At postoperative follow-up at one month, 2 months, and 9 months, the patient had 100% symptom improvement, stating that he was asymptomatic.

<sup>☆</sup> Please cite this article as: Zambrano-Lara M, Gonzalez-Urquijo M, Lozano-Balderas G, Rodarte-Shade M, Fabiani MA. Síndrome de ligamento arcuato medio como causa poco frecuente de dolor abdominal crónico. *Revista de Gastroenterología de México*. 2021;86:199–201.