

## Conflict of interest

The authors declare that there is no conflict of interest.

## References

1. López-Zamudio J, Leonher-Ruezga KL, Ramírez-González LR, et al. Lipoma gástrico pediculado. Reporte de caso. *Cir Cir*. 2015;83:222–6, <http://dx.doi.org/10.1016/j.circir.2015.05.005>.
2. Krishnaraj B, Dhanapal B, Shankar G, et al. Gastric lipoma: a rare cause of haematemesis. *Ann R Coll Surg Engl*. 2018;100, <http://dx.doi.org/10.1308/rcsann.2017.0209>, e41–3.
3. Amundson JR, Straus D, Azab B, et al. Giant symptomatic gastric lipoma: a case report and literature review. *Int J Surg Case Rep*. 2018;51:313–7, <http://dx.doi.org/10.1016/j.ijscr.2018.08.061>.
4. Tirumani SH, Baheti AD, Tirumani H, O'Neill A, Jagannathan JP. Update on gastrointestinal stromal tumors for radiologists. *Korean J Radiol*. 2017;18:84–93, <http://dx.doi.org/10.3348/kjr.2017.18.1.84>.
5. Goldblum JR, Folpe AL, Weiss SW. Benign lipomatous tumors. *Enzingerand Weiss's soft tissue tumors*; 2018. p. 443–83.
6. Alvarado-Cabrero I, Barreto-Zúñiga R, Benítez-Arroyo H, et al. Lineamientos actualizados en el abordaje de tumores del estroma

gastrointestinal (GIST) en México. 2007. *GAMO*. 2008;7:1–18.

7. Al Shammari JO, Al-Shadidi N, Abdulsalam AJ, et al. Gastric lipoma excision during a laproscopic sleeve gastrectomy: a case report. *Int J Surg Case Rep*. 2016;24:128–30, <http://dx.doi.org/10.1016/j.ijscr.2016.05.040>.

I. Garrido-Márquez<sup>a,\*</sup>, P.V. García-Pérez<sup>a</sup>,  
E. Moya-Sánchez<sup>a</sup>, A. Carrero-Castaño<sup>b</sup>

<sup>a</sup> Servicio de Radiodiagnóstico, Hospital Universitario Clínico San Cecilio, Granada, Spain

<sup>b</sup> Servicio de Anatomía Patológica, Hospital Universitario Clínico San Cecilio, Granada, Spain

\* Corresponding author at: Hospital Universitario Clínico San Cecilio, Avda/del Conocimiento, s/n, 18016 Granada, Spain. Tel.: 638722534.

E-mail address: [igamar26@gmail.com](mailto:igamar26@gmail.com) (I. Garrido-Márquez).

2255-534X/ © 2022 Asociación Mexicana de Gastroenterología. Published by Masson Doyma México S.A. This is an open access article under the CC BY-NC-ND license (<http://creativecommons.org/licenses/by-nc-nd/4.0/>).

## Intestinal pseudo-obstruction: A rare presentation of congenital hypothyroidism<sup>☆</sup>



### Pseudo-obstrucción intestinal: una presentación poco frecuente de hipotiroidismo congénito

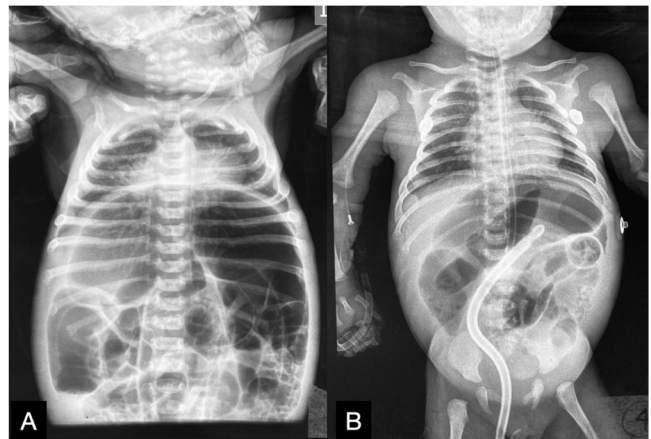
Children with thyroid gland diseases can present with gastrointestinal symptoms, mainly due to alterations in gastrointestinal motility.

A 5-month-old female infant was admitted to the emergency department, presenting with oral feeding intolerance and abdominal distension of 24-h progression. She was from a rural community in Mexico, with young, non-consanguineous parents. Metabolic screening of six elements was carried out, in which, according to the parents, a non-specified alteration was identified. However, due to the SARS-Cov-2 pandemic, the follow-up consultation was postponed. The infant passed meconium within the first 24 h but had a history of constipation during her first two weeks of extrauterine life, presenting with voluminous stools once a week. She also presented with jaundice of undetermined etiology for the first two months.

Upon hospital admission, the infant had severe overall neurodevelopmental delay. She presented with hoarse cry, coarse facies, swollen eyelids and lips, macroglossia, and inability to support her head. She had a restrictive thoracic

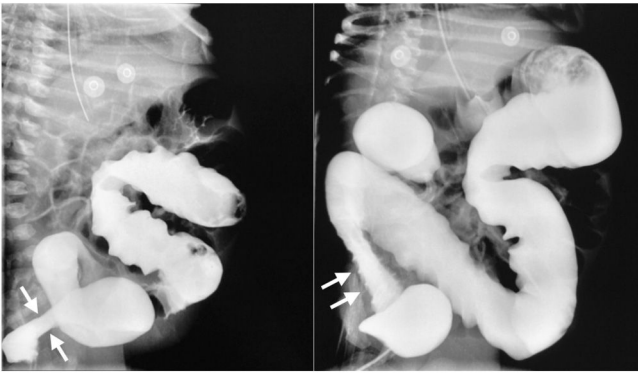
pattern due to abdominal distension, but no heart murmur upon auscultation. The abdomen was tympanic to percussion and painful when palpated. There were signs of an umbilical hernia and no hepatosplenomegaly. She presented with hypotonic and hypotrophic extremities, with diminished pulses, cutis marmorata, and generalized xerosis.

A plain abdominal x-ray was ordered, revealing important intestinal segment dilation (Fig. 1A). An orogastric tube was placed, with abundant output of bile, and a transrectal tube improved the abdominal distension (Fig. 1B). The infant had clinical signs of low cardiac output that responded to dobutamine infusion and presented with oliguria and elevated serum creatinine and blood urea nitrogen. Thyroid panel results were TSH 404 mIU/mL, total T4 0.420 ng/dL, T4 0.058 ng/dL, total T3 0.195 ng/dL, T3 0.321 pg/mL, for which treatment with levothyroxine was indicated. Feeding was started with extensively hydrolyzed formula in



**Figure 1** A) Intestinal segment dilation. B) Improvement of the restrictive thoracic pattern after orogastric and transrectal tube placement.

<sup>☆</sup> Please cite this article as: Peña-Vélez R, Reynoso-Castorena JM, Espinosa-Flores L, Balanzar-Depraect JL, Gil-Vargas M. Pseudo-obstrucción intestinal: una presentación poco frecuente de hipotiroidismo congénito. *Rev Gastroenterol Méx*. 2022;87:499–501.



**Figure 2** Contrast-enhanced barium enema study, suggestive of Hirschsprung's disease in the rectosigmoid colon.

continuous infusion one week after her admission. Given the clinical presentation consistent with Hirschsprung's disease, a contrast-enhanced barium enema was ordered that revealed an apparent transition zone in the rectosigmoid colon (Fig. 2), and so rectal irrigations were started. A rectal biopsy was taken, and high-resolution anorectal manometry was performed, documenting the rectoanal inhibitory reflex. Pericardial effusion, anemia, elevated direct bilirubin, and elevated transaminases were detected in the complementary evaluations.

The patient was released 4 weeks after admission, with improved general clinical status, adequate oral feeding tolerance, and no treatment with laxatives or prokinetics. At the outpatient follow-up, the infant presented with no upper gastrointestinal symptoms or abdominal distension. Her bowel movement pattern was normal, neurologic development showed improvement, and thyroid profile was normal.

The gastrointestinal alterations and symptoms that coexist with congenital hypothyroidism are dysphagia, vomiting, reduced gastric emptying, and small intestinal bacterial overgrowth; intestinal pseudo-obstruction is rare<sup>1</sup>. However, in the directed interview with the parents, the infant did not present with upper gastrointestinal symptoms, until her admission to the emergency department. In the review of the literature, we found only a few reports of intestinal occlusion as a presentation of hypothyroidism in adults<sup>2,3</sup>. Current recommendations in the approach to pediatric chronic intestinal pseudo-obstruction suggest performing thyroid function tests, mainly when there are signs of hypothyroidism<sup>4</sup>.

The coexistence of hypothyroidism and Hirschsprung's disease has been reported. Given that the thyroid hormones are essential for histogenesis, cell migration, and the cytoarchitecture of the central nervous system, the lack of those hormones has been suggested to favor the development of Hirschsprung's disease, due to effects on gene expressions, ligands, receptors, apoptotic factors, or extracellular matrix proteins that affect cell migration or differentiation<sup>5</sup>. Thus, we had to rule out Hirschsprung's disease in our patient, which we did, through rectal biopsy and anorectal manometry.

In conclusion, the evaluation of congenital hypothyroidism should be considered in patients that present with intestinal pseudo-obstruction. In addition, other enti-

ties whose clinical presentations are similar to that of Hirschsprung's disease must be ruled out. In turn, Hirschsprung's disease can be related to congenital hypothyroidism.

## Ethical considerations

The authors obtained informed consent from the parents of the patient referred to in this article and the document is in the possession of the corresponding author. The present work meets the current bioethical research regulations and because of the nature of this scientific letter, does not require approval by the hospital ethics committee. The authors declare that the article contains no personal information that could identify the patient.

## Financial disclosure

No financial support was received in relation to this article.

## Conflict of interest

The authors declare that there is no conflict of interest.

## References

- Ebert EC. The thyroid and the gut. *J Clin Gastroenterol*. 2010;44:402–6, <http://dx.doi.org/10.1097/MCG.0b013e3181d6bc3e>.
- Abboud B, Sayegh R, Medlej R, et al. Manifestation rare de l'hypothyroïdie: l'occlusion intestinale. Rapport de deux cas et revue de la littérature [A rare manifestation of hypothyroidism: intestinal obstruction. Report of 2 cases and review of the literature]. *J Med Liban*. 1999;47:364–6. PMID: 10758712.
- Shera IA, Vyas A, Bhat MS, et al. Unusual case of Hashimoto's encephalopathy and pseudo-obstruction in a patient with undiagnosed hypothyroidism: A case report. *J Med Case Rep*. 2014;8:296, <http://dx.doi.org/10.1186/1752-1947-8-296>.
- Thapar N, Saliakellis E, Benninga MA, et al. Paediatric intestinal pseudo-obstruction: Evidence and consensus-based recommendations from an ESPGHAN-Led Expert Group. *J Pediatr Gastroenterol Nutr*. 2018;66:991–1019, <http://dx.doi.org/10.1097/MPG.0000000000001982>.
- Eren M, Celik M, Kinik S, et al. A case of Hirschsprung disease: does thyroid hormone have any effect? *Turk J Pediatr*. 2009;51:94–6. PMID: 19378902.

R. Peña-Vélez<sup>a,\*</sup>, J.M. Reynoso-Castorena<sup>b</sup>,  
L. Espinosa-Flores<sup>b</sup>, J.L. Balanzar-Depraect<sup>c</sup>,  
M. Gil-Vargas<sup>c</sup>

<sup>a</sup> *Unidad de Gastroenterología, Hepatología y Nutrición Pediátrica, Hospital General de Puebla "Dr. Eduardo Vázquez Navarro", Puebla de Zaragoza, Puebla, Mexico*

<sup>b</sup> *Servicio de Pediatría, Hospital General de Puebla "Dr. Eduardo Vázquez Navarro", Puebla de Zaragoza, Puebla, Mexico*

<sup>c</sup> *Servicio de Cirugía Pediátrica, Hospital General de Puebla "Eduardo Vázquez Navarro", Puebla de Zaragoza, Puebla, Mexico*

\*Corresponding author at: Unidad de Gastroenterología, Hepatología y Nutrición Pediátrica, Hospital General de

Puebla “Dr. Eduardo Vázquez Navarro”, Antiguo Camino a Guadalupe Hidalgo 11350, Agua Santa, Puebla 72490, Mexico.

E-mail address: [rubenpevelez@hotmail.com](mailto:rubenpevelez@hotmail.com)  
(R. Peña-Vélez).

2255-534X/ © 2022 Asociación Mexicana de Gastroenterología. Published by Masson Doyma México S.A. This is an open access article under the CC BY-NC-ND license (<http://creativecommons.org/licenses/by-nc-nd/4.0/>).

## Laparoendoscopic modified Puestow procedure. A report on two cases<sup>☆</sup>



### Procedimiento de Puestow modificado laparoendoscópico. Reporte de dos casos

Chronic pancreatitis (CP) is characterized by chronic inflammation, fibrosis, and irreversible scarring that results in the loss of both exocrine (acinar) and endocrine (islet cells) pancreatic tissue<sup>1</sup>.

Etiology can be toxic-metabolic (alcohol, tobacco, medications, etc.), idiopathic, genetic, autoimmune, obstructive, or due to episodes of recurrent acute pancreatitis<sup>2</sup>.

CP causes healthy parenchyma to be substituted with fibrous connective tissue, resulting in increased density, atrophy, calcification, pseudocysts, and irregularities in the main pancreatic duct (MPD) and its branches. Complications of CP are stricture of the MPD and/or bile ducts, pseudocysts, pancreatolithiasis, duodenal stricture, malnutrition, vascular complications, and recurrent pain<sup>3</sup>.

Stones in the MPD cause an increase in the pressure of the parenchyma, as well as ischemia and chronic abdominal pain<sup>4</sup>.

Endoscopic management focuses on resolving MPD obstruction through dilation or stent placement, in the case of MPD stricture, or through the removal of stones<sup>5</sup>.

Surgical options include drainage, resection, resection with extended drainage, pancreatic denervation alone, or islet autotransplantation. The choice of the procedure depends on the morphologic changes of the pancreas (dilation of the MPD, stricture, lithiasis)<sup>6</sup>.

Studies conclude that surgical treatment is more efficacious and longer lasting than endoscopic treatment<sup>7–9</sup>. At present, the ideal time for surgical intervention is not known. Nealon et al. suggest that early surgical decompression of the MPD delays the progressive destruction of the pancreas<sup>8</sup>.

The modified Puestow procedure consists of a side-to-side longitudinal pancreaticojejunostomy of at least 10 cm, with no resection of the pancreatic tail or the pancreas. It is indicated in patients with MPD dilation > 7 mm, a “chain of lakes”, and no inflammatory mass in the pancreatic head. Pain relief resulting from that surgery has been shown to be around 60–70%<sup>10</sup>.

### Case 1

A 47-year-old man had a past medical history of chronic alcoholism and type 2 diabetes mellitus, both of 10-year progression. He presented with a high risk for choledocholithiasis. Endoscopic retrograde cholangiopancreatography (ERCP) was performed, revealing common bile duct stricture, and an endostent was placed. Later, the patient presented with pain, and an endoscopic ultrasound (EUS) study was carried out that identified a dilated MPD (10 mm), with multiple intraductal stones, calcifications in the pancreatic parenchyma, atrophy of the pancreatic head and tail, and dilation of the intrahepatic and extrahepatic bile ducts. Laparoendoscopic modified Puestow procedure plus cholecystectomy was performed. Oral diet was started the same day and the patient was released from the hospital 48 h after the procedure, with no complications.

### Case 2

A 22-year-old man had a past medical history of numerous hospital admissions due to severe acute pancreatitis of biliary origin, from 2017 to the present date (eight hospital admissions). EUS identified signs of CP, MPD dilation, and intraparenchymal calcifications in the head, body, and tail of the pancreas and inside the MPD (Fig. 1A1–A3). Contrast-enhanced abdominal computed tomography scan revealed CP with multiple calcifications (Fig. 1B1–B2). The laparoendoscopic modified Puestow procedure with pancreatic biopsy was performed on September 2, 2021, confirming CP, with extensive fibrosis, associated with chronic inflammation (Fig. 1C). Oral diet was started the same day, in the afternoon, and the patient was released from the hospital 48 h after the procedure, with no complications.

For the approach, a 12 mm supraumbilical camera port was placed; two 12 mm trocars were placed in the left and right midline of the clavicle; and two 5 mm trocars were placed in the anterior axillary line of both flanks (Fig. 2A). The gastrocolic ligament was cut with a Harmonic Ace® scalpel (Ethicon Endo-Surgery Inc.) (Fig. 2B), the omentum was accessed by cutting the short vessels, and the posterior gastric surface was fixed to the parietal peritoneum with a polypropylene GEA extracorporeal knot, to enable exposure (Fig. 2C). The atrophic and hardened pancreas was observed (Fig. 2D) and the main pancreatic duct was punctured, releasing pancreatic fluid (Fig. 2E). A 7 cm long pancreatotomy was made from the neck to the tail and the pancreatic duct was deroofed with a monopolar hook (Fig. 2F). Pancreatoscopy (Fig. 2G) revealed intraductal stones (Fig. 2H) that were then removed. Irrigation with physiologic solution was carried out through a 5 Fr catheter (Fig. 2I). Repeat pancreatoscopy corroborated the absence

<sup>☆</sup> Please cite this article as: Brito-Carmona RD, Cuendis-Velázquez A, Carrión-Astudillo CM, Bozada-Gutiérrez KE, García-Manzano RA. Procedimiento de Puestow modificado laparoendoscópico. Reporte de dos casos. Rev Gastroenterol Méx. 2022;87:501–503.